Department of Veterans Affairs

Journal of Rehabilitation Research and Development Vol. 38 No. 2, March/April 2001
Pages 175–181

Osseointegration in skeletal reconstruction and rehabilitation: A review

Rickard Brånemark, MD, PhD; P-I Brånemark, MD, PhD; Björn Rydevik, MD, PhD; Robert R. Myers, PhD
Department of Orthopaedics, Gothenburg University, and the Institute for Applied Biotechnology, Gothenburg, Sweden, and the VA San Diego Healthcare System

Key words: *amputation, osseointegration, prosthesis, reconstruction, titanium.*

BACKGROUND

The loosening of implants from bone tissues has been a cause of problems in reconstructive surgery and joint replacement. The thought for decades has been that the layer of fibrous tissue that develops around the implant diminishes the integrity and mechanical stability of the implant/bone interface (1). During the 1950s it had been shown by Brånemark that chambers made of the metal titanium could become permanently incorporated with bone. That is, the living bone could become so fused with the titanium oxide layer of the implant that the two could not be separated without fracture (2). Brånemark introduced the term "osseointegration" to describe this modality for stable fixation of titanium to bone tissue. From this discovery in experiments focused on observing the microcirculation of bone, through its laboratory development and initial application in the dental sciences, osseointegration has become a realized phenomenon of importance also in the orthopaedic and rehabilitation sciences.

In this brief review article we will attempt to highlight key developments in the research and application of osseointegration. Over the years, the concept of osseointegration has developed into as much of a philosophy as it is a technique for rehabilitation (3). P-I Brånemark has stated that osseointegration in theory and practice is defined as continuing structural and functional coexistence, possibly in a symbiotic manner, between differentiated, adequately remodeled, biologic tissues and strictly defined and controlled synthetic components, providing lasting, specific clinical functions without initiating rejection mechanisms (5). While this implies a rigid level of quality control for the implant, it is also absolutely necessary to have surgeons trained in appropriate implant techniques if osseointegration procedures are to be successful.

The patient has always been the focus of advances in the technique of osseointegration, and these advances have been the result of unprecedented levels of

This material is based on work supported by the VA Rehabilitation Research and Development Service, Washington D.C., and by the Institute for Applied Biotechnology, Gothenburg, Sweden.

Address all correspondence and requests for reprints to: Robert R. Myers, PhD, Senior Research Career Scientist, VA San Diego Healthcare System (151), 3350 La Jolla Village Drive, San Diego, CA 92161; email: rmyers@ucsd.edu.

collaboration between health care providers, the research community, and the medical industry. The proceedings of the recent research conference in this area, *Osseointegration, From Molecule to Man*, documents the strength of the key components of science and health that have contributed to the success and growth of osseointegration (3). It also documents the value of an interdisciplinary and multidisciplinary approach to rehabilitation patient care that encompasses many fields of research and clinical endeavor.

Definition of Osseointegration

Osseointegration was originally defined as a direct structural and functional connection between ordered living bone and the surface of a load-carrying implant (4). It is now said that an implant is regarded as osseointegrated when there is no progressive relative movement between the implant and the bone with which it has direct contact (2). In practice, this means that in osseointegration there is an anchorage mechanism whereby nonvital components can be reliably and predictably incorporated into living bone and that this anchorage can persist under all normal conditions of loading (5).

Experimental Studies

The initial observations of osseointegration were made in the 1950s during the study of the circulation in bone marrow (6). In a modification of the rabbit ear chamber, a titanium implant with a central canal and a transverse opening at one level was threaded into bone to allow bone and vessels to grow into the chamber. It occurred to this investigator that such integration of titanium screws and bone might be useful for supporting dental prostheses on a long-term basis. Thus began a continuing program of research and clinical use of titanium implants.

Study of the biomechanics of osseointegration was a key early research activity, which was overseen by Professor Richard Skalak (7). Detailed biomechanical tests were performed by R. Brånemark and coworkers to evaluate implants during healing, after irradiation, in experimental arthritis, in osteoarthritis and rheumatoid arthritis, and *in vivo* in rat, rabbit, dog, and man (8). This series of studies provided evidence that the biomechanics of bone-anchored implants are complex. There was a plastic deformation of the bone-implant interface subjected to shear, and no elastic deformation was observed. In pullout and lateral load tests the load-deformation curve showed an elastic behavior, indicating that these tests mainly reflect the mechanics of the surrounding bone. In dental applications, the clinical experience is now sufficient in length of time and in total patient numbers to say that neither stress shielding nor fatigue appear to be limiting factors in the long-term successful function of titanium dental fixtures (9).

Titanium Properties

A thin oxide layer covers the surface of pure titanium after being spontaneously formed at atmospheric conditions. More extensive oxide growth occurs on titanium implants subjected to biological tissues (10). Inflammatory cells, especially macrophages, may contribute to development of the oxide layer by excreting proteolytic enzymes, cytokines, superoxide, and hydrogen peroxide (11). It is hypothesized that the actual interface of the titanium implant to the living tissue is a hydrated titanium peroxy matrix (**Figure 1**). The formation of such a matrix is unique to titanium, as the other possible transition metals either have too low solubility of their peroxy complex or too low stability of the complex.

Osseoperception

Osseoperception is the term used to describe the ability by patients with osseointegrated fixtures to identify tactile thresholds transmitted through their prostheses.

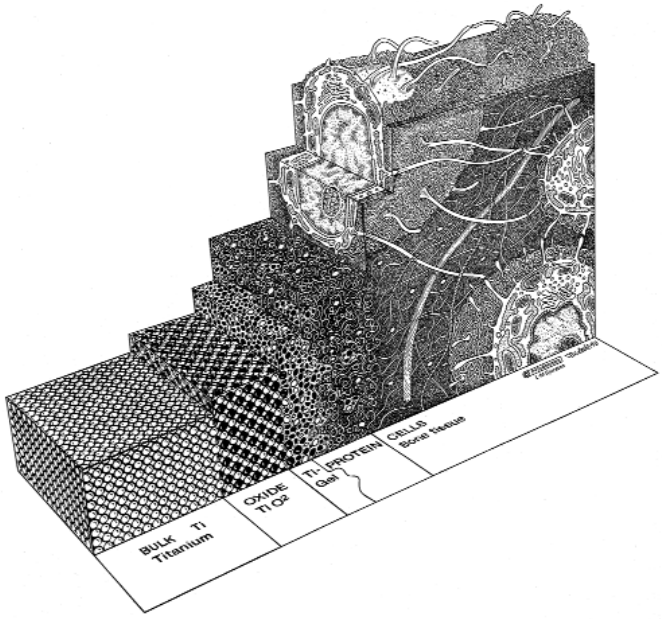

Figure 1.
An artist's view of the titanium/tissue interface. The oxide of titanium is covered with a very thin layer of titanium peroxy compounds, which are in contact with the living bone. From (11) with permission.

It is a phenomenon of importance in both dental and orthopaedic applications of osseointegration.

The identification of osseoperception as a phenomenon of osseointegration was the result of work carried out in the dental sciences by Torgny Haraldson (12). In 1979 he characterized the sensory feedback in patients with osseointegrated bridges and concluded, "Patients with osseointegrated bridges have been restored to a level of functional capacity of the masticatory system equal to that in individuals with a natural but reduced dentition of the same extension as in the osseointegration group."

Osseoperception has also been studied in orthopaedic applications. Experimentally, vibratory perception around implants in the femoral, tibial, ulnar, radial, and (meta)carpal bones has been assessed by means of the psychophysical threshold determination of passive stimuli applied to the implants, whereby the subject has to answer whether he/she detects the stimulus or not. Experiments were carried out on two groups of patients who had suffered limb amputation (13). Group 1 consisted of amputees who had been rehabilitated by means of prostheses supported by osseointegrated implants. Group 2 consisted of amputees wearing conventional socket prostheses. For each subject in Group 1, a subject of the same gender with a comparable age and amputation level was selected to participate in Group 2. Vibratory threshold determination was carried out on the control limb and the prosthetic limb of all amputees. For transfemoral or transtibial amputees, the great toe (I) and the little toe (V), or the metatarsal, were tested. For transhumeral or transradial amputees, the thumb, the index finger (II), and the little finger (V) were tested. This method was also applied for threshold determination of the stump of amputees in Group 2 to compare these values to implant-stimulation threshold.

The measured perception of vibration with an osseointegrated amputation prosthesis in place was generally comparable to that of the normal contralateral hand or foot. This was different from the corresponding measurements obtained with a conventional amputation prosthesis. This finding has recently been repeated in a series of 32 patients, and it was further documented that bone-anchored prostheses yielded better perception than socket prostheses (14). These tests suggest that direct stable and permanent anchorage of amputation prostheses to the skeleton via osseointegrated fixtures and skin-penetrating abutments will be a useful clinical technique that improves an amputee's perception of the environment. As described below, an important current application of osseoperception is its use in providing for hearing prostheses.

ESTABLISHED CLINICAL APPLICATIONS OF OSSEOINTEGRATION

Osseointegration provides an attachment mechanism for the incorporation into living bone of nonvital components made of titanium. As a biological phenomenon it has been amply demonstrated and clinically tested, and is now widely accepted. The present range of clinical applications is as follows:

Dental

In the field of oral surgery, the most common application of osseointegration has been the dental and oral reconstruction of patients who have lost teeth. The anatomical and functional rehabilitation after the loss of teeth implies replacement of the teeth and part of the surrounding tissues because the loss of teeth results in involution of periodontal tissues. Osseointegration has been used for the replacement of missing single teeth, for the restoration of the partially edentulous segment of the mouth, and for the reconstruction of the completely edentulous patient by means of implant-supported fixed bridges or removable overdentures that attach to an implant-supported framework (15).

The superior performance of osseointegration in dental applications by comparison with other techniques has been confirmed in a number of multicenter studies (16). Worldwide, more than 800,000 patients have been treated since 1965 until now with osseointegration dental reconstructions, according to Brånemark. The results indicate a clear superiority over conventional prosthodontics, with respect to long-term success rates (17,18). It should be pointed out that osseointegration in dental sciences has been the subject of more than 2,000 scientific articles, thus creating a solid research and clinical basis for this treatment modality.

Continued development and adaptation of surgical and prosthetic procedures has allowed rehabilitation even of patients with extensive loss of alveolar jawbone, including discontinuities of the jaw skeleton, whether congenital, posttraumatic, or after tumor surgery. Autologous bone grafts have proven beneficial in many of these situations in combination with bone-anchored devices. Requirements on precise fitting of prosthetic superstructures exceed those for devices anchored to

teeth, since the osseointegrated fixtures do not adapt to a misaligned prosthetic framework by changing their position in the jawbone. This, on the other hand, means that fixtures can be used in orthodontic procedures.

There has been a rapid development in orthodontic applications of dental implants to provide anchorage for orthodontic, orthopaedic, and orthognathic movements. One recent young patient with extensive oligodontia has undertaken a program of several steps (19). The initial step was the replacement of the missing mandibular dentition anterior to the molar teeth by implant-anchored bridgework. Subsequently, implants were placed in the missing maxillary cuspid areas to initially provide anchorage for orthodontic realignment of the premolar teeth and to thereafter provide support for freestanding single-tooth implant restorations. Pterygoid plate maxillary fixtures were used to provide distal support for the bridgework.

Facial Prostheses

Complex problems of facial tissue loss are often amenable to management by means of implant-supported maxillofacial prostheses (**Figure 2**). Many previously irradiated patients have been treated successfully with implant reconstructions. One such patient had a hemimandibulectomy performed as part of her ablation and the surgery was followed by radiation. After reconstruction of the mandible with a bone graft and prophylactic hyperbaric oxygen, implants were used to stabilize a full fixed lower partial denture (2).

Extraoral applications of osseointegration include anchorage for craniofacial prostheses including ear, eye, and nose. When the external ear has been removed due to tumor or trauma, a satisfactory replacement can be made by the maxillofacial prosthodontist and the artificial pinna is anchored to the temporal bone by means of special implants. In a similar manner, implants placed around the orbital rim can be used to anchor an orbital prosthesis. These facial prostheses are more hygienic, comfortable, and satisfactory than earlier models retained with adhesives (2).

Hearing Aids

Difficulty in hearing is the most common handicap in the world. The vast majority of these cases have a sensorineural loss, though some also have a sound transmission loss from the outer ear to the sensorineural pathways. These patients can be benefited by a bone-anchored hearing aid (BAHA)(20). Now, thousands of patients worldwide have benefited from the use of BAHA, using essentially the same osseointegrated titanium flange originally designed by Brånemark and Kuikka in 1977.

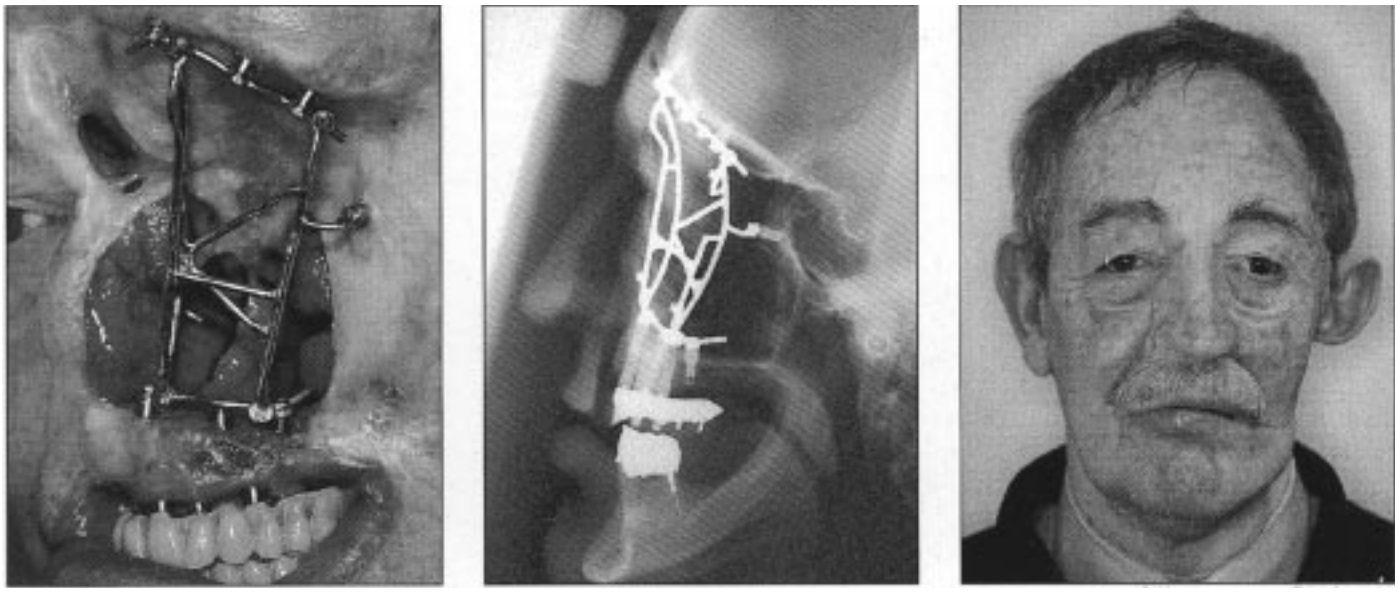

Figure 2.
Major maxillofacial defect after tumor resection and radiation therapy. Reconstruction with autologous bone graft and osseointegration was performed after preoperative hyperbaric oxygen treatment. A bone-anchored maxillary bridge and a fixture-retained maxillofacial prosthesis restores adequate anatomy and function. From Tjellström A, Jansson K, Brånemark P-I. Craniofacial defects. In: Worthington P, Brånemark P-I, editors. Advanced Osseointegration Surgery: Applications in the Maxillofacial Region. Chicago: Quintessence, 1992; 293–312. With permission.

DEVELOPING CLINICAL APPLICATIONS OF OSSEOINTEGRATION

Osseointegration has made possible the development of a number of clinical applications in the field of hand surgery and orthopaedics. There are a number of conditions and diseases that represent a major challenge in relation to rehabilitation and restoring lost function. These include the rheumatoid arthritis patient in whom the destruction of the synovial joints is a particularly challenging problem for the orthopaedic surgeon and hand surgeon. The treatment of destroyed metacarpophalangeal joints in the hand has been achieved through the use of osseointegration, whereby titanium fixtures are installed in the phalangeal and metacarpal bones and linked by a joint prosthesis. This allows the severely deformed hand to be reconstructed to allow a more normal anatomical appearance and also to obtain major improvement of hand function.

Other major challenges in orthopaedics and hand surgery relate to the amputation of digits and upper and lower limbs. Amputations have been performed for much of human history, mostly following trauma as a salvage procedure carried out for the treatment of war victims. Today, the majority result from vascular disorders such as atherosclerosis and diabetes, and from tumor, although trauma still remains a major cause. Examples of osseointegration solutions to these problems are outlined in the following sections.

Finger Joint Prostheses

Patients suffering from rheumatoid arthritis, osteoarthrosis, or posttraumatic/postinfectious arthrosis often present with considerable impairment in hand function. Traditional solutions employed silicon rubber implants (21). Although initial results usually are satisfactory, the friction of silicone moving against bone may eventually result in progressive bone destruction with subsidence and fracture of the implant as well as progressive stiffness of the hand (22).

Based on the osseointegration principle, Lundborg and Brånemark have led an effort to develop an arthroplasty procedure for the metacarpophalangeal joints to permanently fixate a joint implant to the phalangeal and metacarpal bones without the use of cement (23,24).

The artificial joint consists of two components, the joint mechanism and the titanium fixtures. The screw-shaped titanium fixtures are essentially of the same design as the anchorage elements used for edentulous patients. The artificial joint mechanism consists of a constrained flexible silicone spacer, each end being mounted on a titanium plate with a short stem, designed to fit into a central longitudinal cylindrical channel in each fixture (**Figure 3**). The surgical procedure involves the drilling of longitudinally cylindrical channels into the medullary cavities of the metacarpal and phalangeal bones. As with all osseointegration surgeries, special care must be taken not to induce any heat, and therefore no motor-driven drills are used. In the case of rheumatoid patients, it is often necessary to pack the marrow cavities with grafts of cancellous bone and marrow from the iliac crest.

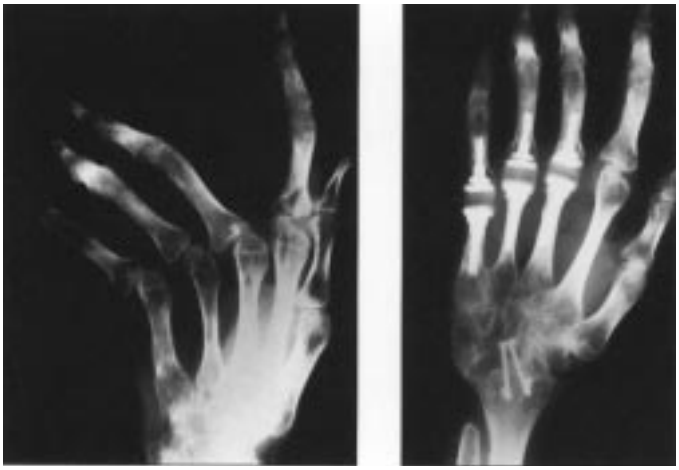

Figure 3.
Example of osseointegration arthroplasty. A 25-year-old female with juvenile rheumatoid arthritis and severe subluxation of the third to fifth metacarpophalangeal joints with ulnar drift of the fingers (left). Radiograph two years following arthroplasty (right). From (24) with permission.

The application of the osseointegration principle to arthroplasty procedures aims at permanent fixation of the implant to the bone without use of cement. In the series by Lundborg and coworkers (24), such osseointegration was regularly achieved, even though the implants were subjected to loading after the fifth postoperative day, and even though some patients were receiving permanent steroid or cytotoxin medication. Although there is potential for damage of the flexible spacer over a long period of time, the procedure allows for replacement of this part. Long-term results out to ten years have been excellent (25). It is important to note that no progressive bone resorption has been observed so far in this series of patients. Thus, this indicates that the problem of fixation of an implant to the bones of the hand may be solved, and that work can be focused on improving the joint mechanisms.

Journal of Rehabilitation Research and Development Vol. 38 No. 2 2001

Thumb Amputations

A small series of patients with traumatic amputation of the thumb at the metacarpophalangeal joint level have undergone a two-stage reconstruction aimed at fixation of a thumb prosthesis to the first metacarpal bone via an osseointegrated titanium fixture (26). The first stage of the procedure included insertion of the fixture into the medullary cavity of the first metacarpal bone in combination with transplantation of cancellous bone from the iliac crest. A period of three months was allowed for the unloaded fixture to become firmly osseointegrated into the bone. The second stage of the procedure involved attachment of a skin-penetrating abutment on top of the fixture and modification of the skin graft to minimize relative mobility. A removable thumb prosthesis can then be attached to the fixture (**Figure 4**). This provides several advantages, such as stable fixation of the prosthetic thumb to the skeleton, restoration of some sensory feedback (osseoperception), as well as an excellent cosmetic result.

Amputation of Lower Limb

Osseointegration has more recently been extended to orthopaedic applications (27). Of particular interest is the treatment of transfemoral amputees where traditional rehabilitation using socket prostheses causes complications related to prosthesis retention and function (**Figure 5**). An ongoing clinical trial in the European Union will soon be able to provide definitive information on the success of this application, and a VA-sponsored laboratory program is focused on the neurobiology of osseointegration, using a rat model of femoral osseointegration (28).

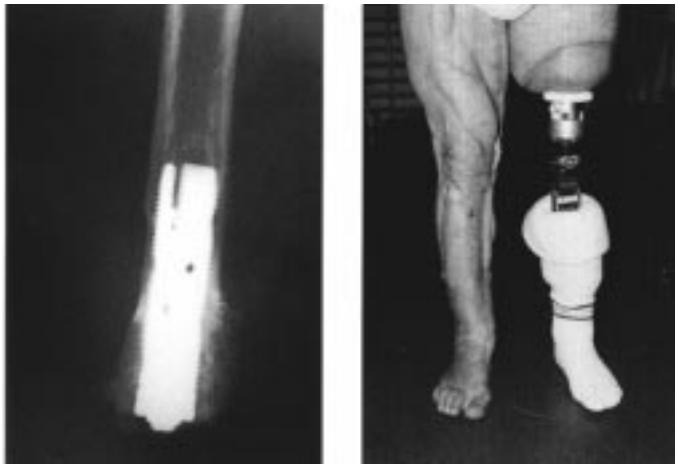

Figure 5.
Transfemoral amputee with osseointegrated limb prosthesis. From (3) with permission.

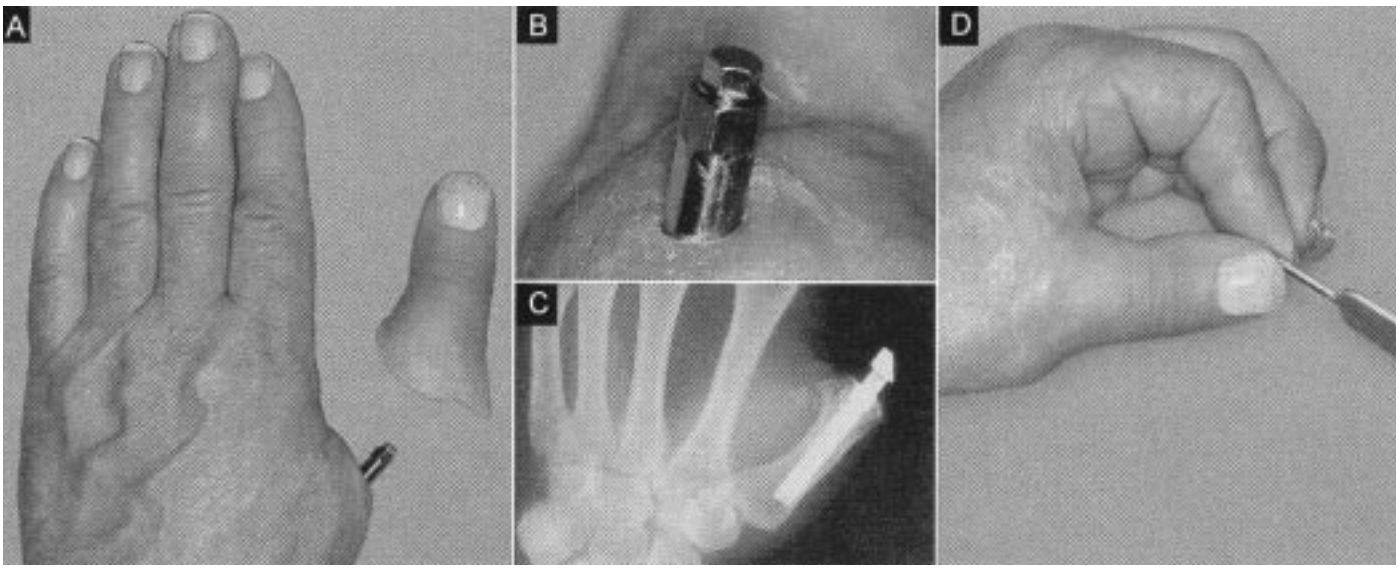

Figure 4.
Thumb amputee provided with an osseointegrated fixture in the remaining carpal bone. The fixture has the capacity to return both mechanical function and sensory capacity (osseoperception). From (3) with permission.

REFERENCES

1. Southam JC, Selwyn R. Structural changes around screws used in the treatment of fractured human mandibles. Br J Oral Surg 1971;8:211–21.
2. Brånemark P-I. Osseointegration and its experimental studies. J Prosthetic Dentistry 1983;50:399–410.
3. Brånemark P-I. Introductory remarks. In: Williams E, Rydevik B, Brånemark P-I, editors. Osseointegration from molecule to man. Institute for Applied Biotechnology, Proceedings of Interdisciplinary Conference, 1999 May 2; Göteborg, Sweden: Artisten.
4. Brånemark P-I, Hansson BO, Adell R, Breine U, Lindström J, Hallán O, Öhman A. Osseointegrated implants in the treatment of the edentulous jaw. Stockholm: Almqvist and Wiksell; 1977. p. 132
5. Worthington P. History, development, and current status of osseointegration as revealed by experience in craniomaxillofacial surgery. In: Brånemark P-I, Rydevik BL, Skalak R, editors. Osseointegration in skeletal reconstruction and joint replacement. Carol Stream, IL: Quintessence Publishing Co; 1997. p. 25–44.
6. Brånemark P-I. Vital microscopy of bone marrow in rabbit. Scand J Clin Lab Invest 1959; Suppl 38.
7. Skalak R. Overview of previous development and biomechanics of osseointegration. In: Rydevik B, Brånemark P-I, Skalak R, editors. International Workshop on Osseointegration in Skeletal Reconstruction and Joint Replacement. The Institute for Applied Biotechnology, Göteborg, Sweden, 1991.
8. Brånemark R. A biomechanical study of osseointegration. *In-vivo* measurements in rat, rabbit, dog and man. Dissertation Research, Gothenburg, Sweden, 1996; ISBN 91-628-2267-5.
9. Skalak R. Biomechanics of osseointegration. In: Brånemark P-I, Rydevik BL, Skalak R, editors. Osseointegration in skeletal reconstruction and joint replacement. Carol Stream, IL: Quintessence Publishing Co; 1997. p. 45–56.
10. Sundgren JE, Bodö P, Lundström I. Auger electronspectroscopic studies of the interface between human tissue and implants of titanium and stainless steel. J Coll Int Sci 1986;110:9–20.
11. Bjursten L-M. The bone-implant interface in osseointegration. In: Rydevik B, Brånemark P-I, Skalak R, editors. International Workshop on Osseointegration in Skeletal Reconstruction and Joint Replacement. The Institute for Applied Biotechnology, Göteborg, Sweden, 1991; p. 25–31.
12. Dahlström L. A summary of the work of Torgny Haraldson. In: Williams E, Rydevik B, Johns R, Brånemark P-I, editors. Osseoperception and musculo-skeletal function. The Institute for Applied Biotechnology, 1999; p. 68–85.
13. Rydevik B. Amputation prostheses and osseoperception in the lower and upper extremity. In: Osseointegration in skeletal reconstruction and joint replacement. Brånemark P-I, Rydevik BL, Skalak R, editors. Carol Stream, IL: Quintessence Publishing Co; 1997. p. 175–82.
14. Jacobs R, Brånemark R, Olmarker K, Rydevik R, Van Steenberghe D, Brånemark P-I. Evaluation of the psychophysical detection threshold level for vibrotactile and pressure stimulation of prosthetic limbs using bone anchorage or soft tissue support. Prosthet Orthot Int 2000;4:133–42.
15. Worthington P. Current status of osseointegration. In: Rydevik B, Brånemark P-I, Skalak R, editors. International Workshop on Osseointegration in Skeletal Reconstruction and Joint Replacement. The Institute for Applied Biotechnology, Göteborg, Sweden, 1991; p. 17–20.
16. van Steenberghe D. Results of osseointegration in complete and partial edentulism. In: Rydevik B, Brånemark P-I, Skalak R, editors. International Workshop on Osseointegration in Skeletal Reconstruction and Joint Replacement. The Institute for Applied Biotechnology, Göteborg, Sweden, 1991; p. 43–50.
17. Adell R, Ericksson B, Kekholm U, Brånemark P-I, Jemt T. Long-term follow-up study of osseointegrated implants in the treatment of totally endentulous jaws. Int J Oral Maxillofac Implants 1990;5:347–59.
18. Esposito M, Hirsch JM, Lekholm U, Thornsen P. Biological factors contributing to failures of osseointegrated oral implants. (I). Success criteria and epidemiology. Eur J Oral Sci 1998;106:527–51.
19. Henry PJ. Osseointegration in dentistry. In: Williams E, Rydevik B, Brånemark P-I, editors. Osseointegration from molecule to man. Institute for Applied Biotechnology, Proceedings of Interdisciplinary Conference, 1999 May 2; Göteborg, Sweden: Artisten; p. 2–12.
20. Tjellström A. To hear or not to hear. In: Williams E, Rydevik B, Brånemark P-I, editors. Osseointegration from molecule to man. Institute for Applied Biotechnology, Proceedings of Interdisciplinary Conference, 1999 May 2; Göteborg, Sweden: Artisten; p. 47–9.
21. Swanson AB. Flexible implant arthroplasty for arthritic finger joints: Rationale, technique and results of treatment. J Bone Joint Surg 1972;54A:435–55.
22. Hagert CG, Eiken O, Ohlsson NM, Aschan W, Movin A. Metacarpophalangeal joint implants. I. Roentgenographic study on the silastic finger joint implant, Swanson design. Scand J Plast Reconstr Surg 1975;9:147–57.
23. Lundborg G, Brånemark P-I, Carlsson I. Metacarpophalangeal joint arthroplasty based on the osseointegration concept. J Hand Surg 1993;18B:693–703.
24. Lundborg G. Osseointegrated metacarpophalangeal joint prostheses in the hand. In: Brånemark P-I, Rydevik BL, Skalak R, editors. Osseointegration in skeletal reconstruction and joint replacement. Carol Stream, IL: Quintessence Publishing Co, 1997; p. 167–74.
25. Lundborg G, Brånemark P-I. Osseointegrated proximal interphalangeal joint prostheses with a replaceable flexible joint spacer–Long term results. Scand J Plast Reconstr Hand Surg 2000;34:345–53.
26. Lundborg G, Brånemark P-I, Rosen B. Osseointegrated thumb prostheses: a concept for fixation of digit prosthetic devices. J Hand Surg (Am) 1996;221:216–21.
27. Brånemark P-I. Osseointegration in orthopaedic surgery. In Dolci G, Favero GA, editors. Proceedings of First World Congress of Osseointegration, Venice, 1994; p. 17–8.
28. Ysander M, Brånemark R, Olmarker K, Myers RR. Intramedullary osseointegration. Development of a rodent model and study of histology and neuropeptide changes around titanium implants. J Rehabil Res Dev 2001;38:183–190.