Department of Veterans Affairs

JRRD Volume 46, Number 3, 2009
Pages 385–394
Journal of Rehabilitation Research & Development

Early delayed amputation: A paradigm shift in the limb-salvage time line for patients with major upper-limb injury

Todd E. Burdette, MD;[1*] Sarah A. Long, BA;[2] Oscar Ho, MD;[1] Chris Demas, MD;[1] John-Erik Bell, MD;[3] Joseph M. Rosen, MD[1]

[1]Department of Surgery, Section of Plastic Surgery, Dartmouth-Hitchcock Medical Center, Lebanon, NH; [2]Thayer School of Engineering, Dartmouth College, Hanover, NH; [3]Department of Orthopaedics, Dartmouth-Hitchcock Medical Center, Lebanon, NH

Abstract—Patients with major injuries to the upper limbs sometimes fail to achieve successful limb salvage. During the attempt to fashion a functional limb, multiple painful procedures may be ventured. Despite the best efforts of surgeons and therapists, a nonfunctioning or painful upper limb may remain in place for many months or years before late delayed amputation and progression to productive rehabilitation occur. We present three patient cases that illustrate failed upper-limb salvage. In each case, patients expressed a desire for amputation at 6 months after their injury. To reduce the pain and suffering that patients with failed limb salvage endure, we propose a paradigm shift in the limb-salvage time line. We suggest that patients be evaluated for early delayed amputation 6 months after their injury.

Key words: amputation, limb salvage, limb-salvage score, pain, phantom pain, prosthesis, rehabilitation, upper extremity, upper limb, therapy.

INTRODUCTION

> "In each case the surgeon faces a vast number of decisions and has considerable latitude to exercise personal judgment."
>
> —Douglas Smith, MD [1].

Treating patients with major upper-limb injuries is complex. The decision to reconstruct or amputate is difficult, and our ability to predict which limbs should be salvaged is not well informed [2]. We have identified a subset of patients with major upper-limb injuries who choose amputation. Typically, this choice occurs after exhaustive salvage efforts have failed over the course of months to years.

We believe that the best way to improve treatment for patients with major upper-limb injury is not to devise a better limb-salvage scoring system but to reevaluate the traditional limb-salvage time line (**Figure 1(a)**) to include a new entity: the early delayed amputation. Our proposed, revised limb-salvage time line includes an analysis of rehabilitation progress at 6 months (**Figure 1(b)**). Patients with nonfunctioning, painful, or excessively stiff upper limbs should be offered early delayed amputation. Early delayed amputation would occur about 6 months after injury. This time line allows the patient to observe and accept the disability from the injury but does not prevent initial reconstructive surgery and therapy from attempting function salvage. We chose 6 months because our three patients remember this time as when they knew amputation was inevitable. They each felt that salvage attempts after 6 months were futile.

Abbreviation: MESS = Mangled Extremity Severity Score.

***Address all correspondence to Todd E. Burdette, MD; Resident in Plastic Surgery, Department of Surgery, Section of Plastic Surgery, Dartmouth-Hitchcock Medical Center, One Medical Center Drive, Lebanon, NH 03756; 603-650-5148; fax: 603-650-0911. Email: Todd.E.Burdette@Hitchcock.ORG**

DOI:10.1682/JRRD.2008.08.0110

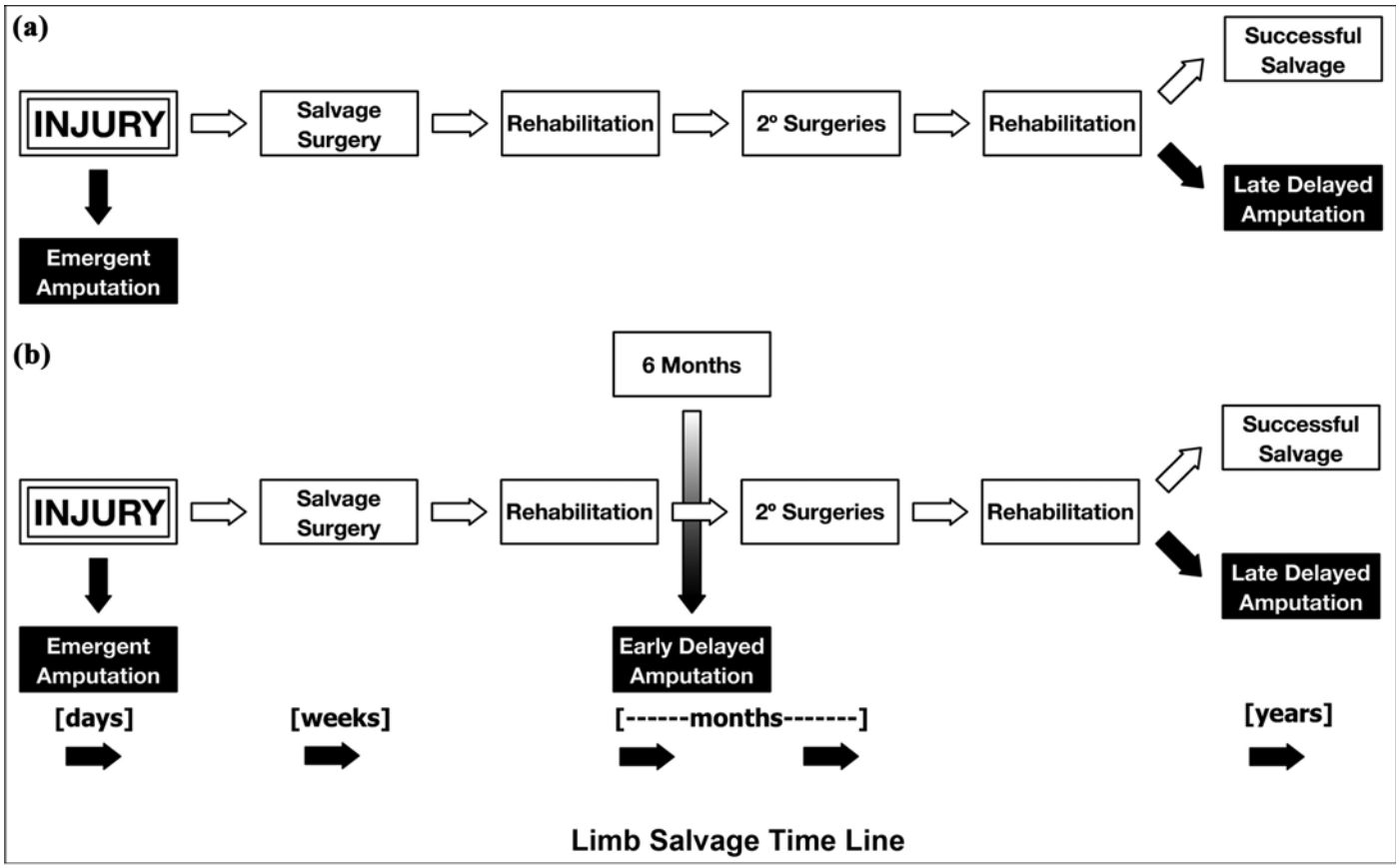

Figure 1.
(a) Default limb-salvage time line. **(b)** Proposed limb-salvage time line that includes analysis at 6 months, early delayed amputation.

Upper-limb amputation is different from lower-limb amputation, and thus, measures for lower-limb amputation should not be used for upper-limb amputation. For example, surgeons widely agree that a useless, painful leg is an unacceptable outcome of lower-limb-salvage surgery. However, with upper-limb salvage, a useless, painful, or stiff limb may remain in place for many months before late delayed amputation and progression to productive rehabilitation occurs. The reasons for this delay are complex. "Absolute indications" exist for lower-limb amputation, as reported by Lange et al.: warm ischemia time >6 hours, disruption of the tibial nerve in an adult, and threat to life in the attempt [3]. Except for the threat to life in the attempt, no "absolute indications" exist for upper-limb amputation. Also, upper-limb prostheses do not restore function to the same extent that lower-limb prostheses do, another factor contributing to late delayed amputation of the upper limb. Therefore, limb salvage at all costs has become the default treatment modality for the upper limb (**Figure 1(a)**).

The concept that prolonged salvage efforts may inhibit a patient's recovery is gaining traction in the limb-reconstruction community. Pinzur et al., in their article "Controversies in lower-extremity amputation," write that ". . . amputation surgery is reconstructive surgery. It is the first step in the rehabilitation process for patients with an amputation and should be thought of in this way. An amputation is often a more appropriate option than limb salvage, irrespective of the underlying cause" [4].

We believe that the best way for patients to progress to productive rehabilitation is to give limb salvage a judicious trial (i.e., 6 months) but then offer early delayed amputation if the patient believes that function, pain, or stiffness are unacceptable.

METHODS: CASE SERIES

We did not obtain institutional review board approvals for this study because only patient case studies were

involved. However, we obtained informed consent from all three patients and present each case illustrating failed upper-limb salvage.

Case Report 1

A 44-year-old male truck driver and furniture delivery worker sustained a significant crush injury to his dominant right hand in a forklift accident. Reconstruction included emergent fasciotomies, release of the carpal tunnel, and microvascular repairs of the middle and ring fingers. Significant bony injuries were stabilized with multiple pins (**Figure 2**).

On the fifth postoperative day, the patient was discharged with all fingers viable. His postoperative course was complicated by osteomyelitis of the index metacarpal, requiring placement of an antibiotic spacer (**Figure 3**) and long-term intravenous antibiotic therapy. His infection was eventually controlled, but significant pain, stiffness, and tendon adhesions in his right hand left him with limited motion. Aggressive hand therapy had been initiated early in his postoperative course with little improvement.

Six months after the injury, the patient was exhausted with therapy and discouraged with lack of progress. His right hand was painful and nonfunctional (**Figure 4**). He asked for an amputation. Consultations with multiple hand surgeons recommended waiting at least 1 year. Further tendon release operations were offered and refused. The patient continued with therapy but progressed little. Thirteen months postinjury, a transradial amputation was performed (**Figure 5**). A second procedure 6 weeks later consolidated the residual limb and he was fitted with a myoelectric prosthesis.

Since that fitting, he is training with a therapist to master the myoelectric prosthesis (**Figure 6**) and is using it a few hours a day, mostly to grasp and stabilize objects. He is not working, because his employer cannot find appropriate modified tasks. He feels the residual limb alone is more useful than the reconstructed hand because

Figure 2.
Case report 1 of male patient. Radiograph of initial postoperative pinning of dominant right hand.

Figure 3.
Case report 1 of male patient. Radiograph of antibiotic spacer placed in right hand because of osteomyelitis of index metacarpal.

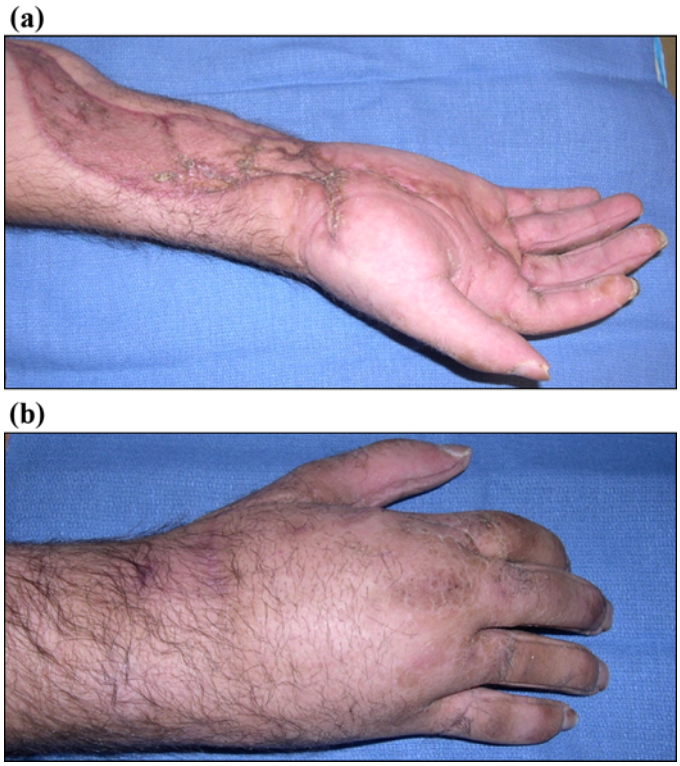

Figure 4.
Case report 1 of male patient. **(a)** Volar surface and **(b)** dorsum of stiff atrophic limb 6 months after initial injury.

Figure 5.
Case report 1 of male patient. Residual limb 13 months postinjury after a transradial amputation was performed before revisional surgery to improve socket fit.

the stiff painful appendage is gone. He uses the residual limb to carry grocery bags and stabilize containers, tasks he could never do with his injured hand. His pain is much reduced, and he wishes he had undergone the amputation 6 months after the injury when his therapy had reached a plateau.

Figure 6.
Case report 1 of male patient. Prosthesis in place 18 months after initial injury.

Case Report 2

A 32-year-old male involved in a motorcycle accident sustained a severe multisystem trauma, including a closed-head injury and scapulothoracic dissociation of his upper limb involving his brachial plexus. His neurological injury was severe, with no motor function except in his trapezius and chronic neuropathic pain. Computed tomography demonstrated a brachial plexus injury involving nerve root avulsions from cervical level 5 to thoracic level 1 (**Figures 7**–**8**).

Six months following his injury, he still had a "flail arm" with no volitional motor activity except in the trapezius. He developed profound atrophy of his hand, forearm, biceps, triceps, deltoid, and shoulder girdle musculature, and his shoulder would spontaneously dislocate multiple times a day. The weight of the injured arm constantly hindered him. A brachial plexus reconstruction was attempted

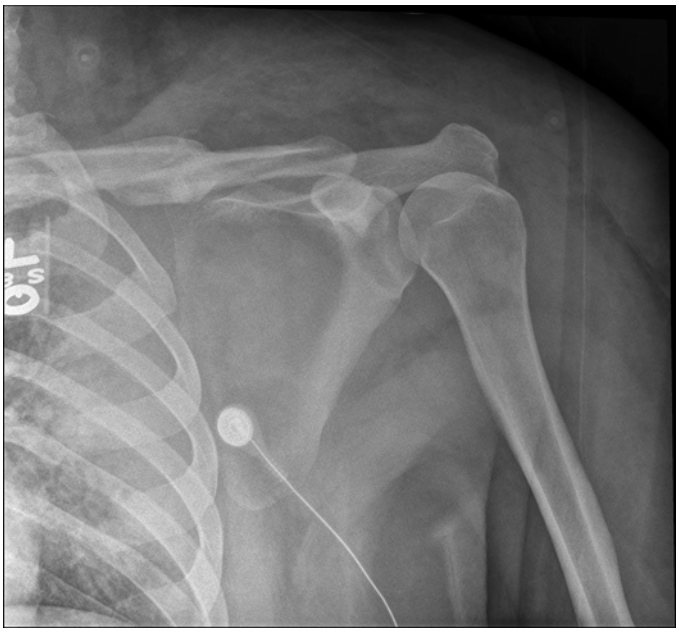

Figure 7.
Case report 2 of male patient. Anteroposterior radiograph of left shoulder demonstrates typical findings of scapulothoracic dissociation. Scapula is lateralized significantly and acromioclavicular joint is widened. Patient also has old healed clavicle fracture.

Figure 8.
Case report 2 of male patient. Anteroposterior radiograph of left shoulder taken 7 months after scapulothoracic dissociation demonstrates profound deltoid wasting and instability of glenohumeral joint with widened joint space and inferior subluxation at rest.

at this time; however, no suitable nerve roots were identified. Retrospectively, he identifies this time as when he decided to pursue amputation.

Thirteen months after the initial injury, with no clinical or electromyographic evidence of recovery, the patient underwent transhumeral amputation and shoulder arthrodesis (**Figure 9**). He recovered without any wound complications, and the shoulder fusion consolidated uneventfully.

Because of insurance coverage problems, his prosthetic fitting was delayed. He was fitted with a myoelectric prosthesis 20 months after the initial injury. The prosthesis provides elbow flexion and extension (controlled by contralateral pectoralis major), pronation and supination (controlled by contralateral latissimus), and pincer function (controlled by ipsilateral trapezius) (**Figure 10**).

Twenty-six months after the injury and seven months after his fitting, his chief complaint is persistent phantom pain, which is exacerbated by attempts to control the prosthesis and is the reason he gives for limited use of the prosthesis. He is, however, pleased with the cosmetic appearance of the prosthesis. He is most satisfied with the stable shoulder arthrodesis and amputation, because he no longer dislocates his shoulder and the flail arm no longer gets in his way. He is in vocational rehabilitation and learning to use a computer through voice commands.

Case Report 3

A 61-year-old male emergency department physician sustained a traumatic left distal radius amputation when a jack failed while he was changing a car tire. Replantation was performed 8 hours after the accident (**Figures 11–14**). In this case, the limb underwent warm ischemia time until the patient arrived at the first hospital, after which he was transferred by air to a transplant center. Less than half of the total time was warm ischemia time. The artery and the vein were immediately shunted, as shown in **Figure 12**.

The initial postoperative course was encouraging, but sensory and intrinsic motor reinnervation failed to occur. The wrist was unstable, requiring constant bulky splintage. Neuromas and wrist pain continued to plague him. Significant stiffness, despite aggressive hand therapy, prevented function of the extrinsic muscles.

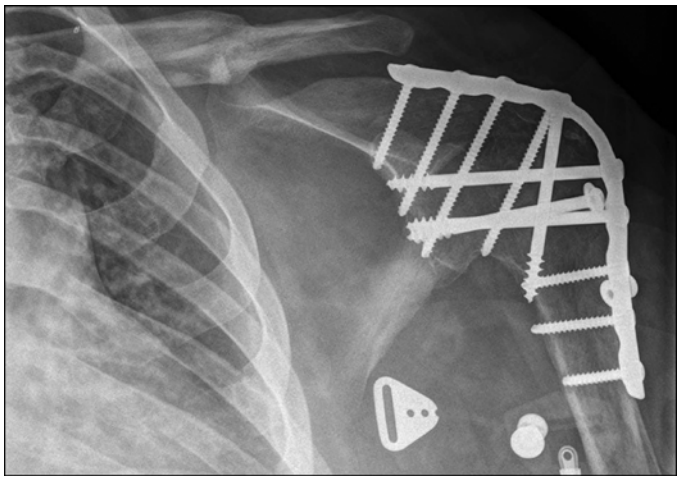

Figure 9.
Case report 2 of male patient. Postoperative anteroposterior radiograph demonstrating left shoulder arthrodesis using contoured 4.5 mm low-contact dynamic compression plate and 6.5 mm lag screws.

Figure 10.
Case report 2 of male patient. Customized myoelectric prosthesis with pincer attachment 20 months postinjury.

At 6 months, he was investigating delayed amputation. He spent the next 4 months in a complex decision-making mode. His replantation team disagreed on the course of action. The plastic surgeons were recommending tenolysis and wrist arthrodesis, while the orthopedists were recommending watchful waiting for return of sensation. He chose the latter course. The replanted hand continued to need constant protection and splinting, and he even had to walk holding it with the "good" hand. This need to support the injured hand effectively disabled both upper limbs. He

Figure 11.
Case report 3 of male patient. Original injury.

Figure 12.
Case report 3 of male patient. Intro-operative image with shunt in place.

noticed the arm and shoulder muscles on the injured side atrophying from disuse.

No return of sensation occurred, and 10 months after his injury, a delayed transradial amputation was performed. He immediately found that the residual limb alone was better than his fragile, unstable, painful hand. He initially had increased discomfort from phantom pain. The phantom pain subsided, and 12 months after the injury, he was fitted with a prosthesis (**Figure 15**).

He has not been able to return to work as an emergency department physician, because he lacks the two-handed dexterity required for emergent procedures, but is very active with his small farm and hobbies. He currently uses a body-powered hook for heavy work on his farm. He uses a

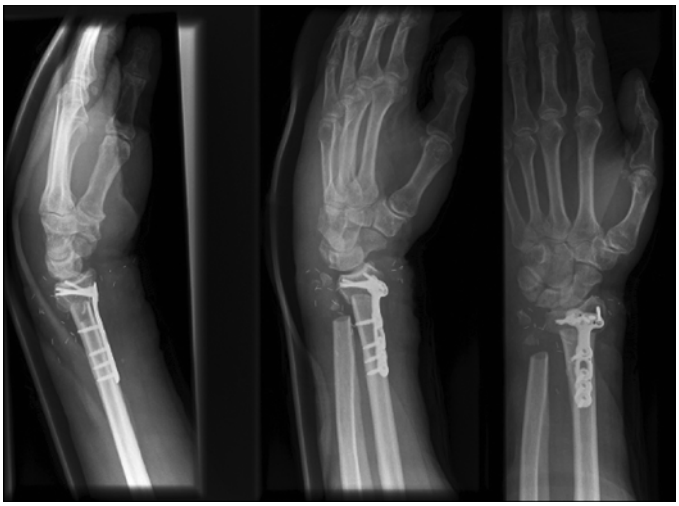

Figure 13.
Case report 3 of male patient. Early postoperative radiograph.

Figure 14.
Case report 3 of male patient. Early postreplant result.

myoelectric pincer for fine work such as reconditioning personal computers. He has a myoelectric hand that is cosmetically superior for what he calls "dining and dancing."

In a recent interview, he stated that ideally he would have had the amputation at the 6-month point. He feels this would have facilitated earlier prosthesis fitting.

RESULTS AND DISCUSSION

The first patient in our series requested amputation 6 months into his limb-salvage sequence. His rehabilitation had reached a plateau, and he had lost hope for successful salvage. He eventually underwent late delayed amputation

Figure 15.
Case report 3 of male patient. Residual limb and prostheses 12 months postinjury (showing both body-powered and myoelectric prostheses).

13 months after his injury. Our second patient also concluded at 6 months that he needed an amputation, but did not obtain it until 7 more months had passed. The third patient was clear about his need for amputation at 6 months but continued 4 months of consultation and therapy before he eventually convinced his surgeons to amputate 10 months after injury.

In our experience, patients who choose late delayed amputation seem to share certain characteristics. Their reconstructed limb is relatively nonfunctional, and they are asking for amputation. Patients in our series began asking for therapeutic amputation consistently 6 months after injury.

The correct time to offer amputation to a patient with major upper-limb injury is unknown. Conventional surgical wisdom has been to pursue limb salvage for 1 to 2 years before considering amputation. We speculate that this decision is based on reports of functional nerve recovery up to 2 years after injury in the lower limb or brachial plexus [5–6]. Alternatively, secondary salvage operations,

such as tendon transfers and nerve grafting, are often performed in the first year after a major upper-limb injury, prolonging the time line. Even limited residual upper-limb function is widely held as better than that which a prosthetic can provide; so patients with major upper-limb injury may pursue multiple procedures and rehabilitation protocols to maximize limb functionality. The result is that some patients with major upper-limb injuries are still pursuing salvage 1 to 2 years after injury, although they and their care team may suspect it is futile [1].

We propose a new time line for limb salvage, as diagrammed in **Figure 1(b)**. We propose that limb salvage should be pursued vigorously in all patients except those who require life-saving amputation or who have obviously unsalvageable limbs. Scoring systems to attempt to predict which limbs should be amputated should be abandoned. Patients should be reevaluated at 6 months after injury and offered amputation if they believe that useful function is not achievable. Six months is the ideal time (neither too early nor too late) for evaluating early delayed amputation. Even in patients with atrophy from disuse or denervation, clinical evidence for denervation may take months to develop. Also revision surgeries and/or hand therapy may be able to salvage useful function up to 6 months after the operation. Those patients who choose amputation at 6 months should be offered prosthesis fitting within 12 weeks of amputation for maximizing their chances of success. Those who choose further salvage should be offered the reconstruction and rehabilitation best suited to their injury.

Through a review of the literature on limb-salvage scores of the upper limb [2,7–9], we have concluded that their use should be abandoned. Their scoring systems are flawed and the stakes are too high. The finality of amputation should not be risked unless it is based on a statistically valid scoring system that currently does not exist. If amputation is decided on the flawed systems described, salvageable limbs might be amputated. No thoughtful person should accept this outcome.

Lower-limb salvage scores, such as the Mangled Extremity Severity Score (MESS) [10], have been modified and applied to the upper limb [2]. However, when satisfactory salvage was reported for limbs with scores above the "cutoff" point, their utility was questioned [2]. The failure of applying lower-limb salvage scores to the upper limb is due the inherent differences in the limbs. The lower limb must bear weight, whereas the upper limb may be quite useful even if it is weak, as long as sensation and flexibility remain. An insensate foot can be used to ambulate, but an anesthetic hand is comparatively less functional. Additionally, functional requirements can be replaced much more easily with a prosthesis in a lower limb than an upper limb. This point is illustrated by the recent banning of South African runner and bilateral transtibial amputee Oscar Pistorius from Olympic trials competition. Regulators cited the "clear competitive advantage" that his prostheses provided [11].

Two recent studies conclude that limb-salvage systems should not be used to pursue limb-salvage surgery [7,12]. Simmons et al., in a study of 41 patients, concluded that predictors of amputation in brachial artery injuries differ from those in lower-limb vascular injuries [7]. Delayed presentation >6 hours, MESS, open fracture, nerve deficits, and diminished capillary refill did not predict later amputation for patients with brachial artery injuries. These data suggested that salvage should be attempted for the vast majority of upper-limb injuries regardless of the severity scoring systems [7]. Ly et al. conducted a study to evaluate the clinical utility of the five commonly used lower-limb injury severity scoring systems as predictors of final functional outcome in >400 patients with lower-limb salvage surgery and at least 2-year follow-up. They concluded that currently available injury severity scores do not predict the functional recovery of patients who undergo successful limb reconstruction [12].

Limb-salvage scoring systems also rely on clinical assessments made at or near the time of injury to predict which limbs will eventually require amputation. Some surgeons believe that early amputation will facilitate eventual recovery. These systems must assess factors such as radiographs, vascular injury, soft-tissue injury scales (e.g., the Gustilo classification), and sensory nerve function. A report from the Lower Extremity Assessment Project group in 2005 described a cohort of 26 patients with severe lower-limb trauma and absent tibial nerve sensation. Of the 26 patients, 25 regained sensation and had similar 2-year outcomes compared with two equivalent groups: those with intact sensation and those who had early amputation [6]. This distressing finding underscored the unreliability of the sensory examination in the acute setting.

Brachial plexus injuries demonstrate the importance of neural function for upper-limb rehabilitation. Manord et al. reported results from a study of 43 patients with delayed nerve repair after brachial plexus injuries [8]. One patient eventually underwent late delayed amputation for a painful, nonfunctional limb. The remaining

42 patients' disability scores improved after nerve repair. At most, they obtained stabilizing functions so that the other hand could perform fine motor tasks, but this finding suggests that even disrupted nerves can be reconstructed to provide functions equivalent to those that a prosthesis can provide [8]. Vascular injuries also may not reliably indicate eventual amputation. Clouse et al. reported 43 major vascular injuries to upper limbs in the military conflicts that began in 2003 [9]. Although this was a short follow-up study, 9 percent of the limbs went on to amputation, but the rest were salvaged.

The current wartime theaters in Iraq and Afghanistan had produced 105 upper-limb amputations as of 2006. Of these amputations, 95 percent were performed early in the evacuation sequence, before the patients reached definitive care. Neurovascular status was not the decisive factor in these amputations [13]. Thus, limb-salvage scores, which usually rely on extent of neurovascular injury, will not likely improve our treatment of patients in these theaters. We conclude that the decision to amputate cannot practically be made in the first several hours to weeks after the injury. The stakes are too high and the scoring systems too unreliable.

Timing, however, is paramount in amputation and prosthesis fitting. Longer delays between amputation and prosthesis fitting negatively affect prosthetic usage rates in studies of both upper- and lower-limb amputees [14–17]. A study of 55 upper-limb amputees in England revealed that those who were delayed more than 12 weeks between amputation and prosthesis fitting never returned to gainful employment [15]. Thus, if we can identify those patients who will eventually choose late delayed amputation at 6 months and provide early delayed amputation to those who desire it, along with prompt prosthesis fitting, we can greatly relieve their suffering and move them more quickly to productive rehabilitation and independence.

CONCLUSIONS

We believe that the best way to improve treatment for patients with major upper-limb injury is not to devise a better limb-salvage scoring system but to reevaluate the limb-salvage time line to include a new entity: the early delayed amputation. In our small series, the three patients expressed a desire for amputation at 6 months postinjury. They each prefer their residual limb to the salvaged limb, and the two with transradial amputation find the residual limb alone to be more useful than their salvaged limb. Reevaluation for an early delayed amputation and shared decision making at the 6-month period is a crucial step in treating patients with severely injured, nonfunctional upper limbs. This change in the time line will benefit a small but significant number of patients who might otherwise suffer for months with painful and/or useless limbs when they could move on to productive rehabilitation (**Figure 1(b)**). In the meantime, we expect and eagerly await innovations in upper-limb reconstructive surgery [18] and prosthesis technology that will require another shift in the limb-salvage time line.

ACKNOWLEDGMENTS

Author Contributions:
Study concept and design: T. E. Burdette, S. A. Long, O. Ho, J. M. Rosen.
Analysis and interpretation of data: T. E. Burdette, C. Demas, J. E. Bell, J. M. Rosen.
Drafting of manuscript: T. E. Burdette, S. A. Long.
Critical revision of manuscript for important intellectual content: C. Demas, J. E. Bell, J. M. Rosen.
Financial Disclosures: The authors have declared that no competing interests exist. None of the authors has any affiliations, funding sources, financial or management relationships that would be perceived as potential conflicts or biases with any companies or products that may be shown or mentioned in this article.
Funding/Support: This material was unfunded at the time of manuscript preparation.
Additional Contributions: We wish to acknowledge the patients described in our cases for contributing their stories and images; Kael Nahikian, for assisting with diagrams; and Robyn Mosher, for assisting with editing.
Participant Follow-Up: The authors do not plan to inform participants of the publication of this study.

REFERENCES

1. Smith DG, Michael JW, Bowker JH, editors. Atlas of amputations and limb deficiencies: Surgical, prosthetic, and rehabilitation principles. 3rd ed. Rosemont (IL): American Academy of Orthopaedic Surgeons; 2004.
2. Togawa S, Yamami N, Nakayama H, Mano Y, Ikegami K, Ozeki S. The validity of the Mangled Extremity Severity Score in the assessment of upper limb injuries. J Bone Joint Surg Br. 2005;87(11):1516–19. [PMID: 16260670] DOI:10.1302/0301-620X.87B11.16512
3. Lange RH, Bach AW, Hansen ST Jr, Johansen KH. Open tibial fractures with associated vascular injuries: Prognosis for

limb salvage. J Trauma. 1985;25:203–8. [PMID: 3981670] DOI:10.1097/00005373-198503000-00006

4. Pinzur MS, Gottschalk FA, Pinto MA, Smith DG, American Academy of Orthopaedic Surgeons. Controversies in lower-extremity amputation. J Bone Joint Surg Am. 2007; 89(5):1118–27. [PMID: 17523257]
5. Terzis JK, Vekris MD, Soucacos PN. Outcomes of brachial plexus reconstruction in 204 patients with devastating paralysis. Plast Reconstr Surg. 1999;104(5):1221–40. [PMID: 10513901] DOI:10.1097/00006534-199910000-00001
6. Bosse MJ, McCarthy ML, Jones AL, Webb LX, Sims SH, Sanders RW, MacKenzie EJ; the Lower Extremity Assessment Project (LEAP) Study Group. The insensate foot following severe lower extremity trauma: An indication for amputation? J Bone Joint Surg Am. 2005;87(12):2601–8. DOI:10.2106/JBJS.C.00671
7. Simmons JD, Schmieg RE Jr, Porter JM, D'Souza SE, Duchesne JC, Mitchell ME. Brachial artery injuries in a rural catchment trauma center: Are the upper and lower extremity the same? J Trauma. 2008;65(2):327–30. [PMID: 18695466] DOI:10.1097/TA.0b013e31817fbde4
8. Manord JD, Garrard CL, Kline DG, Sternbergh WC 3rd, Money SR. Management of severe proximal vascular and neural injury of the upper extremity. J Vasc Surg. 1998; 27(1):43–49. [PMID: 9474081] DOI:10.1016/S0741-5214(98)70290-3
9. Clouse WD, Rasmussen TE, Perlstein J, Sutherland MJ, Peck MA, Eliason JL, Jazerevic S, Jenkins DH. Upper extremity vascular injury: A current in-theater wartime report from Operation Iraqi Freedom. Ann Vasc Surg. 2006; 20(4):429–34. [PMID: 16799853]
10. Johansen K, Daines M, Howey T, Helfet D, Hansen ST Jr. Objective criteria accurately predict amputation following lower extremity trauma. J Trauma. 1990;30:568–72. [PMID: 2342140]
11. CBS News [home page on the Internet]. New York (NY): CBS Corporation; c2006–2009 [updated 2008 Jan 14; cited 2008 Aug 30] AP. "Blade Runner" barred from Olympics: Double-amputee sprinter told prosthetic racing blades give him an unfair advantage; [about 6 screens]. Available from: http://www.cbsnews.com/stories/2008/01/14/sports/main3707924.shtml/.
12. Ly TV, Travison TG, Castillo RC, Bosse MJ, MacKenzie EJ; LEAP Study Group. Ability of lower-extremity injury severity scores to predict functional outcome after limb salvage. J Bone Joint Surg Am. 2008;90(8):1738–43. [PMID: 18676906] DOI:10.2106/JBJS.G.00136
13. Stansbury LG, Lalliss SJ, Branstetter JG, Bagg MR, Holcomb JB. Amputations in U.S. military personnel in the current conflicts in Afghanistan and Iraq. J Orthop Trauma. 2008;22(1):43–46. [PMID: 18176164]
14. Gauthier-Gagnon C, Grisé MC, Potvin D. Predisposing factors related to prosthetic use by people with a transtibial and transfemoral amputation—A survey of 396 subjects was conducted to determine factors relating to use of a prosthesis among individuals with transtibial and transfemoral amputation. J Prosthet Orthot. 1998;10(4):99–109.
15. Gaine WJ, Smart C, Bransby-Zachary M. Upper limb traumatic amputees. Review of prosthetic use. J Hand Surg [Br]. 1997;22(1):73–76. [PMID: 9061532]
16. Malone JM, Fleming LL, Roberson J, Whitesides TE Jr, Leal JM, Poole JU, Grodin RS. Immediate, early, and late postsurgical management of upper-limb amputation. J Rehabil Res Dev. 1984;21(1):33–41. [PMID: 6527288]
17. Roeschlein RA, Dumholdt E. Factors related to successful upper extremity prosthetic use. Prosthet Orthot Int. 1989; 13(1):14–18. [PMID: 2717379]
18. Kuiken TA, Dumanian GA, Lipschutz RD, Miller LA, Stubblefield KA. The use of targeted muscle reinnervation for improved myoelectric prosthesis control in a bilateral shoulder disarticulation amputee. Prosthet Orthot Int. 2004; 28(3):245–53. [PMID: 15658637]

Submitted for publication August 31, 2008. Accepted in revised form February 9, 2009.