AMPUTATION

PRINCIPLES AND METHODS

Knud Jansen, M.D.

Chief Orthopaedic Surgeon, Orthopaedic Hospital, Copenhagen
Chairman, International Committee on Prosthetics and Orthotics of the International Society for Rehabilitation of the Disabled

In June 1963, an International Experts Meeting on Prosthetics was held in Virum, Denmark under the chairmanship of Dr. Knud Jansen, author of this article. The meeting was organized by the World Veterans Federation with the cooperation of the International Society for Rehabilitation of the Disabled and with the participation of the United Nations, the World Health Organization, and the European Coal and Steel Community.

The group of experts, representing countries in all parts of the world, offered twenty-seven specific recommendations for improvement of the status of prosthetics and orthotics internationally. These recommendations, as well as summaries of the various discussions, are contained in the report PROSTHETICS, June 17–21, 1963, a publication of the World Veterans Federation.

Many of the recommendations were aimed at improvements in the mechanisms for disseminating information internationally. Several of the recommendations dealt with medical subjects, particularly amputation surgery and amputee management. Recommendation No. 3 of the Virum meeting states "A brief but comprehensive instructional pamphlet on amputee management, recent surgical procedures and the essential principles of prosthetics should be made available to all surgeons and to all physicians responsible for the care of amputees." The conferees agreed that Dr. Jansen's article "Amputation," available in Danish in June 1963, represented such a contribution and therefore that it be translated and disseminated internationally.

The article has been translated into Spanish, French, Serbo-Croatian, English, and possibly into other languages. The World Veterans Federation took a very active part in obtaining these translations. The English version, recently received, has not been published previously in the United States. Therefore, the Editors of the Bulletin of Prosthetics Research are indeed proud to offer this medium through which United States practitioners can be reached. We are also proud to have Dr. Jansen, who serves

as Chairman of the International Committee on Prosthetics and Orthotics, ISRD, as our first contributor from outside the United States.

Please note that this article was originally published in 1963; some changes in surgical and prosthetic techniques have taken place since then. But for many clinicians and certainly for many students, Dr. Jansen's presentation is an excellent and concise summary of reasonably modern practices.

ANTHONY STAROS,
Director, VA Prosthetics Center

AMPUTATION TEAM

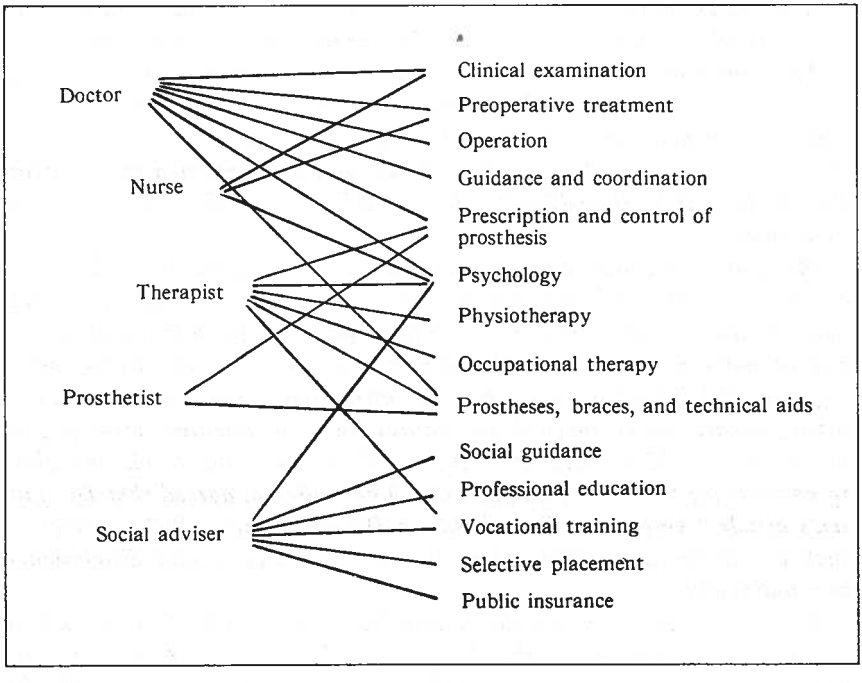

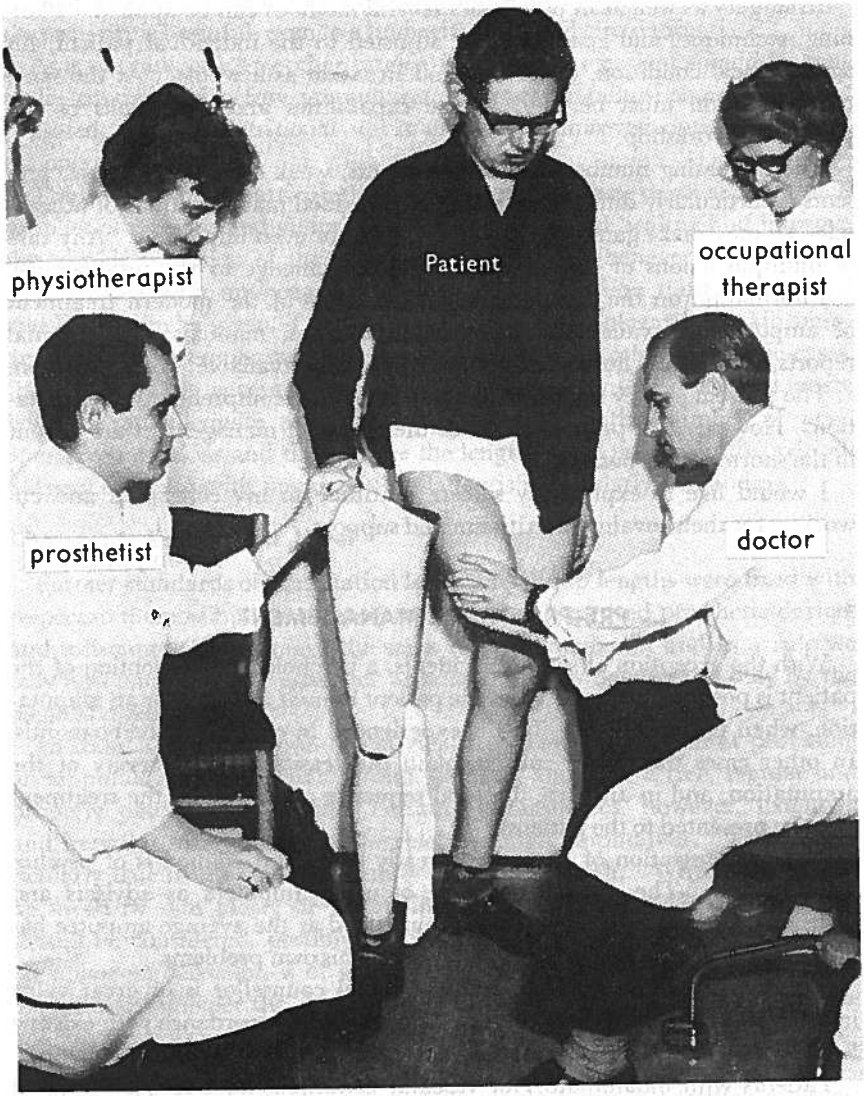

INTRODUCTION

The management and rehabilitation of the amputee is a task so complex that effective cooperation among doctor, nurse, therapist, prosthetist, and social counsellor is a premise to success.

It should not be forgotten that the patient is a member of the team. His belief in the future will condition his willingness and desire to cooperate. The patient's confidence is more easily obtained when the doctor coordinates the various stages of treatment and devotes the necessary time to explaining to the amputee the scheme and scope of the overall management.

In surgery as well as in prosthetics several methods can be applied. Planning, technique, and goals must be adjusted to the individual patient, his age, physical condition, capacities, and situation as a whole. At the same time attention must be paid to the capabilities and limitations of the prosthetics workshop.

The increasing number of elderly patients, weak or atherosclerotic, presents a particularly difficult problem, as the added manifestations of atherosclerosis may make gait rehabilitation difficult or even impossible. Any case of multiple lesions or handicaps presents a challenge to the total service.

Information on the principles and procedures of the modern treatment of amputees is available in special publications, manuals, and original reports, which are not as a general rule easily available to the surgeon.

The present survey does not pretend to offer a comprehensive presentation. However, the principal lines of the course of management are set out in the shortest form possible.

I would like to express my sincere gratitude to my colleagues and coworkers for their invaluable criticism and support.

KNUD JANSEN

PRE-PROSTHETIC MANAGEMENT

With the exception of serious accidents, a psychological perception of the patient is possible. In some cases the patient himself may ask for an amputation, when pain is severe. This is experienced in cases of thromboangiitis. In other cases the doctor must explain the feasibility or necessity of the amputation, and in any case the total sequence and scope of the treatment must be presented to the patient.

The demonstration of amputees already fitted and trained is of psychological value. The general principle of using amputees as advisers and instructors is, however, not to be recommended as the average amputee has difficulty in judging beyond his own force and his own problems.

A preliminary conversation with the social counsellor is of great value in order to outline the possible course to be taken in accordance with existing legal provisions and available funds.

Patients with inflammatory or vascular conditions have frequently spent weeks or months prior to surgery in bed or in a wheelchair. Under such circumstances disabling contractures may easily develop. Such contractures may be prevented when the patient is under medical supervision. It is worthwhile warning against the "nice" pillow under the knee in the bed.

A regimen including exercises with mobilization of all joints every day may prevent such contractures.

Whenever a contracture is observed, it should be treated by passive and active exercises, by correct posture, and by corrective bandages. As prosthetic gait is more demanding than normal gait, a general physical condi-

tioning is essential, when no contra-indications are found. There is no proof that activity is harmful, even to a limb with impaired circulation.

As is the case with any other surgical condition the patient should be generally conditioned before amputation. A cardiac failure should be compensated, and the nutritional status should be improved optimally before the operation.

This precaution is particularly important in elderly patients as additional supplies of proteins and vitamins may promote wound healing and improve the trophic condition of the stump significantly. Whenever a patient has been treated wtih anticoagulants the blood coagulation must be checked and K vitamin be given, if necessary. Finally the importance of skin preparation must be emphasized. In the battlefield or in other traumatic cases, the skin must be accepted as it is found. In cases which are not acute however, an adequate skin condition may reduce the number of post-operative infections and thus reduce the length of the post-operative period. Surgery on limbs with impaired circulation is particularly demanding.

Choice of Amputation Level

Former standards of amputation levels and stump lengths were fixed with respect to the possibilities of prosthetic fitting. Improved prosthetic devices and techniques do not make the same rigorous demands, and as a rule we may now state that the extent of an amputation is determined only by the medical condition.

In traumatic amputation the surgical treatment should aim at providing an amputation stump which is solid, painless, and with a free, regular and properly placed scar. Under certain circumstances, however, extensive and irregular scars may be preferable to a high amputation. This is particularly true in the upper extremity and on the thigh. When a joint may be saved by skin plasty or by preliminary skin grafting these procedures should be considered, possibly supplemented by secondary reconstructions. As preserved sensation is of great importance, extensive irreparable nerve lesions may influence the choice of level. Amputations in vascular cases are actually performed under the same principles, as we remove only the ischaemic, nonviable part of the extremity.

The evaluation of the limit for really viable tissue in vascular disorders is extremely difficult even with the use of angiograms, oscillograms, cutaneous and isotope tests. The final decision may sometimes be made only during the surgical procedure by segmental amputation and estimation of the trophic and vascular state. The choice is most frequently below, through and above the knee. In the pre-operative conversation the patient should therefore learn about and understand this problem.

In amputation surgery for malignant tumors, several specific factors influence our choice of procedure. The pathology, the site of growth, the

age of the patient, X-ray findings, etc., all influence our attitude. In general it is necessary to amputate with a joint separating tumor and amputation level.

In spite of the general principles, practical problems do still cause some limitation of our choice of level.

When an amputation is performed *above* the knee, room should be reserved for a prosthetic knee joint, i.e. the amputation should be done 4–6 inches above the joint level.

On the tibia we are theoretically free, however, if an end bearing stump (Syme's amputation) is not feasible; the distal third or half of the shank may just as well be sacrificed, as we still have a good stump for fitting and better trophic and cosmetic conditions. The musculo-tendinous junction of the gastrocnemius is a suitable *point de repère.*

Amputations on Children

Besides the general problems following amputations, we have to deal with specific problems in children due to the growth of the extremities.

A general warning against any amputation not vitally necessary before the end of growth is justified by experience.

In the leg the major growth potential is related to the distal femoral and the proximal tibial epiphysis. An above-knee amputation therefore tends to get shorter with age whereas the below-knee amputation stump continues to grow and the bones show a tendency to push and penetrate the skin. A disarticulation seems to reduce these problems, and possibly an osteomyoplasty may likewise work better in children.

SURGICAL TECHNIQUE

The aim of surgery is the provision of a stump regularly shaped with normal sensation and without hypersensitive spots. The scar must be solid,

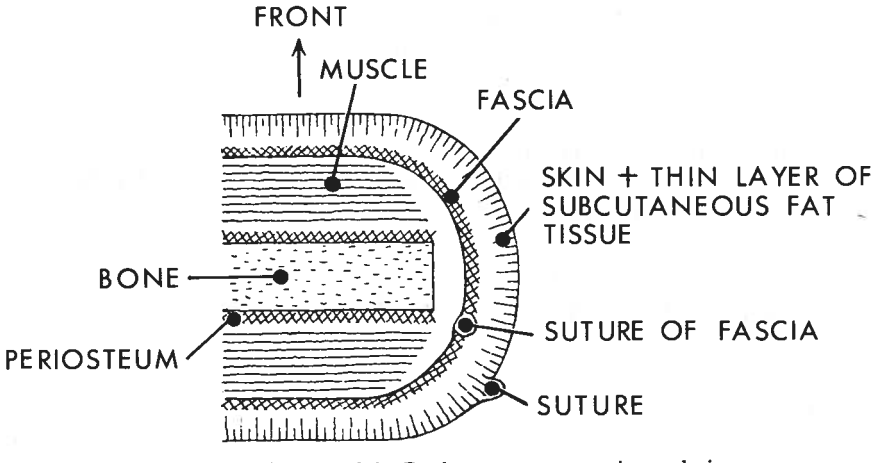

FIGURE 1. Diagram of the Roehampton amputation technique.

movable, and properly placed, i.e. where pressure irritation from the prosthesis is minimal.

Two methods, the conventional and the myoplastic amputation, are used. The choice of procedure will be discussed later.

I. The Conventional Amputation

a) Curved incisions of the skin form a ventral and a dorsal flap with bases at the amputation level.
b) The flaps including skin and fascia are dissected and reflected.
c) Muscles and bone are divided at the bases of the flaps.
d) The nerves are isolated, pulled down gently, and cut cleanly. They should retract for about 1 inch after division.
e) The major vessels are ligated with silk and a careful haemostasis is then performed.
f) The fascia is closed by interrupted silk sutures and the skin with interrupted monofilament nylon.
g) A thin polythene catheter is brought in place through a separate small incision permitting suction drainage for two days. A simple polyvinylchloride bottle may serve as the suction apparatus when squeezed before connection with the tube.
h) The wound is dressed and an elastic stump bandage is carefully applied.

Tourniquet: In cases with normal blood circulation a tourniquet offers a better opportunity for surgery. The tourniquet is released before the detailed haemostasis is performed.

With proper care, the stump is mature for prosthetic fitting after 4–8 weeks.

II. Osteomyoplasty Amputation

a) Skin flaps, ventral and dorsal, must be longer than in the conventional amputation. The length of each should be about 1½ times the diameter of the limb.
b) The fascia may be treated conventionally, or it may be excised at the base of the skin flaps.
c) The muscles are divided 2 inches distally to the level of bonecut.
d) The bone is isolated. Before it is sawn, an osteoperiostal flap is prepared from the part of the bone which is to be removed. The flap is sutured to the periosteum to cover the bone end and the bone marrow cavity.
e) The nerves are pulled down and divided.
f) Haemostasis is carried out.
g) The antagonists are united by silk or catgut suture distally to the bone end. NB: It is essential that the limb be placed in a neutral position during this procedure. A permanent contracture is otherwise created.
h) Suction drainage is put in place and the skin is closed.
i) Normal dressing and stump bandage. Instead of an elastic bandage it may be an advantage to wrap the stump moderately padded, in plaster

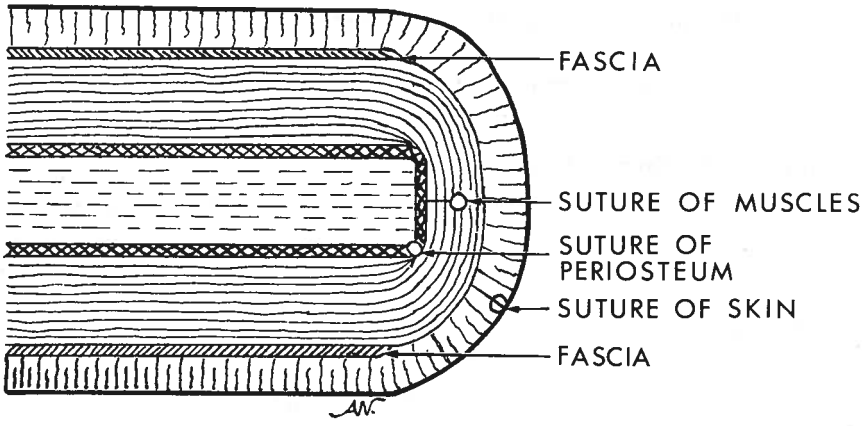

FIGURE 2. Diagram of the osteomyoplastic amputation.

of Paris. By this method the post-operative oedema is largely prevented and the pre-prosthetic period reduced.

This procedure may be performed without osteoplasty when a prolonged procedure is contra-indicated.

Choice of Procedure

The conventional operation generally offers satisfactory results. New investigations have, however, revealed that the trophic conditions may be improved by a more elaborate treatment of bone and muscles. Stump pain may be due to ischaemic scar formation, and a myoplastic stump revision has proved effective in relieving pain in a great number of cases.

The conical shape of the stump which is achieved by the conventional method was perfect for fitting with the traditional socket shape. Myoplasty offers a more bulky, square shape, and this shape is perfect for the modern total contact sockets. The most important advantages of myoplasty, however, are the improvement of the active muscle function in the stump and the preservation of muscular balance. This is most clearly demonstrated on the thigh where a simple division of the muscles creates serious loss of adductor and extensor power (adductors and hamstrings), whereas the hip flexor and abductors are not affected. Myoplasty should for these reasons be the operation of choice, especially for reamputation cases.

The conventional procedure may be preferable in risky cases with impaired vascular supply and in the upper extremity.

Open Amputation: When a regular amputation is contra-indicated because of an infection, a conventional amputation with but a few sutures in the fascia-skin flaps is recommended. The sutures may be placed but not tied until the acute crisis has been overcome.

Circular amputation (guillotine amputation) is applied to particular cases when infection or the patient's condition contra-indicates a regular procedure. This procedure should be combined with skin traction in order to reduce retraction of the skin. A secondary amputation is frequently necessary.

As previously mentioned traumatic cases may be encountered in which a regular surgical amputation would mean the loss of a joint, essential stump length, or any other important structure. In such cases the circular amputation may be the answer when skin grafts and secondary skin plasty permit local conservative reconstruction.

Post Operative Complications

Haematoma is an unfortunate complication interfering with the healing of the wound and the final quality of the scar. Careful haemostasis and maintenance of suction drainage for a sufficient period therefore deserve much attention as preventive measures. If a haematoma occurs it should be evacuated by puncture near the suture line. Attempts to remove the haematoma by pressure should not be made.

Wound infection is a particular risk when circulatory disturbances are present. Again prevention is better than cure.

When infection occurs one should not hesitate to remove stitches, making bacterial probes, and starting antibiotic treatment. To a greater extent gangrene is due to a too optimistic judgment of the circulation at the level of amputation. In pronounced cases an immediate reamputation at a more proximal level is indicated.

Minor necrotic changes of part of the wound must be treated conservatively, and secondary healing may be expected.

Gentle handling of the skin during surgery is of preventive value.

General and local measures for improving the circulatory and metabolic conditions should be considered in all vascular cases. It is wise to avoid skin grafting and particularly flap plasty in such cases.

TYPES OF AMPUTATION

LOWER EXTREMITY

In a lower limb amputation it is particularly important that the stump be robust and capable of tolerating the mechanical strain to which it is exposed during ambulation and weight bearing. The scar should therefore, when possible, be placed distally, and sharp, bony edges under the skin should be avoided.

Femur Amputation

1. *Level:*

   In order to give room for a prosthetic knee mechanism the amputation should be performed 4–6 inches above the knee joint. Above this level

797–386 O—66——2

the stump should be as long as the disorder or lesion permits. Even a short stump is preferable to a disarticulation of the hip.

2. *Flaps:*

   Curved incisions through skin and fascia on anterior and posterior sides of the femur.

   The ventral flap should be 2 inches longer and 1 inch broader than the dorsal flap. The total length of the flaps should exceed the cross diameter of femur on amputation site by 1 inch. (In myoplasty the flaps must be cut long enough and possibly adjusted before suture.)

   The flaps are dissected to their base. In myoplasty the fascia may be isolated and removed.

3. *Muscles:*

   a) When a myoplasty is being done the muscles are divided 2 inches distally to the division of the bone. After treatment of the bone the adductors and the vastus lateralis are joined by sutures and next the quadriceps and the hamstrings are united in a superficial layer. In myoplasty slight trimming of the muscle bulks may be indicated. The leg must be positioned without hip flexion during the procedure.

   b) In conventional amputations the muscles are cut transversely at the level of amputation.

4. *Bone:*

   a) In conventional amputations the periosteum is incised circularly and the femur sawn transversely.

   b) When an osteoplasty is intended the femur is dissected free of the amputation level and 3 inches distally. A pedicle flap is outlined in half the diameter, 2 inches long. This flap is prepared by chisel and the femur is now sawn transversely. The flap is turned down over the bone end and fixed by periosteal sutures.

5. The nerves are isolated, pulled gently distally 1 inch, and cleanly divided.
6. Careful haemostasis is carried out.
7. The tube for suction drainage is put in place.
8. Fascia and skin are closed by interrupted suture.
9. Compressive elastic bandage, which does not pull the hip joint into flexion is applied. The bandage pressure is gradually reduced proximally.

   (A plaster of Paris bandage may replace the elastic bandage.)
10. Correct positioning in bed (extended, adducted hip) is important.
11. Drainage tube is removed after 3–5 days.
12. Stitches are removed 12th–14th day.

Atypical above-knee amputations (e.g. Gritti Stokes) should be avoided as they offer no advantage but cause a high percentage of complications.

Hip Disarticulation

A complete description of this procedure is beyond the scope of this pamphlet.

The operation is performed by making a racket-shaped incision. The incision is made from the anterior superior spine, along the inguinal ligament, medially around the thigh (2 inches distally to the inferior ramus and 3 inches distally to the apex of the greater trochanter) and upwards to the anterior spine. In the anterior part of the incision the femoral vessels are isolated, ligated, and divided. The femoral nerve is transcised and the rectus and pectineus are divided.

With the leg abducted and rotated outwardly, the psoas, the adductors, and hamstrings are divided while the obturator artery is secured and ligated. With the leg rotated inwardly the fascia lata are divided distally to the tensor muscle and gluteus maximus. The glutei are then transcised and finally the small outward rotators. The sciatic nerve is cut, and the extremity is removed by incision of the hip joint capsula.

A good soft tissue cover is provided by this procedure, the skin flap, the glutei, and the tensor muscle being sutured medially, where the muscles may be fixed to the origins of the pectineus and adductors.

Hemipelvectomy

This procedure is a demanding one, and as it is most frequently performed in case of malignant tumors, it should be left to specialists. In this procedure also the principle is the provision of a good soft tissue flap with gluteus maximus and skin in one big dorsal flap. The incision is carried along the iliac crest and the inguinal ligament. When the abdominal muscles are moved medially the iliac fossa may be inspected and the tumor and its operability be evaluated. The iliac vessels are ligated. The pelvis is divided by saw anterior and lateral to the symphysis and posteriorly a little anteriorly to the sacroiliac joint, as the blood supply to the gluteus maximus should be saved.

Knee Disarticulation

This question has considerable value because the procedure is that of dividing a minimum of soft tissue, the stump permits direct weight bearing, and the triangular shape offers rotational stability. This level is a frequent possibility in vascular lesions.

Technique:

1. Anterior u-incision through skin and joint capsule passing 1 inch distally to the insertion of the inferior patellar ligament on the tibia. The upper angles of the incision are on a level with the femoral epicondyles.

The dorsal flap is shorter. In the anterior flap the patella is preserved.

2. The flaps are dissected free from underlying bone and muscles.
3. The joint capsule is divided near the tibia, and the cruciate ligaments are cut. The popliteal artery and vein are isolated, ligated, and divided. The tibial nerve is pulled down and cut. The hamstrings are divided distally. The patellar ligament is sutured to the rest of the cruciate ligaments, and the stumps of the gastrocnemius are also sutured to the cruciate ligaments. Finally the tendons of the hamstrings are fixed to the patellar ligament (Fig. 3).
4. The skin-fascia flaps are sutured after insertion of the drain tube. Synovectomy is not normally performed.

Amputation on the Tibia

Level of amputation:

An amputation stump of proper length, with a good soft tissue cover, and good blood supply is the goal.

Choice of the gastrocnemius muscle tendon junction is excellent, but also much shorter stumps are suitable for prosthetic fitting.

Conventional method:

1. Skin-fascia incisions provide anterior and posterior flaps. The anterior flap should be ½ inch longer than the leg diameter; the dorsal flap, one half of the diameter.
2. Transverse division of muscles is carried out ½ inch distally to the base of the flaps.
3. The tibia is sawn at the base of the skin flaps, but the anterior tibia-corner is removed by a saw cut from 1 inch proximally to ½ inch dorsally to the point of the corner. The sharp edges must be sanded off.

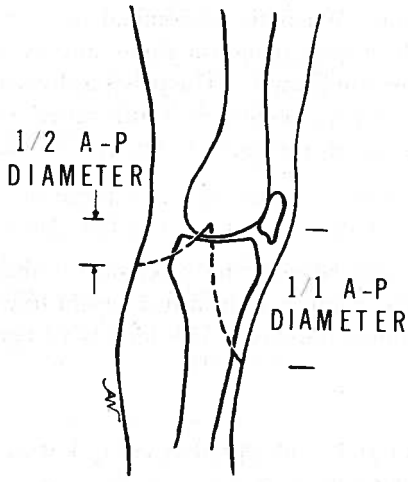

FIGURE 3

4. The fibula is divided 1 inch proximally to the tibia end. (In very short stumps it may be preferable to remove the fibula completely.)
5. Division of nerves is made cleanly.
6. Haemostasis is carried out.
7. Drainage is made in the wound corners or by suction tube.
8. Interrupted suture of fascia and skin is carried out.
9. Compression bandage is applied.
10. The amputee is positioned so that the knee is extended.
11. The drain tube is removed 3rd-5th day.
12. Sutures are removed 12th-14th day.

Osteomyoplastic Amputation

This procedure takes longer; it gives, however, a stump properly suited to prosthesis use, and eliminates the fitting problems due to dislocation of the fibula.

1. Equal long anterior and posterior skin flaps. The total length should exceed the cross diameter by 1 inch.
   The fascia is excised.
   The flaps should preferably be situated crosswise to the tibia-fibula axis.
2. The muscles are divided 1½ inches distal to the base of the skin flaps.
3. Tibia and fibula are dissected from about 2 inches distal to amputation level.
4. From the medial and lateral aspects of tibia osteoperiostal flaps are prepared with base slightly proximally to the level of amputation. The same procedure is performed on the fibula.
5. Tibia and fibula are sawn transversely on the same level, and the anterior corner of tibia is removed as described above.
6. The nerves are isolated and divided.
7. Haemostasis is carried out.
8. The osteoperiostal flaps are united, the lateral tibial and medial fibular flaps first, then the medial tibial and lateral fibular flaps. By this procedure a tibio-fibular bridge is created. The bridge closes the bone cavities, it serves as a pulley for the myoplasty, and later it forms a tibio-fibular synostosis.
9. The anterior muscles are sutured to the dorsal and peroneal groups. It may occasionally be necessary to excise the soleus muscle belly if it is too bulky.
10. The skin is closed.
11. The stump is bandaged for 8 weeks. Plaster of Paris bandage affords the best protection. It may be changed to an unpadded bandage, when the sutures have been removed two weeks after the amputation.

Distal Amputations on the Lower Extremity

This level is of particular interest in traumatic and diabetic cases.

Amputatio Digiti

Is usually performed as a disarticulation in the proximal interphalangeal joint or the metatarso-phalangeal joint. Amputation of first or second toes should be done only when vitally necessary.

Technique:

Skin incision with a plantar flap which is sufficiently large to cover the capitulum. In the metatarso-phalangeal joint a racket-shaped incision with the apex dorsally may be applied. The tendons are divided, and so are the nerves.

Drainage may be omitted when the haemostasis is carefully done.

Amputatio Transmetatarsea

This procedure is frequently used in diabetics with gangrene in the forefoot. Its advantage is the preservation of a functional foot which may need orthopaedic footwear but no real prosthesis.

Technique:

A dorsal transverse incision is made through skin, fascia, and tendons about 1 inch proximally to the metatarso-phalangeal joints.

The plantar incision is made at the proximal toe flexion crease. The plantar flap, which includes the short toe flexors, is dissected to the level of the dorsal incision.

The metatarsals are sawn a little distally to the dorsal incision and in a regular medial-lateral curve.

Suture of fascia and skin.

Lisfranc's, Chopart's, and *Pirogoff's* amputating are rarely used.

The amputation in the Chopart joint may be performed when a balance between dorsi and plantar flexors can be achieved. This balance may be provided by a subastragalar anterior shift of the calcaneum, reducing the force of the triceps and a solid anchoring of the tibialis anterior to the anterior side of the calcaneum.

Amputatio Intercalcaneo-Tibiale

1. Skin incision with a small dorsal and a large plantar flap. The incision begins ½ inch under the medial malleolus, it is continued across the dorsum of the foot corresponding to the talo-navicular joint and in a curve towards the apex of the lateral malleolus. From here it is curved anteriorly across the plantar aspect near the metatarsal heads and back to the medial malleolus (Fig. 4).
2. The ligaments between tibia, talus, and calcaneus are divided, and the talus is excised.
   Lesion of the retromalleolar vessels should be avoided.
3. The calcaneus is sawn ½ inch behind the Chopart joint, and the foot may now be removed.

4. The cartilage on tibia and calcaneus is removed.
5. The calcaneus is shifted forwards, adapted to tibia and fixed by a Steinmann nail from the planta.
6. The medial and lateral plantar nerves are isolated and divided.
7. Skin edges are trimmed and sutured (Fig. 5).
8. A suction tube is inserted.
9. Stitches may be removed 2 weeks post-operatively; the nail is removed 4 weeks post-operatively.
10. A plaster bandage for walking is applied until solid bony union has been obtained.

Syme's Amputation

Principle:

Amputation is carried out on the tibia immediately above the ankle joint and is covered with skin and tissues from the heel. A stump tolerating direct weight bearing should be achieved (Fig. 6).

Technique:

1. Skin incision is made between the apex of the malleoli anteriorly to the ankle joint. The incision is continued in a U-shape through the planta anteriorly to the heel pad.
2. The soft tissue is dissected close to the bony structure.

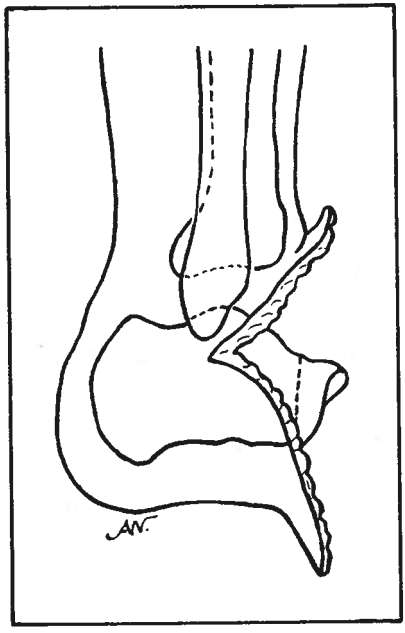

FIGURE 4

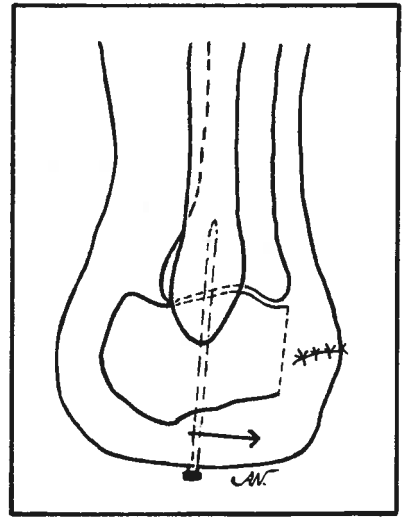

FIGURE 5

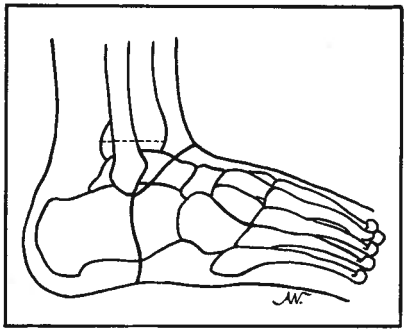

FIGURE 6

3. The ankle joint is opened anteriorly and the collateral ligaments are divided from the joint cavity distally and plantarwards.
4. The foot is extremely plantar-flexed, and now the talus and next the calcaneus are dissected free, a hook being applied first in the talus and next in calcaneus to expose the area for dissection.
   NB: Avoid lesion of the retromalleolar vessels.
5. The dorsal and plantar arteries are ligated near the skin edges, and the plantar nerves are isolated and divided above the ankle level.
6. The malleoli and distal end of tibia are freed and sawn ⅜ of an inch above the joint level.
7. The skin-fascia flaps are sutured. Although trimming of the skin edges is tempting, this should be omitted as the vascular supply is the critical point of the procedure.
8. Suction drainage is applied.
9. The heel skin is fixed to the bone end by 2–3 metal pins.
10. Bandage is applied for 4–5 weeks.

NB: The described amputation types which permit direct weight bearing and for which a prosthesis is not an absolute necessity are of particular value in areas where prosthetic services are not easily available.

AMPUTATIONS ON THE UPPER EXTREMITY

Forequarter Amputation

Amputatio inter-thoraco-scapularis is best performed in specialized centers, when the indication is malignant growth. The centralization is justified also because of the particular fitting problems. In traumatic lesions the procedure is determined by the type of injury, and muscle and skin cover must be provided according to the possibilities.

Amputatio Humeri

Level:

As long a stump as possible is sought, the level depending solely on the pathological condition. Even an extremely short stump (the humeral head) is preferable to a shoulder disarticulation.

Technique:

1. Equal long, curved anterior and dorsal skin-fascia flaps, a good half the diameter of the arm.
2. The muscles are divided at the level of the base of the flaps.
3. The humerus is sawn at the same level.
4. The median, ulnar, and radial nerves are divided 1 inch proximal to the amputation level.
5. Haemostasis is carried out.
6. A few sutures connect flexors and extensors.
7. Interrupted suture of fascia and skin is used.
8. Suction drainage is used.
9. Elastic compression bandage is applied.

Exarticulatio Cubiti

Disarticulation of the elbow is an amputation which offers a good basis for prosthesis use; in particular it provides an excellent stability and control of the prosthesis.

Technique:

1. Equal anterior and dorsal skin-fascia flaps are made.
2. Dissection of the biceps and triceps tendons, division of brachioradialis and brachialis, excision of the extensor and flexor heads at the epicondyli.
3. Transcision of the joint capsule anteriorly and dorsally and of the collateral ligaments.
4. Dissection and division of the nerves.
5. Haemostasis.
6. Suture of triceps and biceps tendons.
7. Suture of fascia and skin.
8. Suction drainage.
9. Elastic bandage.

Amputatio Antebrachii

Level:

Level should be as low as possible; wrist disarticulation also is acceptable. With very short stumps, division of the biceps tendon may facilitate fitting of the prosthesis.

Technique:

1. Equal, curved anterior and posterior skin-fascia flaps.
2. Division of muscles a little distally to the flap base.
3. Radius and ulna are sawn transversely at the same level, a little distally to the base of the skin flaps.
4. Median, ulnar, and radial nerves are isolated and divided 1 inch proximal to amputation level.
5. Haemostasis.

6. Suture of flexors to extensors (osteoplasty is not performed).
7. Suture of fascia and skin.
8. Suction drainage.
9. Elastic compression bandage.

Krukenberg's Operation

In the case of blind patients much thought should be given before amputating the upper limbs. In this group of disabled, which is not uncommon as a result of war casualties, the Krukenberg operation is preferable to prosthetic fitting with below-elbow amputees. The Krukenberg operation, which consists of a phalangization of radius and ulna, should be performed in specialized centers. Through this procedure a stump with grasping capacity and preserved sensation is achieved. It may be supplied with prosthetic appliances for social purposes.

Cineplasty

With below-elbow amputees the biceps muscle may be utilized advantageously as a motor operating the prosthetic hand. The principle of this procedure is a release of the biceps from its insertion and creation of a skin-lined tunnel through the distal part of the muscle belly. This procedure should only be used where specialized services are available as the after-care and the prosthetic fitting are particularly demanding.

Wrist disarticulation, transcarpal amputation and *amputation of the metacarpals* are usually dictated by the limit of a traumatic lesion, and surgical care must be influenced by practical possibilities. Therefore, no strict rules should be given. It must be remembered that:

a) any level is acceptable,
b) a solid scar is desirable, preferably distal or dorso-distal,
c) the nerves should be dissected and resected 1 inch proximally to the scar,
d) preliminary skin cover by skin grafts may permit secondary repair,
e) extensive lesions may indicate more radical amputations,
f) possibilities for secondary phalangization or reconstructions should be taken into consideration.

Amputations on the Fingers

Level of amputation is indicated by the site of the lesion. It is important that sensibility be preserved in the stump established and that the proximal joints be movable or at least be placed in a position suitable for hand function.

Disarticulation is not preferable to regular amputation unless the cause of the amputation is infection.

In the planning of amputation the patient's occupation should be considered. To a laborer doing heavy work the basic phalanx (and the metacarpal) are of value whereas a patient doing fine handwork or working

as a representative may be better off with a complete removal of the finger. This does not, of course, apply to the thumb. Removal of the metacarpal head should, when possible, be avoided as it reduces the stability of the hand considerably.

Technique:

1. Volar skin flap aiming at a dorso-distal scar. The skin edges must be carefully adapted.
   For disarticulation in the metacarpo-phalangeal joint a racket-shaped incision with the point dorsally is preferred.
2. The two volar nerves are dissected and divided ½ inch proximally to the amputation.
3. The flexor tendon is pulled distally and divided. The flexor and extensor tendons should never be united as this procedure locks the function of the other fingers as well.
4. Careful haemostasis makes drainage unnecessary.
5. Skin closure is made with a monofilament nylon.

AFTER-CARE

The post-operative treatment is of decisive importance for achieving a good result in the shortest possible time. This treatment should be started immediately after surgery, and it is supplemented with performance training when the prosthesis has been assembled.

I. Stump Care

a) *Bandage:*

The purposes of bandaging are: 1) prevention or removal of the post-operative oedema of the stump; 2) maintenance of the blood circulation (backflow).

On the operating table the surgeon applies an elastic dressing, which exerts a moderate pressure, most tightly at the stump end. When the wound permits, a regular stump bandage is applied with an elastic crepe band (Fig. 7). This bandage is applied with maximal pressure at the distal end. Constricting turns and tight turns which cause malposition of joints should be prevented.

Bandaging must be continued for a long time, also after the prosthesis has been delivered, in periods when the prosthesis is not used.

For below-knee stumps special elastic socks are practical for home use. In cases where osteomyoplasty has been performed a plaster of Paris bandage is used for the first post-operative weeks. This bandage type, which like other rigid bandages is effective in oedema prevention, deserves more general use. The risks of rigid bandage must, however, still be kept in mind.

b) *Contracture prevention and treatment:*
Contractures may develop rapidly after amputation. Correct posture of the limb is therefore essential. No pillow is allowed under the thigh or the knee.

c) *Stump exercises* aim at preserving the free movements of the joints involved and at improving the power of the stump to make it fit for later function.

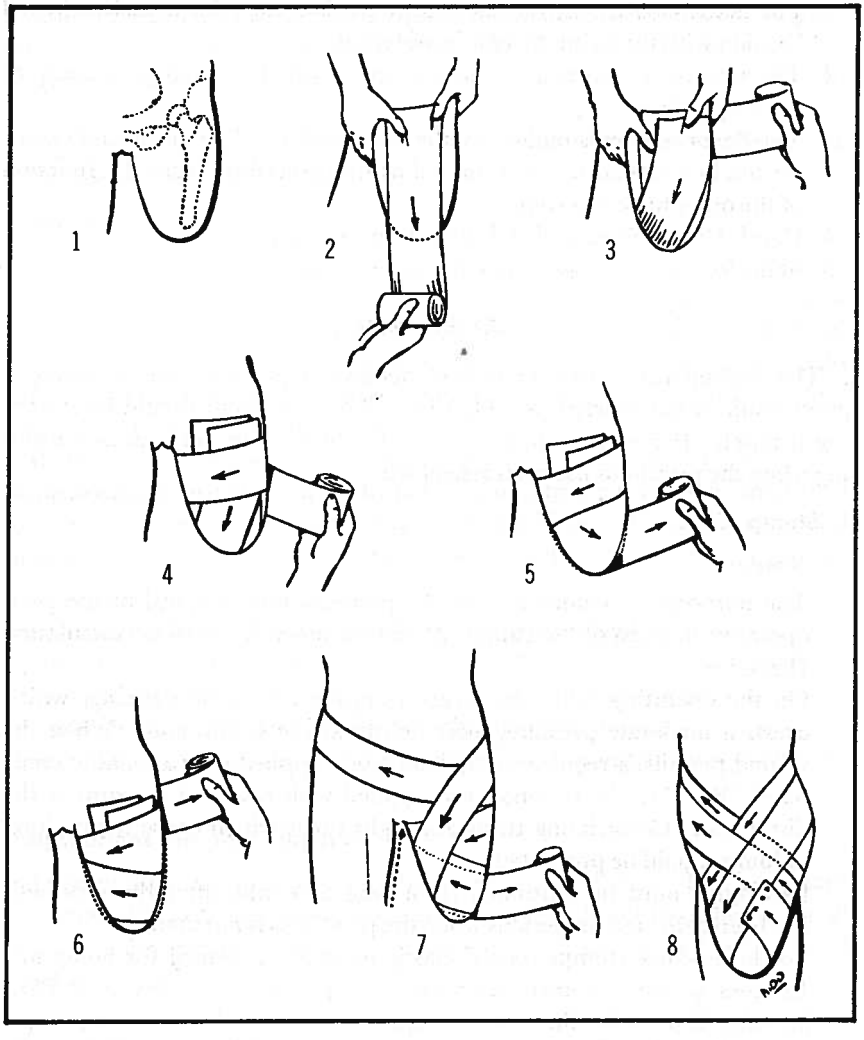

FIGURE 7. Stump-bandaging according to the principles of Mr. A. W. J. Craft.

d) *Passive exercises:*

May be commenced shortly after surgery. The exercises are mainly directed against the joint restrictions which by experience most frequently occur. In the above-knee amputee the complete extension of the hip is forced with the patient in a prone position.

e) *Active exercises:*

May be performed most effectively after removal of the stitches, and they are combined with passive treatment.

Active exercises are performed with graded increased resistance. Simple apparatus of slings, pulleys, and sand bags are adequate for training of all the important muscle groups.

II. General Conditioning

Gait with a prosthesis is physically demanding. It is important that the general physical state be improved by early gymnastics adapted to the capacity and limitations of the individual patient. The unilateral leg amputee may start early his standing and walking exercises with arm crutches. When a pool is available swimming, possibly with attached rubber fins, offers excellent physical and diversional rehabilitation opportunities.

III. Occupational Therapy

Functional training at adapted tasks and possibly with adapted tools and equipment is essential for the upper-limb amputee. Also the leg amputee may benefit physically and psychically from such treatment. Temporary prostheses for upper and lower limbs permit early function or ambulation.

Psychological treatment is of great importance in the pre-prosthetic period. This should include some guidance as to the vocational future of the amputee. The skilled occupational therapist and physiotherapist may contribute significantly to this end including analysis and evaluation of the patient's capacities and problems.

LOWER LIMB PROSTHESES

In the post-operative period the stump may be activated and function resumed by application of a provisional type of prosthesis. This may consist of an adjustable cuff (leather or plastic) which is tightened on to the stump in certain training hours.

The lower limb cuff may by extension permit some weight bearing and particularly management of pedals on a static bicycle, a loom, etc. The cuff for the arm may permit the attaching of a hammer, pencil, etc., for regaining the "functional consciousness" of the limb. Otherwise use of temporary prostheses is considered obsolete.

Prescription of Prosthesis

Prescription should be made when the scar is solid and the oedema has subsided—on an average 4–8 weeks post-operatively.

The surgeon must acquire a certain knowledge of the principle of prosthetics, the available component parts and their characteristics. On such background he is in a position to make his prescription with attention to the patient's particular possibilities and demands and to the influence of possible additional handicaps.

The prescription must be made in consultation with the prosthetist because he may suggest adequate technical solutions and possibilities. Also the physiotherapist and the occupational therapist and possibly the social adviser (or vocational counsellor) should attend the session as they may have obtained a more intimate knowledge of the patient's desires, problems, and vocational aspects in the pre-prosthetic period.

The selection of the type of prosthesis must depend on the patient's overall situation, physical and intellectual status, and vocational future. When the patient is trained with the roughly assembled prosthesis the possibilities are open for correction of fitting and alignment for optional performance and for revision of the original choice of appliance. In the case of arm amputees it may be wise to postpone the first prescription of terminal devices utilizing the experience during the pre-vocational rehabilitation.

The phases following the prescription are:

—the fitting of a socket to the stump,
—assembly of the prosthesis,
—preliminary training, during this period alignment and adjustment of the limb and of the cable and suspension apparatus are performed,
—preliminary check out,
—finish of the prosthesis,
—possibly final training;
—final check out.

These procedures apply mainly to the supply of the first prosthesis. In subsequent fittings the experience gained from the first prosthesis is utilized.

Above-Knee Prosthesis

The femur prosthesis consists of a femoral socket, a knee device, a shank, and an ankle and foot piece.

The socket may be made from light wood, metal, leather, or plastic material.

The body weight is transferred to the prosthesis by the socket, and a proper shape is therefore essential for comfort and stability. The ischial tuberosity is the only region which permanently tolerates the necessary

load. It is therefore essential that the socket brim has a shape which offers a stable seat for the tuberosity (Fig. 8). The brim is shaped like a seat for the ischial tuberosity, and the anterior-posterior diameter is so short that the bone is prevented from sliding down. Furthermore, the anterior wall is made high, smooth, and shaped for the trigonum scarpae to exert a tolerable counter-pressure.

Excavations are prepared and shaped for the greater trochanter and the bulks of the proximal muscle groups (glutaeus maximus, quadriceps, adductors).

The medial brim is low as the perinaeum will tolerate no load. Pressure here causes pain and consequently abducted limping gait.

During the stance phase the trunk is held in balance by a torque action (Fig. 9). The body weight is transmitted through the socket, the stump exerts a pressure towards the lateral distal part of the socket wall, and a counter pressure is exerted medially below the perineal brim. In order to achieve maximal stability it is obvious that the stump should be as long as possible, the lateral wall should be smooth and snugly fitted, and it should slope slightly into adduction.

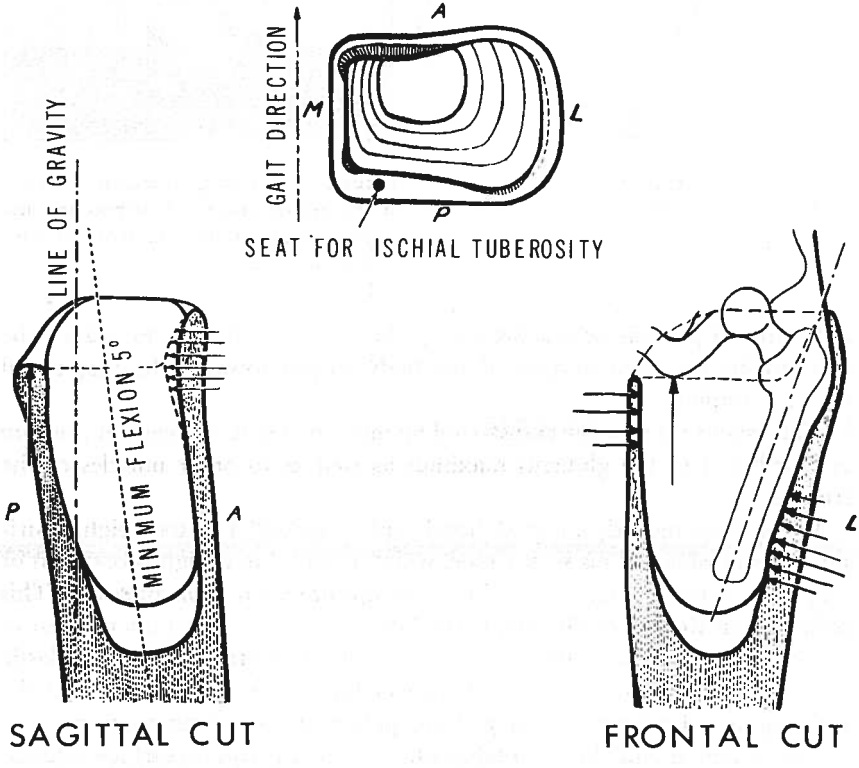

FIGURE 8

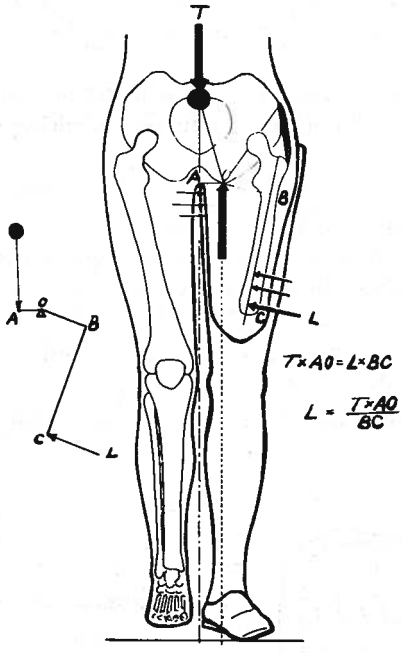

FIGURE 9

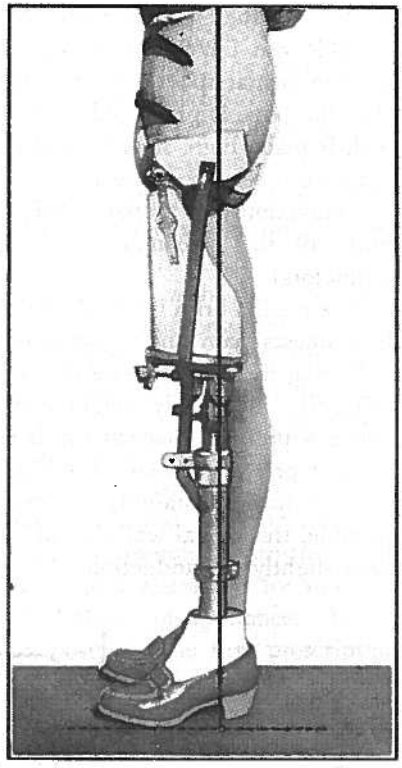

FIGURE 10. Hemipelvectomy prosthesis at testing stage. A temporary and adjustable apparatus is used as lower leg (adjustable leg).

Owing to poor fit or a short stump the patient will tend to reduce the pressure by exaggerated shift of the body weight towards the amputated side, i.e. limping.

The weight is not solely transferred by the ischial seat as a certain pressure is distributed to the glutaeus maximus as well as to other muscles of the stump.

In the more recently adopted "total contact socket" a better weight distribution is possible. This socket type, which is useful to a high proportion of amputees, is particularly applicable to stumps prepared by myoplasty. This socket is not worked out by measurements alone, but is based upon a cast of the stump. This cast is built on a type of adjustable frame made of plastic or metal. The frame, forming the upper brim, is fixed to a pole and the molding may therefore be done with the patient in a standing position.

The socket should be in total contact with the stump surface and no airspace is permitted in the bottom of the socket. Apart from the improved

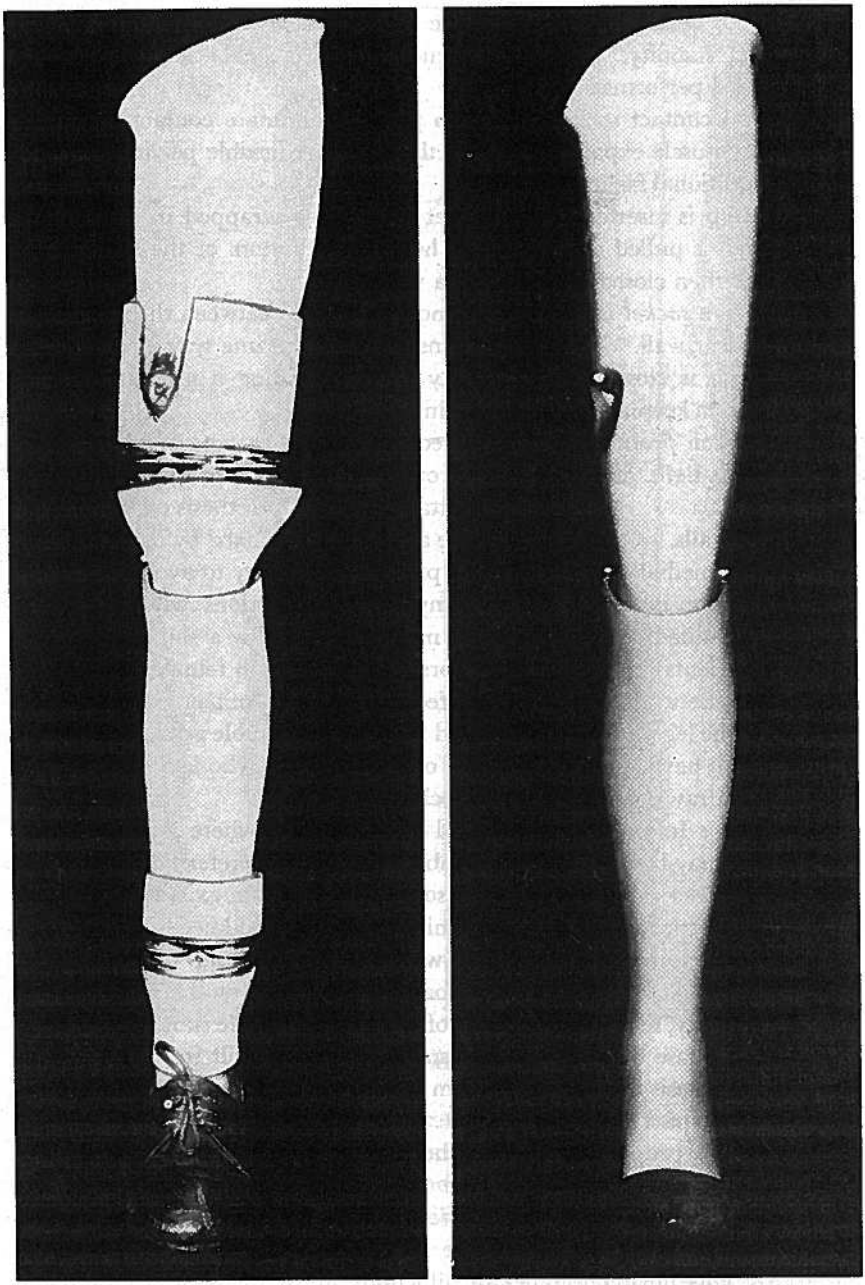

FIGURE 11. Total contact prosthesis at testing stage and finished.

principle for transfer of pressure, the total contact socket offers a perfect operational stability. The less "pseudarthrosis," the better the security, comfort, and performance.

The total contact socket is held in place by intimate contact, adhesion, and by the muscle expansion against the wall. A flexible pelvic band may offer an additional feeling of security.

The stump is inserted in the socket after being wrapped in a sock or a band, which is pulled out through a hole in the bottom of the socket wall. The hole is then closed by a cork or a valve.

The suction socket is built with a moderate space between the stump end and the socket wall. The stump is inserted in the same way as the above. The opening is closed by a two-way valve providing a graded vacuum, which assists in keeping the prosthesis in place.

A suspension prothesis is constructed with the same type of socket brim. The fit is less tight, and the socket is open below. The prothesis is held in place by a harness system, which is attached to the prosthesis on the medial and lateral walls. On the lateral side a strap may be fixed by a screw to the wall; on the medial side a strap may pass a small pulley to avoid restriction of flexion-extension movements. Any rigid connections with the trunk should be avoided. The suspension may be secured by a shoulder harness (in male patients) or an adequate corset (preferably in females).

This prosthetic system is less perfect as regards contact, stability, and rotation of the leg. It may be reserved for the considerable group of geriatric patients, who have changing oedema of the stump or who lack the strength necessary to draw on a tightly fitted socket.

Knee joint: In young patients and in other cases where a true gait rehabilitation may be expected, a movable knee joint is preferred. A variety of artificial knee joints is available, some with a single axis action, others with a polycentric movement more similar to the natural knee function.

Some knee joints are equipped with a brake system, mechanical or hydraulic. Braking is achieved by load on the knee (or the foot), and it provides stability, in the stance phase of walking and while standing.

A "swing phase control" mechanism may also be built in. This system gives the prosthesis the normal rhythm of movement, in particular deceleration in the final part of the swing phase.

Essential for proper function of the knee and of the total prosthesis is proper alignment. Decisive for the knee stability is the position of the femoral socket with respect to the foot. The knee axis must be placed slightly posteriorly to the gravity line (Fig. 12). If it is placed too much posteriorly, knee flexion becomes too difficult.

The thigh must be placed in such a way that extension is possible when the amputee is in an upright position.

Normally the thigh piece is placed at 5 deg. of flexion when the knee is fully extended. Whenever a hip flexion contracture is present, the degree

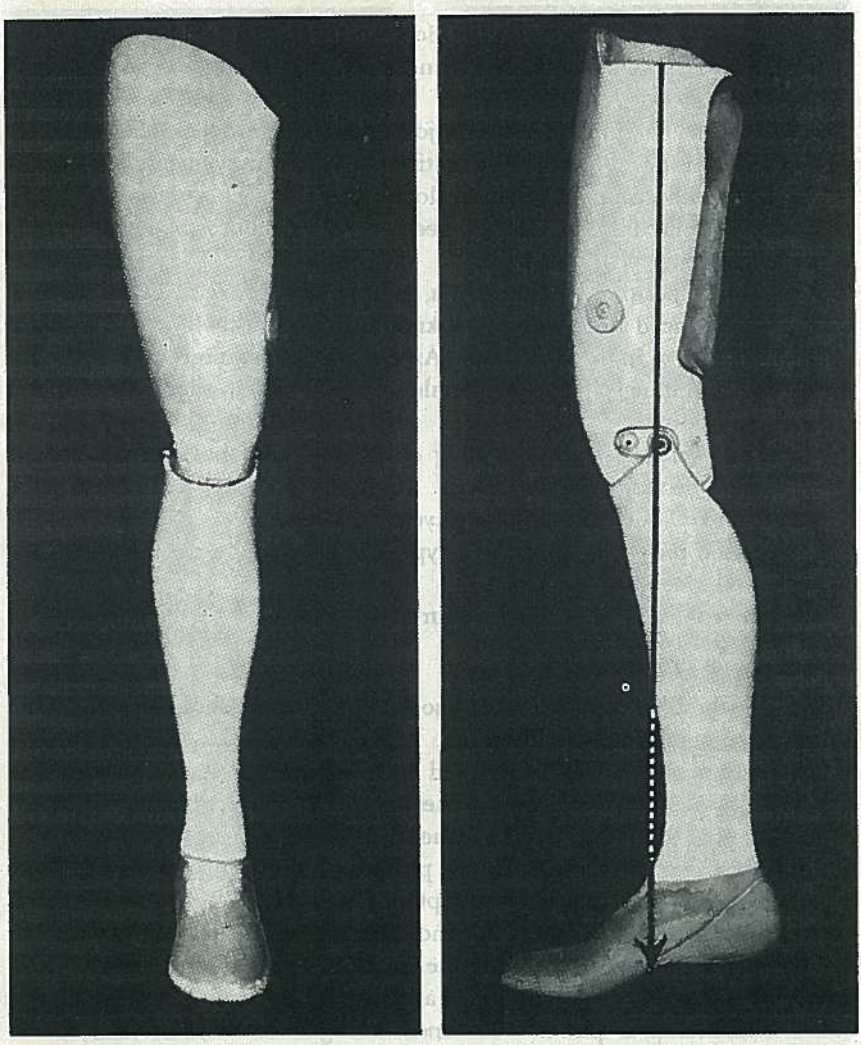

FIGURE 12

of this contracture is added, and the thigh piece must correspondingly be shifted forward to achieve proper alignment. A knee joint with a releasable lock is preferred in weak patients and when other conditions, e.g. lack of balance, indicate need for more stability. When the patient is sitting, he may unlock the knee. The stiff knee is a hindrance to "normal gait," and it is more traumatizing to the stump. Proper attention must, therefore, be given to the choice and possibily no decision taken until after preliminary gait training.

In some cases it may be a question whether an old or weak patient should be supplied with a prosthesis and subjected to the strain involved. Although

the patient may enjoy the benefit of doubt, it is in general a reasonable criterion that the patient be able to stand and to walk on the good leg with two arm crutches.

Ankle joint: The prosthetic ankle joint may be a simple hinge joint or a polyaxial joint permitting also rotation and side movements. The last function is of importance in gait on sloping surfaces (e.g. sidewalks). The SACH foot (*s*olid *a*nkle, *c*ushioned *h*eel) is a durable prosthetic foot which to some degree meets the demands.

The correct position of the foot is, as mentioned, decisive for the gait. By too pronounced dorsiflexion the knee becomes unstable as the forefoot acts as a lever arm in this function. An exaggerated equinus makes the gait difficult and limping. The foot should be positioned in slight equinus and outward rotation.

In old or weak patients mounting of the foot may be achieved with a pylon. This necessitates a knee lock. The pylon is easy to manage for a little "get about" but no real walking cycle is achieved.

For specific purposes, specialized types of feet may be desirable, e.g. for work in mud, ricefields, etc.

A plastic coated foot and shin or simplified item may be the choice.

Below-Knee Prosthesis

The prosthesis consists of a stump socket fitted into a shin piece and most frequently mounted on a SACH foot.

Application of a thigh corset used to be the rule. As this corset was attached by sidebars and hinges to the shin, considerable weight was taken by the corset. On the other hand, the discrepancy between the hinge joint and the knee joint was a troublesome problem. In recent years a new type of prosthesis has been universally adopted, called the PTB prosthesis (*p*atellar *t*endon *b*earing). As the name indicates the weight is transferred from the patellar ligament (and from the anterior areas of the tibia). The prosthesis is made from a plaster cast and usually fabricated in plastic laminate. The stump is placed with knee in slight flexion, and a dynamic alignment in a trial training period is essential. The prosthesis is suspended by a transverse leather strap which passes above the knee cap. Another prosthesis which is of French design (PTS = *p*rothese *t*ibiale *s*upracondylaire) encases the patella in the plastic laminate. This type has advantages cosmetically but it is particularly suitable to short stumps. Prosthesis for other types of leg amputations are not explained in this pamphlet. For the hip disarticulation and hemipelvectomy a Canadian type has been of great benefit. The pelvis and lower part of the trunk is encased in a partly rigid, partly flexible plastic corset. The hip hinge is placed anteriorly and the knee hinge posteriorly; this principle permits an acceptable ratio stability-performance.

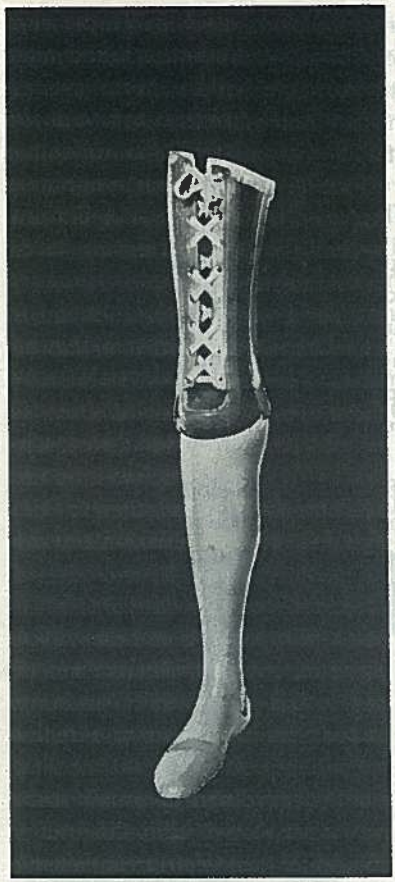

FIGURE 13. Knee disarticulation prosthesis.

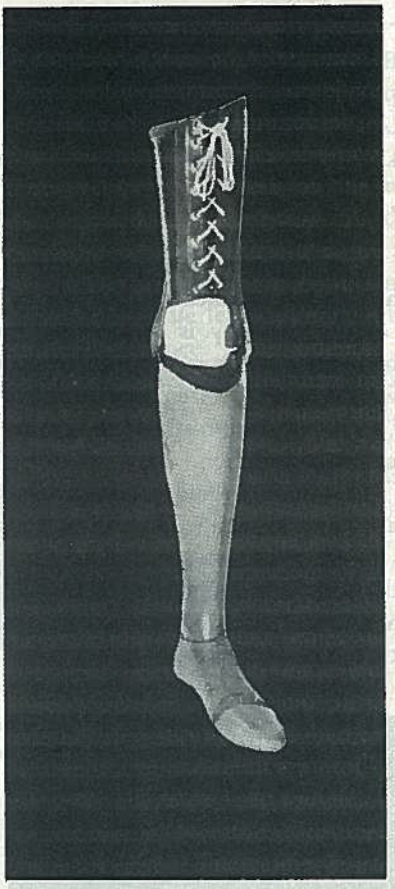

FIGURE 14. Conventional below-knee prosthesis.

The knee disarticulation prosthesis is usually made from a leather socket with a pad in the bottom and laces in front. It is connected with shin and foot by sidebars and hinges.

For distal amputations various designs have been suggested. The problem of the Syme prosthesis is the bulky stump end. This problem may be solved by a plastic shin with prosthetic foot. On the side of the shin a window permits the passage of the stump down to the bottom.

Prostheses for Double Leg Amputees

The bilateral amputee presents particular and difficult problems as to prescription and training. A bilateral above-knee amputee should usually have a knee lock on one side, and this should be the side with the longer and more resistant stump.

The prosthetic training should be started with the sockets mounted on the prosthetic feet. Later, when balance and performance improve, the prostheses are elongated stepwise by 4 inch increments. The final height of the patient is usually 3–4 inches less than the pre-operative height. The knee joints may now be inserted and the final alignment performed.

ARM PROSTHESES

The capacity of a prosthesis to compensate for the loss of an arm is at present significantly inferior to that of the leg prosthesis. The loss of sensory capacity is of decisive importance. Skilled work and effort is demanded to have the patient accept the insufficiency of the replacement we are able to offer, and in our prescription we must consider which capacities of the prosthesis should be favored: cosmesis, specific light weight, or heavy function.

The above-elbow prosthesis consists of a socket, an elbow joint, a forearm, and an artificial hand or hook. The socket may be fitted in different ways; most practically the socket is shaped to fit the stump and to include the acromion to which the lifting load is transferred. By this method the additional harness may serve solely for operation of elbow flexion and the terminal device (Fig. 16).

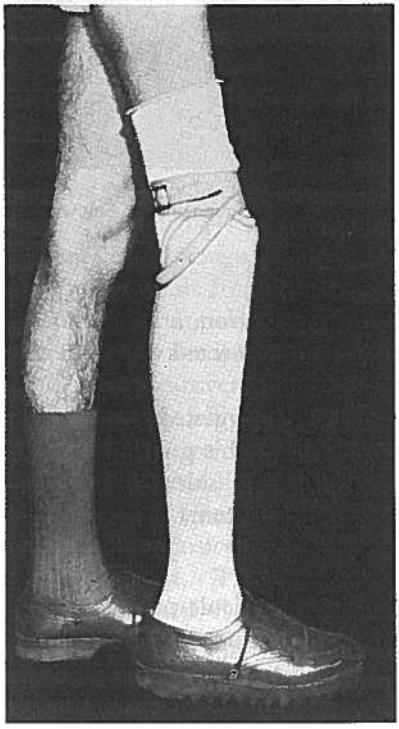

FIGURE 15. Modern below-knee prosthesis.

The elbow joint contains a passively operated turntable and a cable-controlled hinge joint which is most frequently equipped with a device permitting locking in various degrees of flexion. The forearm piece is closed by a disk to which the hand or hook may be connected and easily exchanged. Passive rotation of the terminal device is possible.

The below-elbow prosthesis consists of a socket, which is held in position by straps above the elbow or it may be shaped to fit like a shoe around the epicondyles and olecranon. The latter design is thus self-suspending; in return this socket permits rotation only by a special double wall system with a distal rotation unit. A forearm stump of middle length or shorter possesses, however, no rotary function of any importance.

The artificial hand may be purely cosmetic. However, prosthetic hands are available which combine function with cosmetic effect, e.g., the APRL hand (*A*rmy *P*rosthetics *R*esearch *L*aboratory, Washington, D.C.).

For most occupations some type of split hook is necessary. The split hook is composed of two curved branches (of various designs and dimensions)

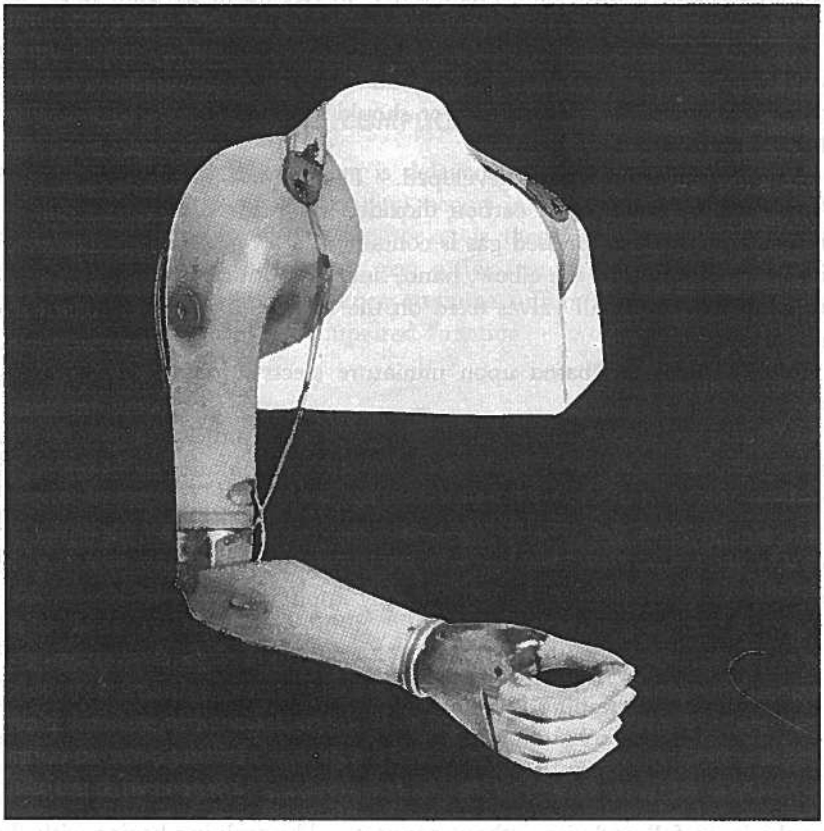

FIGURE 16

which are closed by a spring action, while a cable control system provides for opening (the inverse principle is also used). Specialized terminal devices may be prescribed for a particular function, e.g., fine forceps or screwdriver, appliance for car driving, etc. These devices may all fit into the prosthetic disconnection disk. The active elbow flexion and elbow locking and the operation of the terminal device are made possible by a shoulder harness with attached Bowden cables. The principle is selective use of the different movements of the shoulder girdle, which makes three independent operations possible.

Careful fitting, training, and adjustment are essential for proper function.

The Bilateral Arm Amputee

Prosthetic service to the bilateral amputee is obviously a most important task and most demanding, particularly in above-elbow amputations.

It is important because it converts a helpless disabled person into an independent and possibly employable citizen.

It is difficult because the patient lacks the assisting hand for mounting the prostheses and because the shoulder harness must serve two prostheses.

In such cases certain functions are imperative. At least one prosthetic hand must be able to reach the mouth and any part of the body. In centres, where it is available, external power should be considered for the benefit of the bilateral arm amputee.

Several systems have been developed. The Heidelberg prosthesis, which is powered by compressed carbon dioxide, has reached a high degree of perfection. The compressed gas is contained in a metal bottle and it provides for operation of the elbow, hand, and wrist rotation. The functions are controlled by small valves fixed on the muscles of the shoulder girdle and the upper arm.

Other systems are based upon miniature electric motors fed by small batteries.

The application of external power may also be considered in unilateral cases, which are particularly high (forequarter amputation) or combined with extensive paralysis.

The development of artificial arms, externally powered and controlled by EMG signals from muscles in the amputation stump is going on—and some day such devices may be universally applicable.

PROSTHETIC TRAINING

Instruction and training in use of the prosthesis is obviously of decisive importance for the rehabilitation of the amputee. For the leg amputee the training should include balance and walking exercises, climbing stairs, and walking on sloping surfaces. The patient must be able to apply the prosthesis, to fall and rise without support. The training begins with the

parallel bars, next by arm crutches, and finally the younger amputee may manage with one cane or perhaps even without a cane.

The weaker amputee may not achieve the same results, and sometimes it may become clear during the training that the wheelchair is the proper means for transportation. The prosthesis may even in such cases offer a useful service when the amputee is getting around in the home.

The arm amputee also benefits significantly from physiotherapy, in particular, regarding the mobilization and training of the shoulder girdle function. The main emphasis is, however, placed on the occupational therapy training, the activities of daily living and pre-vocational training. During the training several problems may appear, and the patient may be supplied with specific technical aids. The training period is also used for analysis and adjustment of the prosthesis. When the training is completed, the performance should be evaluated by the team, and the prosthesis checked as to fit, stability, comfort, and function.

The final approval of the prosthesis should not be a general judgment. The result must be evaluated by a systematic and critical analysis of the prosthesis and of the patient's performance with the prosthesis, due consideration being given to the opinion of the amputee.

LATE COMPLICATIONS

Although the prosthetic fitting is delayed until the oedema has disappeared, a further atrophy (muscular) occurs in the following months. A follow up and adjustment of the socket is therefore necessary. If this measure is neglected the patient may suffer from all the troubles which follow a poor fit. The above-knee amputee suffers from pressure in the perinaeum, skin lesions, and impaired function.

Stump Pain

It is a normal occurrence that the patient, after the amputation, has preserved perception of the removed limb (phantom sensation). Gradually the phantom diminishes, and at last it fades away. In some cases the phantom image, however, is more persistent and it may become the site of pain, sometimes an intense, sleep disturbing pain.

The pathophysiological mechanism of phantom pain is probably a peripheral stimulus from the stump and a central perception and response, the latter becoming increasingly important in time and possibly closely related to the personality of the individual.

The peripheral stimulus is explained by the existence of a painful neuroma and ischaemic scar formation.

Although the central factors may be the major factor in patients of the vegetative neurotic type, it is worthwhile to concentrate on the peripheral problem.



FIGURE 17. Vocational training of double arm amputee provided with two temporary, adjustable prostheses.

It is a common experience that the steady course of amputee treatment, early fitting and training together with early settling of accompanying social and economical problems tend to reduce the problem.

Some patients describe their phantom pain as being due to a feeling of such things as a tight fist of the missing hand, or forced dorsi or plantarflexion of the removed foot.

Physiotherapy including selected mobilizing exercises of the spared and of the missing limb may unlock the phantom and yield relief. Encouraging results have been obtained by myoplastic revision of the stump.

Neuromas

The formation of neuromas on the divided nerves is a normal occurrence following amputation; these neuromas may be of various sizes. In some cases the neuroma may become hypersensitive, and this makes the prosthetic fitting impossible. This hypersensitivity and soreness may be of varying degrees.

Conservative treatment with vibration has been recommended. Ultrasonic treatment has in many cases had an excellent relieving effect.

The neuroma may be removed by surgery, cutting the nerve more proximally. Recurrences are, however, not rare.

In some cases it may be possible to dislocate the nerve and place the nerve end in an area which is not subject to pressure. Some prefer to bury the nerve end in a hole drilled in the bone.

Recurrence may frequently be prevented by sheathing the nerve end in a polythene film tube. This tube is a few inches long, the proximal end is fixed round the nerve, the distal end is tied as in a sack distally to the nerve.

Circulatory Disturbances

Both local and general circulatory disturbances may cause stump problems. Local oedema, cyanosis, and pigmentation are most frequently due to strangulation by the prosthesis. An altered fit of the prosthesis is indicated.

Ischaemic changes with pain and ulceration may indicate reamputation. In some cases with a pronounced angiospastic factor, sympathectomy or vasodilatory drugs may be beneficial. The same treatment may be useful in case of pronounced pernio. As the coolness is mainly due to lack of muscle function this problem is less pronounced in myoplasties.

Some elderly patients suffer from cardiac insufficiency. This may cause changing oedema of the stump with subsequent prosthetic problems. Adequate medication with diuretics may have an excellent effect. A general proper medical management is of course essential.

Bone Spurs

Formation of an exostosis at the bone end may cause pain and fitting problems. Even a tiny bone spur may give a tumor-like appearance. Radiological diagnosis and surgical revision are indicated.

In children overgrowth of bone is a frequent experience. In particular the tibial bone end grows long and pointed, and this exostosis is covered by a bursa. Surgical revision is indicated and must perhaps be repeated. Whether myoplasty may prevent this complication has not yet been proved.

Skin Lesions

In the socket the skin is exposed to warm humidity which when combined with skin friction against the prosthesis leads to skin lesions and infections.

In order to prevent such complications the patient should be given careful instructions in hygienic measures.

The skin should be cleansed every evening with a soap containing hexachlorophene. Irritants, mechanical (brushes) or chemical (iodine, alcohol), should be avoided.

The prosthesis should also be cleaned according to instructions (which depend on the kind of material used). A wooden prosthesis may be washed with soap containing hexachlorophene followed by clean water in the evening so that it is dry and clean in the morning.

At the first sign of infection discarding of the prosthesis is indicated for a period of time.

Staphylococcus infection with furunculosis or abscessus is the most common type of infection. Hygienic and antibacterial treatment is applied. Ultraviolet light may have a beneficial effect, and in some cases autovaccine may be helpful.

Dermatomycosis is most frequently encountered in connection with intertrigo in obese patients. Specific antimycotic treatment is the proper procedure and change of prosthetic fitting or material may be feasible.

Chemical dermatitis and eczema

A patient may be allergic to one of the materials used in the prosthesis (rubber, varnish, chromium, etc.). Skin tests reveal the agent and exclusion of the material together with dermatological care is indicated.

When a number of amputees present skin reactions it should be considered whether any of the materials used by the prosthetist may be responsible for the lesions.

Distinction from mechanical dermatitis may be difficult. It has been recorded that a plastic laminate after sanding may cause skin lesions, which are provoked by the slightly uncovered glass fibers.

Mechanical Skin Lesions

Strangulation followed by swelling, skin hemorrhages and pigmentation has been mentioned. Adjustment of the fit is important as neglect may result in large chronic ulcerations.

In spite of careful fitting certain skin areas are exposed to intense mechanical pressure. The skin in such areas may react by forming keratosis (skin horns) or epidermoid cysts, which look like pearls in the skin. The cysts may grow into the depth and by confluence form large sinuses. The sinuses only become infected after perforation at the surface. Excision is the treatment of choice because simple incision will offer only temporary cure.

THE CHILD AMPUTEE

In previous chapters the problems connected with amputations in childhood have been mentioned, and the importance of proper conservatism has been stressed.

Besides the surgical and traumatic amputations we must also deal with the congenital defects (amelias). The most frequent congenital amputations are the short below-elbow stump and the below-knee amputation. The congenital torso is fortunately rare; multiple defects are, however, rather frequent. The leg prosthesis for the child should be made with possibility for easy elongation. A prosthesis, however, rarely fits for more than one year. The principles for fitting are the same as those applied to adults. Prosthetic equipment for the child arm amputee should be started at the stage when the child begins to sit and play.

In the first year of life a passive prosthesis with a mitt may be useful for balance and for opposing the normal arm. Soon the child may benefit from a split hook with cable control.

When the child begins his social life (dancing, school, etc.) a cosmetic hand may be desirable although it is not as functional as the split hook.

The previously mentioned APRL hand is available in six and twelve year sizes. The results of the treatment of the child amputee depend largely on whether the understanding and collaboration of the parents is achieved.

TECHNICAL AIDS

Even to the most successfully treated amputee the supply of some kind of specific technical equipment may be decisive for his or her capacity and ability to resume personal independence and useful occupation. The field of technical aids covers a wide range of commercially available or specially fabricated items.

It has been mentioned that many leg amputees may want a cane or arm crutches permanently or under certain circumstances. The bilateral leg amputee and some elderly unilateral amputees need a wheelchair also, for possible night visits to the lavatory. A motor vehicle with hand operation or with automatic transmission may solve problems for certain leg amputees.

The arm amputee should, in principle, not be equipped with "one arm tools." However, the day program of the amputee should be analyzed and suggestions made for any difficult situation to be encountered. Mechanical gadgets in the kitchen, electric shaver, garments with Velcro fastenings, etc. are no luxury for the amputee.

SOCIAL SECURITY

The coverage of expenses for prosthetic equipment is in many countries managed by insurance systems or by a social security system. In principle any amputee should be supplied with two usable prostheses.

The fitting of the second prosthesis should be delayed until the stump is of definite size and quality. The doctor normally has the responsibility for the proper timing for renewal of prostheses.

The supply of technical aids may also be covered by such a system, more frequently with certain restrictions as to expenses, attention being paid to the amputee's working capacity.