ACCURATE PREOPERATIVE FABRICATION OF SUBCUTANEOUS AND BONY IMPLANTS WITH SILASTIC MDX 4–4515 AND MDX 4–4516—TECHNIQUE AND RESULTS

Donald R. Laub, M.D.

Chief, Plastic Surgery Section
Veterans Administration Hospital
3801 Miranda Avenue
Palo Alto, California 94304

Assistant Professor of Surgery
Chief, Division of Plastic and Reconstructive Surgery
Stanford University Medical School
Palo Alto, California 94305

Walter Spohn

Chief, Restorations Clinic
Ft. Miley Veterans Administration Hospital
4150 Clement Street
San Francisco, California 94121

Howard Holderness, M.D.

Resident, Division of Plastic and Reconstructive Surgery
Stanford University Medical School
Palo Alto, California 94305

Harvey Lash, D.D.S., M.D.

Clinical Assistant Professor of Plastic Surgery
Stanford University Medical School
Palo Alto, California 94305

Lawrence Crowley, M.D.

Chief, Department of Surgery
Veterans Administration Hospital
3801 Miranda Avenue
Palo Alto, California 94304

Professor of Surgery
Stanford University Medical School
Palo Alto, California 94305

With the advent of high velocity missile wound injuries such as seen in the Vietnam era, tissue damage is widespread in many cases. With the unavailability of unscarred local tissue for reconstruction, some recent emphasis has been placed on the use of prosthetic materials. Over the years various materials have been evaluated for subcutaneous implantation in the maxillofacial area, but many of these materials are less than ideal. Autogenous tissue, of course, has been used successfully in the form of distant flaps, grafts of dermis, dermis fat, cartilage, and bone.

Metals such as stainless steel, Vitallium, tantalum, and zirconium provide good structural integrity but are difficult to form to the contour of the face (1, 2, 3). Ivory has been used primarily in nasal and skin augmentation with good results. The use of ivory presents two disadvantages, however. It must be carved with a burr at the time of surgery to fit the contour, and it causes some tissue reaction.

Various plastics have been evaluated. These are listed as follows:

1. *Ivalon* (polyvinyl alcohol-formal) (1, 4, 5) is a spongy material which causes only a slight reaction but shrinks in size as connective tissue grows into it and matures into scar tissue. Any open cell sponge will eventually shrink and harden because of invading scar tissue and subsequent contraction.

2. *Marlex* (polyethylene) (1, 4) has been used as a textile, a sponge, or a solid. Polyethylene is relatively easy to work with but causes enough tissue reaction that it cannot be consistently retained.

3. *Etheron* (polyurethane) (1, 4) is supplied as a foam sponge or solid. It is chemically and mechanically unstable, causing tissue reaction, and is absorbed to some extent.

4. *Dacron* (polyester or polyethylene terephthalate) (4) is supplied as a textile and as a solid. It seems to cause very little reaction and is widely used in vascular surgery. The cloth has also been used as a backing for Silastic implants, allowing connective tissue to grow into its interstices and impeding migration of the implant. The solid form (Mylar) is firm and stiff and, to our knowledge, has not been used extensively for implant purposes.

5. *Teflon* (polymer ff tetrafluoroethylene) (4, 6, 7) is one of the least reactive materials. This is supplied as a liquid, a textile, and a hard solid. The solid form has a slight tendency to flow under stress at room temperature.

6. *Cranioplast* (acrylic, methyl methacrylate, polymer of the ester of methacrylic acid) (1, 4, 8, 9, 10) has been used for replacement of cranial and forehead defects and is commonly used by neurosurgeons in cranioplasty operations. It is usually supplied as a powder and is molded with a catalyst to fit the defect at the time of surgery. The formation of complex shapes is difficult. Room temperature quick-cure

preparations contain enough free monomer to cause tissue reaction.

7. *Silastic* [a] or silicone (polymer of dimethylpolysiloxane) (4, 11, 12, 13) is one of the most physiologically inert substances known. There is no known organism, plant or animal, that can metabolize medical-grade silicone rubber. It appears to be noncarcinogenic, is mechanically and heat stable, and does not change with aging. Furthermore, silicone rubber can be easily shaped and molded preoperatively to the exact configuration desired.

Preformed silicone implants are available for nasal and chin augmentation. Carved block silicone (14) has been used extensively, but it is difficult to form it into a perfectly accurate and smooth reconstruction in the areas of the glabella or supraorbital rim (15). The silicone impression, or inlay method as described by Harvey Lash in 1964 (16), has been used by us in the fabrication of implanted subcutaneous prostheses for the restoration of contour in the head and neck area.

METHODS AND TECHNIQUE

The following account describes our experience with 25 cases which have been treated with this form of therapy. The impression technique has been used in the restoration of congenital and traumatic deformities. In traumatic cases 6 months have been allowed to lapse after the wounds have been fully healed before surgery has been performed.

The technique consists of coating the face with a lubricant, such as Lubafax or Vaseline, and making a facial moulage of the patient by applying dental alginate to the face. This solidifies in 1–3 min. after which a reinforcing layer of plaster is applied. During this procedure the patient is in a sitting position and breathing occurs through the nostrils which are not covered. When the outer layer of plastic is dry, the alginate is removed from the face intact. Plaster, or room temperature vulcanizing acrylic, is poured into the mold to form a model of the patient's face. The facial reproduction is then separated from the alginate negative. Dental wax or modeling clay is placed over the defect in the facial reproduction, and a restoration model is shaped to achieve the desired form or symmetry. A mold is then made by placing the restoration model in a dental flask containing dental plaster. When the plaster is firm the wax is replaced in the dental flask with raw silicone (Dow Corning medical-grade Silastics MDX 4–4515 or MDX 4–4516). [b] This raw silicone rubber is soft and putty-like and capable of achieving any form, but may require milling with a machine.

The material is vulcanized by placing the flask in a press at 10,000

[a] Registered tradename of the Dow Corning Corporation, Midland, Michigan.

[b] Dow Corning has changed nomenclature (October 1, 1969). Silastic MDX 4–4515 was formerly 372, and Silastic MDX 4–4516 was 373.

lb./sq. in. at 400 deg. F. for 10 min. Vulcanization changes the raw silicone rubber into a firm rubbery material which retains its shape under stress and is stable to heat, cold, and aging.

The silicone implant is then removed from the flask and placed in an air-circulating oven at 350 deg. F. for 4–6 hours to allow curing.

The prosthesis is tried on the patient externally to double check for proper fit.

Following curing, the prosthesis is carefully scrubbed, cleansed, and autoclaved and is ready for implantation.

The surgical technique is tailored to the operative site and condition of the defect. For the forehead or periorbital prosthesis the incision is placed away from the implant areas fashioning a large flap. The dissection is extended in the subperiosteal plane down to the underlying bone which surrounds the defect, and the implant is secured in place by permanent sutures, e.g., Teflon coated polyester sutures placed through holes drilled in the bone. The dissection has also been made in the subgaleal plane and the sutures placed in the periosteum. The implant has been found to fit quite accurately, forming a smooth contour. If the implant is too large, which is, of course, possible since the model used represents the external defect, and not the actual bony or soft tissue defect, it can then be modified with a scalpel. Suction draining for 24 hours and a pressure dressing help prevent seroma formation.

The silicone used is Dow Corning Silastic MDX 4–4515 or MDX 4–4516 (Table 1). It is made up of a polymer, a filler, and a vulcanizing agent. The polymer is dimethylpolysiloxane. The filler is extremely fine silica (SiO_2) particles of 0.020 micron size (17). It reinforces the rubber and imparts strength after interacting with the polymer. The vulcanizing agent is dichlorobenzoyl peroxide which forms free radicals when heated and causes cross-linkages to form between adjacent polymer chains. The vulcanizing agent changes the putty-like easily-molded elastomer Silastic MDX 4–4515 or MDX 4–4516 into a rubber that has a permanent shape. After vulcanization, heating or curing drives off all volatile products (17).

TABLE 1.—*Heat Vulcanizing Silastic Medical-Grade Elastomer*

		Vulcanization		
Silastic 370	soft	260°F.	pressure required	10 min.
Silastic 372	medium	240°F.	with pressure	10 min.
		300°F.	without pressure	
Silastic 373	hard	240°F	with pressure	10 min.
		300°F.	without pressure	

RESULTS

Accurate reconstructions using this technique have been made in 25 cases. Table 2 displays the results according to anatomic area and lists the complications. It has been noted that the stability of the implant in tissue and the freedom from infection are improved in the relatively immobile areas of the forehead where intimate bony contact is obtained.

TABLE 2

Location	Number of Patients	Complication
Forehead, Periorbit, and Temple	22	1 (Prosthesis slightly large)
Zygoma	3	1 (Infection) [a]

[a] Removal not required.

The technique has been found to be particularly useful in treatment of patients with complex bony defects in the forehead, periorbital, and glabellar areas. Trial and error fabrication with carved solid silicone, with room temperature vulcanizing silicone, or methyl methacrylate may be time consuming and inaccurate when the implant is fashioned at the time of surgery.

Seroma formation in the first 10 days following implantation is quite common but appears to be a benign problem.

BRIEF CASE REPORTS

R. V., 22-year-old infantryman, sustained high velocity missile wound injury November 1967 in Vietnam, resulting in a left fronto-temporal bony defect (Fig. 1), and loss of the left eye and portions of the left frontal and parietal lobes of the brain. Meningitis was treated in Japan. Restoration with a molded Silastic implant was carried out in October 1968 (Fig. 2).

R. H., 21-year-old soldier, sustained loss of left eye and left frontal periorbital bone (Fig. 3) January 1968 from an AK–47 high velocity rifle wound. Restoration with a Silastic prosthesis with Dacron cloth on the external surface of the implant was performed in December 1968 (Fig. 4).

DISCUSSION

The method appears to be a useful therapeutic technique which is helpful in the surgical restoration of certain defects in the maxillofacial area which result from trauma, congenital defects, or the surgical treatment of malignant disease. It appears to have advantages over the use of carved solid silicone block because the contour of the implant is smooth. If desired, the prefabricated prosthesis can be easily modified

FIGURE 1.—R.V. preoperatively.

FIGURE 2.—R.V. postoperatively.

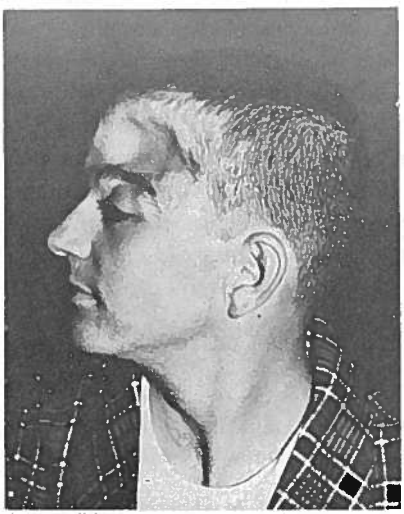

FIGURE 3.—R.H. preoperatively.

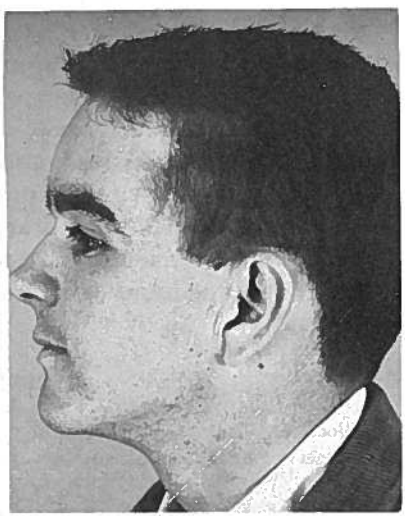

FIGURE 4.—R.H. postoperatively.

by the incorporation of Dacron cloth to the deep and/or superficial surface of the implant. Stainless steel mesh or a metallic plate can be incorporated into the interior of the implant to impart stiffness. Through-and-through perforations of the implant can be made to allow drainage of fluid or blood from the deep surface, e.g., the epidural space to the subcutaneous area, and to allow ingrowth of fibrous tissue for stabilization, if this is desired.

Disadvantages include the fact that the implant is fabricated from a

model made from the external defect, and it may therefore be slightly larger than the actual bony defect or the existing subcutaneous tissue loss. It has been found recently that further accuracy can be achieved by lining the alginate negative of the defect, or the model itself, with a layer of material which corresponds to the thickness of the skin and subcutaneous tissue which overlies the actual defect (18).

This technique can be performed by anyone familiar with the use and safety of the materials but is, of course, facilitated by the technical or professional assistance of a practitioner of anatomic facial and body restorations or by dental prosthetists. We have found it convenient occasionally to make the impression, the model, and the wax or clay restoration. We then transmit this to the laboratory personnel for fabrication.

The technique is not entirely standardized. Since modifications are being made in the method and the implants themselves from time to time, the technique is considered to be evolving as experience dictates.

SUMMARY

We have used the silicone inlay method of prefabricating subcutaneous and bony implants for congenital and acquired defects of the maxillofacial area in 25 cases. Heat vulcanizing Silastic 372 or 373 was used and appears to be satisfactory. The method is presented as a useful adjunct in the surgical restoration of subcutaneous and bony defects, particularly complex contours of the periorbital area when autogenous tissue is unavailable. Complications appear to be less common when the implant is immobile and secured to the bone. The method is evolving, and modifications can and should be made in the technique as needed.

REFERENCES

1. Blocksma, Ralph and Silas Braley: Implantation Materials, p. 111. *In* Plastic Surgery, edited by William C. Grabb and James Smith, Little Brown and Co., Boston, 1968.
2. Morral, F. R.: Cobalt Alloys as Implants in Humans, J. of Materials, 1:384, 1966.
3. Scott, Michael: Long Term Evaluation of Stainless Steel Cranioplasty, Surg. Gynec. & Obstet., 115:453, 1962.
4. Block, Bernard and Garth W. Hastings: Plastics in Surgery. Charles C Thomas, Springfield, Illinois, 1967.
5. Brown, J. B., D. A. Ohlwiler, and M. P. Fryer: Investigation of and Use of Dimethylsiloxanes, Halogenated Carbo S, and Polyvinyl Alcohol as Subcutaneous Prostheses, Ann. Surg., 152:534, 1960.
6. Brown, J. B., M. P. Fryer, Peter Kolias, David Ohlwiler, and J. B. Templeton: Silicone and Teflon Prostheses, Including Full Jaw Substitution: Laboratory and Clinical Studies of Etheron, Ann. Surg., 157:932, 1963.
7. LaVeen, Harry H.: Tissue Reaction to Plastics Used in Surgery with Special Reference to Teflon, Ann. Surg., 129:74, 1949.

8. Blaine, George: Experimental Observations on the Use of Absorbable and Non-absorbable Plastics in Bone Surgery, Brit. J. Surg., 33:245, 1946.
9. Blaine, George: The Uses of Plastic in Surgery, The Lancet, 2:525, 1946.
10. Blum, George: Experimental Observations of the Use of Absorbable and Non-absorbable Plastics in Bone Surgery, Proc. Royal Soc. Med., 38:169, 1945.
11. Braley, Silas: The Silicones in Maxillofacial Surgery, The Laryngoscope, 78:549, 1968.
12. Braley, Silas: Use of Silicones in Plastic Surgery, Arch. Otolaryngology, 78:669, 1963.
13. Speirs, Alfred C. and Ralph Blocksma: New Implantable Silicone Rubbers: An Experimental Evaluation of Tissue Response, Plast. & Reconstr. Surg., 42:166, 1968.
14. Courtemanche, A. D. and G. B. Thompson: Silastic Cranioplasty Following Craniofacial Injuries, Plast. & Reconstr. Surg., 41:165, 1968.
15. Rhodes, Robert D.: Restoration of Facial Defects with Individually Prefabricated Silicone Prostheses, Plast. & Reconstr. Surg., 43:201, 1969.
16. Lash, Harvey, Donald Zimmerman, and Robert Loeffler: Silicone Implantation: Inlay Method, Plast. & Reconstr. Surg., 34:75, 1964.
17. Heat-Vulcanizing, Medical-Grade Silicone Elastomers. Bulletin of the Dow Corning Center for Aid to Medical Research, Midland, Michigan.
18. Tolleth, Hale C.: Personal Communication, 1969.