WOUND HEALING

Ernest M. Burgess, M.D.

Principal Investigator, Prosthetics Research Study
Eklind Hall, Room 409, 1102 Columbia Street
Seattle, Washington 98104

The response of living tissue to trauma—chemical, thermal, or mechanical—is of prime concern to the physician. This is particularly true in surgery. The body, not the surgeon, repairs wounds. The surgeon is responsible for providng optimum environmental circumstances for wound healing consistent with the surgical problems he faces. Gentleness in the handling of tissues is the first surgical axiom. The knife destroys; nature heals. The process of tissue repair encompasses a most complex, interrelated group of biochemical, electrical, and genetic phenomena. Cellular reproduction is the very essence of life.

The amputation is an excellent clinical laboratory for the study of wound healing. Since the surgical trauma is terminal, there are no tissues distal to the operative site which require body support for viability. Physical modalities such as pressure, temperature, and immobilization can be controlled and measured without concern for a more distal uninvolved body segment. The Prosthetics Research Study (PRS) accepted the assignment to investigate immediate postsurgical prosthetic amputee fitting on the basis of a wound-healing study. Ongoing investigations continue to emphasize wound healing as a primary concern.

Our study of the complex and little understood mechanism of wound healing has been confined to the application of certain physical influences on the immediate postsurgical amputation wound. Tissue rest (immobilization) early in the process of wound repair is important. Animals involuntarily splint an injured limb. For centuries this simple fact has been carried over into management of injured body tissue. The degree and duration of immobilization has been the subject of considerable study. The term arthrofibrosis is used to designate the ill effects of prolonged immobilization for joint injuries. The graduated transition from rest to function will depend on the nature of the tissue injury and the type of tissues involved.

The chemical and vascular phenomena involved in injury cause intracellular and extracellular fluid accumulation. Control of this posttraumatic edema has also been incorporated into wound management for hundreds of years. Elevation of the injured part, the application of

compressive dressings, massage, and voluntary muscle activity are all part of conventional limb wound management. Edema control is undoubtedly one of the most important factors for a satisfactory wound-healing environment. Other physical parameters include temperature, humidity, sterility, chemical (gas) composition, intermittent or continuous wound lavage, and the application of chemcial agents.

The PRS immediate postsurgical prosthetic dressing is of rigid design to immobilize and to provide edema control by a pressure interface together with changes of position of the limb, protected weight-bearing under certain circumstances (Fig. 1 and 2), and activity of limb muscles. It also seeks to provide a dry, clean wound atmosphere at average room temperatures. Adequate hemostasis and drainage prevent hematoma

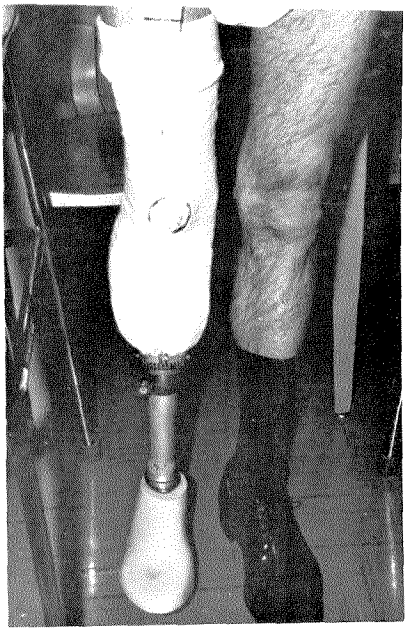

FIGURE 1.—Weight-bearing below-knee immediate postsurgical rigid dressing prosthesis.

FIGURE 2.—Weight-bearing knee-disarticulation and above-knee type of immediate postsurgical prosthesis.

formation. The physical and psychological advantages of patient mobility and ambulation have been highlighted as part of the PRS management protocol. They are considered important but ancillary to the wound-healing process in the stump itself. Over the last several years, observation of the results of this wound management (Fig. 3 and 4) through many hundreds of cases has allowed us to upgrade and simplify techniques. Each amputation we have done using the PRS system has been viewed as a wound-healing experiment. Documentation includes

the clinical records, routine serial photographs, measurements, and in certain cases, pressure, temperature, and skin tension readings in certain areas of the healing stump. Based on these data, we have modified and improved our system. The below-knee postsurgical dressing is illustrated in its various components (Fig. 1). Immediate postsurgical dressng at a level other than the lower limb is also shown (Fig. 5).

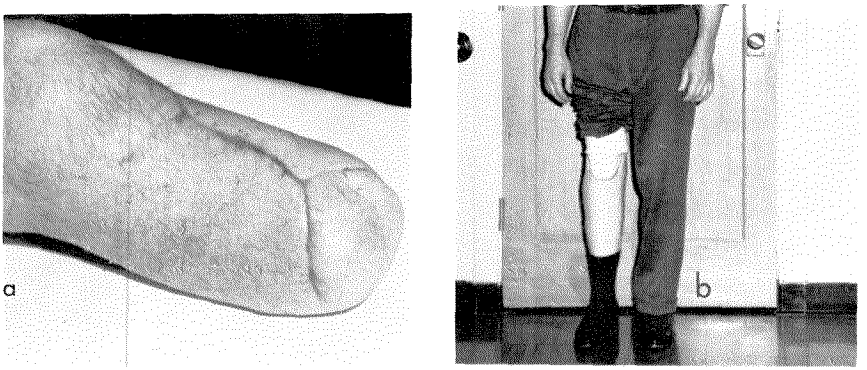

FIGURE 3.—Demonstrates early wound healing as a result of using reconstructive-plastic surgical approach and rigid dressing and postsurgical prosthetic management.

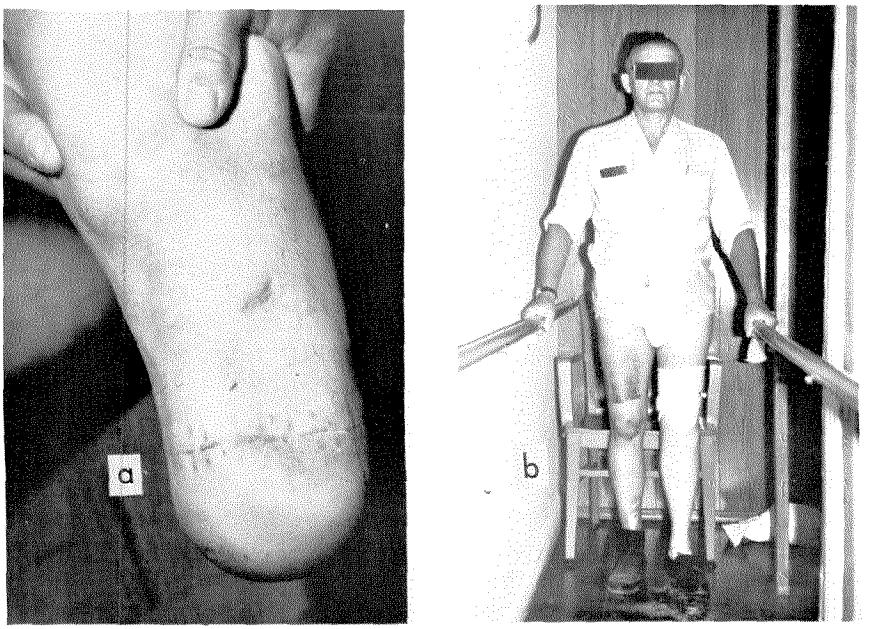

FIGURE 4.—Below-knee amputation showing primary wound healing with PRS management.

FIGURE 5.—Below-elbow immediate post-surgical prosthesis.

In March 1974 we entered an agreement with members of the Biomechanical Research and Development Unit, Department of Health and Social Security, Roehampton, London, in the investigation of a controlled environment chamber for the treatment of postoperative wounds of the upper and lower limbs, including amputation stumps (Fig. 6). Preliminary information from this coordinated investigation will be jointly submitted. We are enthusiastic about the data and results obtained with the Roehampton wound environment system.

This brief discussion on wound healing relates only to those factors under investigation at the Prosthetics Research Study. The complex nature of the process at the cellular level is recognized. Information obtained from all sources must continue to be incorporated into clinical studies of the type we now pursue.

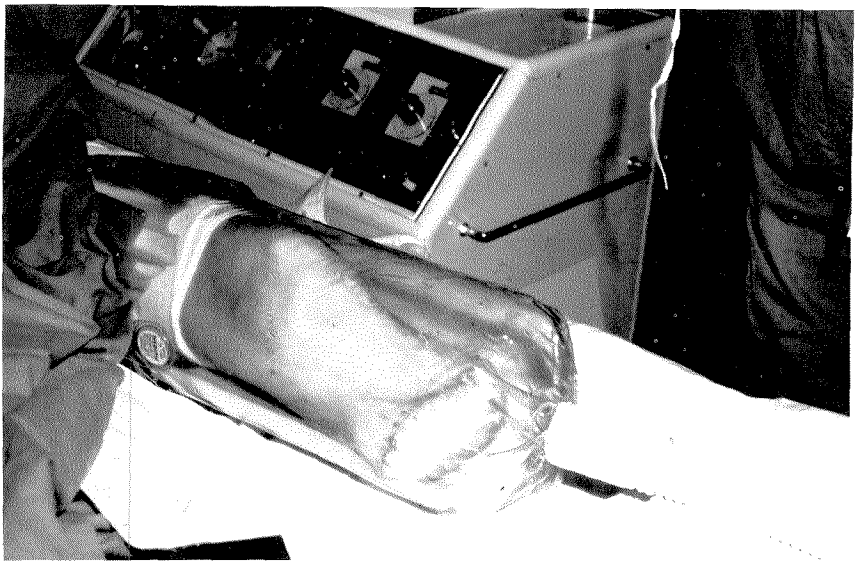

FIGURE 6.—Controlled environment chamber applied immediately after below-knee amputation. Environment sterility and gas composition are controlled in this (Roehampton) unit.