Veterans Administration

Journal of Rehabilitation Research and Development Vol. 25 No. 3
Pages 33–40

Speech restoration post-pharyngolaryngoesophagectomy using tracheogastric fistula

KRZYSZTOF IZDEBSKI, FK, MA, PhD, CCC, JOEL C. ROSS, MD, FACS, DOUGLAS HETZLER, MD, JAMES FONTANESI, MD, and PETER KRUMPE, MD
Pacific Presbyterian Medical Center, San Francisco, California 94120 and Veterans Administration Medical Center, Martinez, California 94553

Abstract—Restoration of voice and speech in patients with gastric pull-up presents a formidable challenge, and many of these patients are left at best with a poorly functional electrolaryngeal speech. To improve this condition, a tracheogastric puncture stented with a biflanged self-retaining Groningen voice button was accomplished, resulting in gastric mucosa vibrations during exhalatory phase. The biomechanical characteristics of gastric vibrations and tracheogastric puncture candidate selection criteria are discussed.

Key words: *biomechanics, fistula, gastric pull-up, gastric vibrations, tracheogastric voice, Groningen voice button/prosthesis, pharyngolaryngoesophagectomy, speech/voice restoration, tracheoesophageal and tracheogastric punctures.*

INTRODUCTION

A successful pharyngolaryngoesophagectomy with pharyngogastric anastomosis—the so-called gastric pull-up surgery—involves a variety of postoperative functional alterations, including alimentation and speech. Although the problems involved in solving the postoperative difficulties of swallowing and digestive processes have been discussed extensively, restoration of voice and speech in these patients has been largely unsuccessful (1-4, 7-9). For example, of the 136 cases of gastric pull-up performed at the Queen Mary Hospital in Hong Kong, speech rehabilitation was highly unsatisfactory, with only 9 patients (6.6 percent) able to produce audible whisper, and 6 patients (4.4 percent) able to use an electrolarynx. This occurred despite the fact that 87 percent of patients achieved satisfactory alimentary functions (8).

Reviewing their experience with pharyngoesophageal reconstructive techniques, Schechter *et al.*, report that gastric pull-up resulted in better functions of swallowing, weight maintenance, and speech than deltopectoral flap, pectoralis major flap, or jejunal graft (7). Nonetheless, speech restoration for all types of pharyngoesophageal reconstruction was not considered to be satisfactory, and involved single word utterances or was achieved only with the aid of an electronic device. Although better speech quality was obtained for the gastric pull-up group than for the other categories, since these patients were able to inject air transorally and generate neoesophageal sound, the functional scores for speech were still poor.

Of the 101 gastric pull-up surgeries performed in England by Harrison and his colleagues, acquisition

Address all correspondence to: Dr. K. Izdebski, Pacific Presbyterian Medical Center, P.O. Box 7999, San Francisco, CA 94120.

Dr. Izdebski is Chief of Speech Pathology and Audiology, Director of Voice Physiology Laboratory, Head and Neck Function Clinic, Pacific Presbyterian Medical Center, and Associate Clinical Professor of Otorhinolaryngology, University of California, Davis.

Dr. Ross is Attending Otolaryngologist, VAMC, Assistant Clinical Professor, Department of Medicine, University of California, Davis.

Dr. Hetzler is Chief, Otorhinolaryngology, VAMC, Assistant Clinical Professor, Otorhinolaryngology, University of California, Davis.

Dr. Fontanesi is Brachy Therapy Fellow, West Coast Cancer Foundation, VAMC.

Dr. Krumpe is Chief, Pulmonary Medicine, VAMC, Associate Professor, Department of Medicine, University of California, Davis.

Journal of Rehabilitation Research and Development Vol. 25 No. 3 Summer 1988

of an adequate voice was possible only in a small number of patients, in contrast to the number who regained trouble-free eating ability (1). Patients who were able to produce voice did so by manual compression of the cervical stomach, or when experiencing pharyngogastric fistulas. Although Harrison *et al.* (2) stated that, in their view, tracheogastric shunt may be of considerable use in restoring speech in pharyngolaryngoesophagectomized patients, they did not elaborate on this approach. A tracheojejunal fistula stented with a Blom-Singer voice prosthesis resulted in successful restoration of speech in 3 patients reported recently by Salamoun *et al.* (6). Five successful cases of tracheogastric fistula for speech restoration were also reported by Holden at London's Charing Cross Hospital (3).

In our attempt to restore voice function in a patient with gastric pull-up, we drew upon experience involving voice rehabilitation using tracheoesophageal (TE) puncture procedures (5). The results of this modified TE approach, which we termed TG (tracheogastric) puncture procedure, are described in this paper.

CASE REPORT

The subject of the study was a 73-year-old male with a 2-month history of intermittent hoarseness, dysphagia, and odynophagia, who had had a 16-pound weight loss in the 6 months prior to admission. His past history included T_1 squamous cell carcinoma of the left vocal fold treated with external beam radiation therapy 10 years prior to admission. The patient had continued his smoking habit during those 10 years.

Endoscopy showed a large ulcerated lesion of the left pyriform sinus extending into the cervical esophagus, which prevented passage of the rigid esophagoscope.

Endolaryngeal structures appeared normal. Barium swallow showed a 3.5 cm diameter mass of the cervical esophagus. Nutritional support was instituted in the form of nasogastric (NG) feedings. The patient experienced airway compromise and required a tracheostomy. He subsequently underwent a pharyngolaryngoesophageoctomy in conjunction with a left radical neck dissection, total thyroidectomy, gastric pull-up, parathyroid reimplantation in the right forearm, and a feeding jejunostomy.

Postoperatively, the patient developed a left pleural effusion requiring a thoracostomy tube; hypocalcemia requiring supplementation of calcium and vitamin D; weakness of the right arm which resolved spontaneously; and a pharyngocutaneous fistula which closed with conservative treatment. Swallowing improved following closure of the fistula, and the patient did well on 6 small tube feedings per day, without symptomatic regurgitation. The patient refused postoperative radiation therapy. Throughout his recovery period, he showed signs of being able to develop "gastric" sounds consisting of occasional grunts, but a greater degree of voice restoration was desired. This prompted us to attempt a tracheogastric fistula procedure to be stented with a voice prosthesis.

Preoperative testing

Prior to attempting tracheogastric fistulatization, the patient was tested for the ability to produce gastric voice. This was accomplished by a 2-stage insufflation test procedure. During stage one (external insufflation) a #16 French red rubber catheter was passed into the cervical gastric space. Positive air pressure/air flow was applied via the catheter as the patient sustained varied oral cavity postures that simulated the position for various sounds. Sustained phonation and speech lasting for the duration of insufflation were produced by this method. To estimate the amount of air pressure/air flow needed to generate voicing, insufflation by mouth was also performed. Air was blown into the catheter (#16 French) as the patient performed sustained sound and connected speech gestures, which resulted in acceptable phonation and/or speech. Air pressure/air flow requirements were deemed to be not excessive.

To verify these findings, and to assure that the patient would be able to produce voicing using his own respiratory air flow, the stage two insufflation test was performed. It involved passing a #16 French red rubber catheter in the same fashion as above, but this time the proximal housing of the insufflating catheter was attached to the stoma of the patient. Occluding the housing with the investigator's finger allowed for passage of pulmonary air into the cervical gastric region that produced sus-



Figure 1.
A videoradiograph showing positioning of the insufflation catheter (arrow) high in the cervical gastric air space, resulting in a friction-like sound and limited vibration of the gastric mucosa.

tained sound and connected speech. This procedure was videotaped, using a flexible fiberoptic bronchoscopy unit. Contraction of the gastric cervical stomach was confirmed during production of sustained sound and connected speech.

Surgical procedure

Under general anesthesia, a secondary TG fistula was created, using a Groningen tracheal puncture forcep. With the patient in a supine position, a rigid esophagoscope was placed into the cervical stomach via the oral cavity. The esophagoscope was turned 180 degrees to expose the beveled edge toward the penetration site, which was within the visible lumen of the stoma. Considerable force was required to puncture through the gastric wall. Immediately following the puncture, the voice prosthesis was inserted, using the procedure described by the Groningen group (5). The fistula site was placed at the level of the inferior margin of the stoma.

RESULTS

Immediately following surgery, the patient was able to produce faint phonation and speech with occlusion of the stoma performed by one of the investigators. The patient was reexamined within 48 hours of surgical recovery, at which time the stoma was cleaned and the button was ventilated with external pressurized air. This was achieved by inserting a #14 French catheter into the lumen of the Groningen voice prosthesis. During this ventilation, strong voicing and speech were produced. But the quality of voice decreased significantly (weakened) when the patient attempted to speak using his own respiratory air supply while covering the stoma. This

Journal of Rehabilitation Research and Development Vol. 25 No. 3 Summer 1988

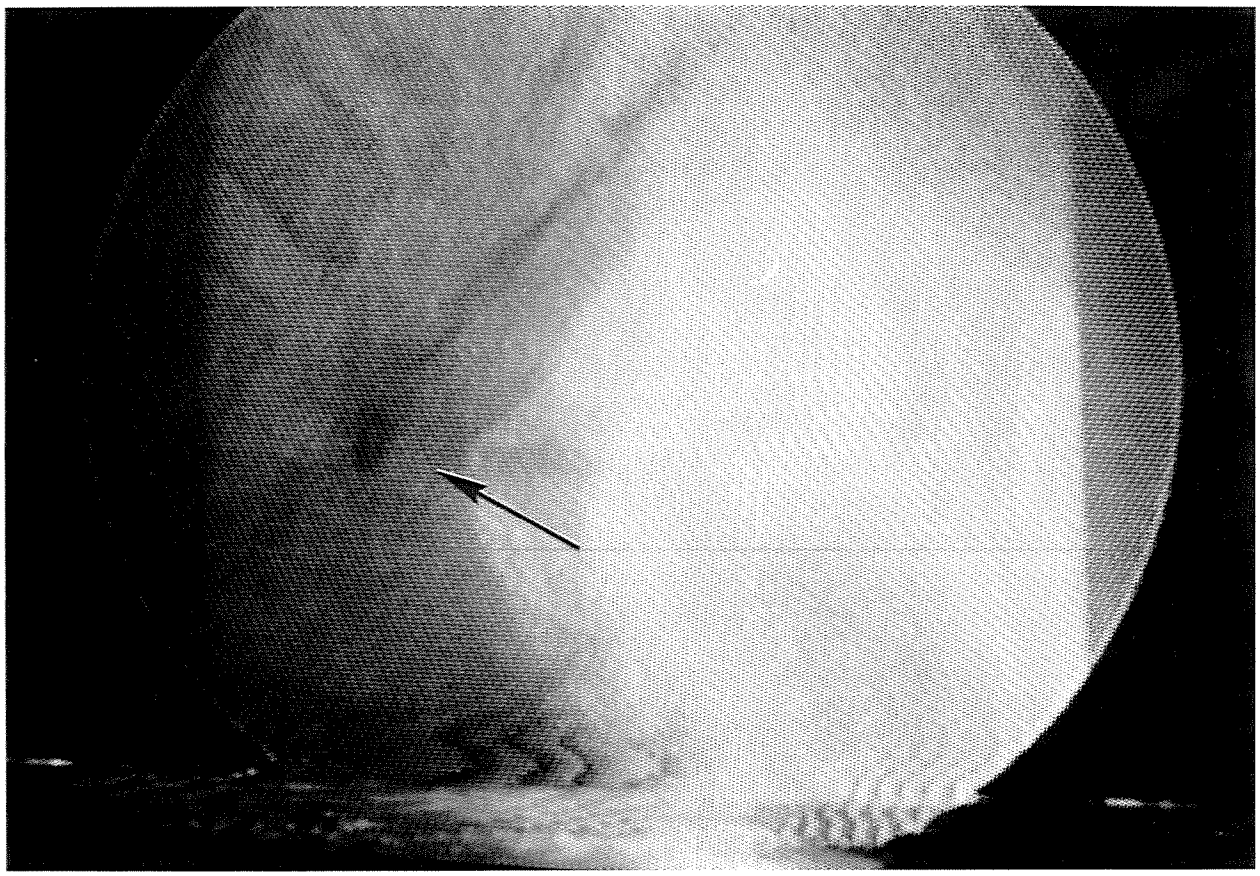

Figure 2.
A videoradiograph showing deep positioning of the insufflation catheter (arrow) in the cervical gastric air space, resulting in improved sound generation and creation of a neoglottis above the tip of the catheter.

occurred despite the absence of air leakage from around the occluding finger. The procedure of external ventilation was repeated and good voice was achieved, though again, it could not be duplicated by the patient's own attempts. However, this difference could perhaps reflect residual postoperative swelling, requiring higher air pressure/air flows to set the gastric mucosa into vibration.

To verify the preoperative findings, the patient was reinsufflated at 6 days post-puncture, using the stage two procedure. As previously, this resulted in a production of good voicing, with soft but adequate loudness for speech. The insufflation catheter (#16 French) was then marked at 1-inch intervals and an opaque marker was attached to its distal end. Videoradiography was used to document the level of the catheter tip at which insufflation voicing was optimal. Raising the catheter from the optimal position resulted in a weaker voice and decreased volume (**Figure 1**), while pushing the catheter deeper into the gastric space increased the volume and improved vibrations (**Figure 2**). When the position of the distal tip of the catheter was matched to the *in situ* depth of the Groningen prosthesis, it became apparent that the depth at which the prosthesis was inserted accounted for the poor voice quality, as compared to the insufflation voice quality. Optimal voice quality was produced at a point 15 mm below the placement of the prosthesis, where the lumen of gastric space had narrowed sufficiently to provide vibratory capability.

Based on this result, a decision was made to create a lower TG fistula. The second fistula was punctured 15 mm below the primary site, and a new Groningen voice prosthesis was put into place 25 mm below the inferior edge of the stoma (**Figure 3**). Following this procedure, the primary Groningen voice prosthesis was removed. Closure of the primary fistula was achieved spontaneously within 24 hours. Next morning, the patient was able to

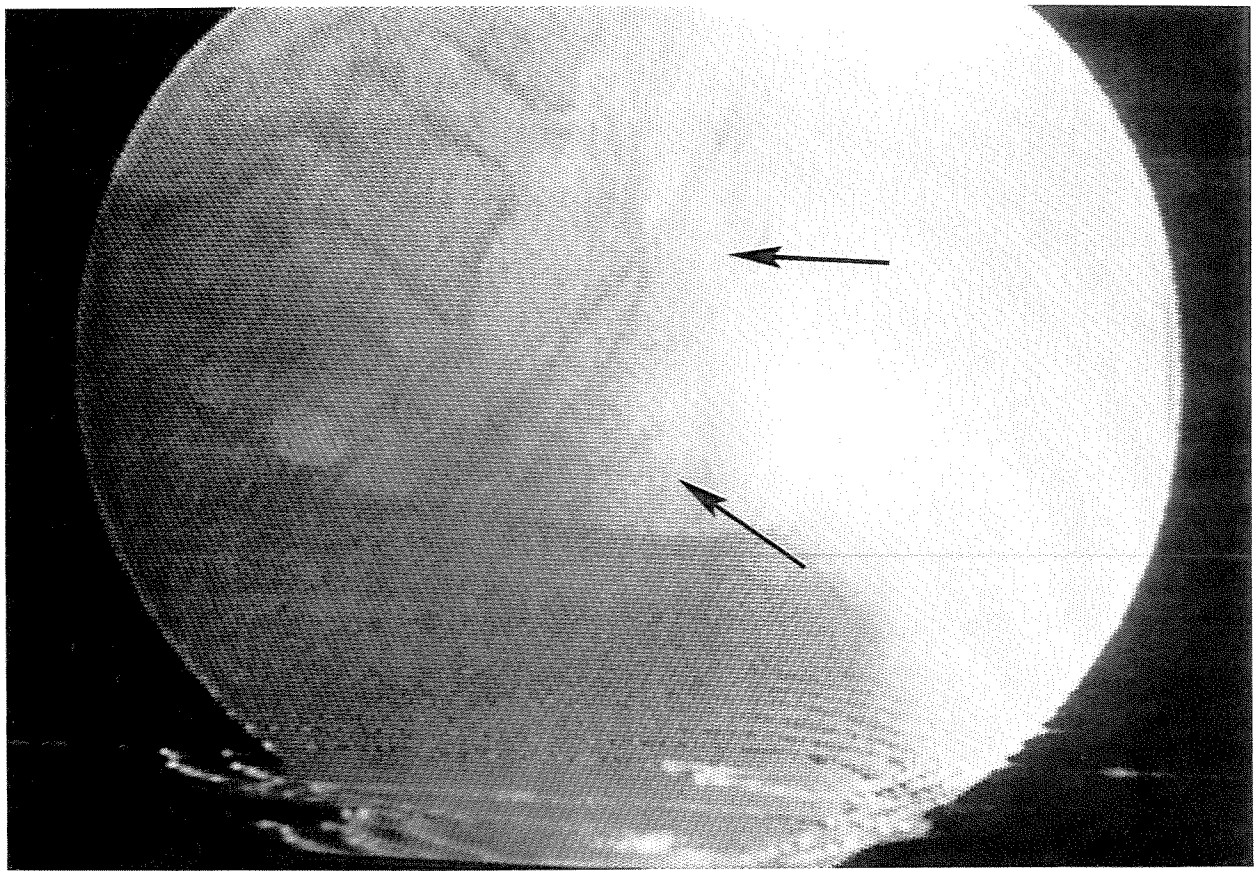

Figure 3.
A videoradiograph showing optimal positioning of the Groningen voice prosthesis (lower arrow) in the cervical gastric air space and a creation of a clearly visible neoglottis (upper arrow).

swallow without evidence of leakage through the primary fistula. The function of the new prosthesis was retested 48 hours postoperatively. Stomal occlusion performed manually by one of the investigators resulted in adequate voicing and speech (high lung volume); but voicing and speech quality deteriorated significantly when occlusion was done by the patient, because of his inability to synchronize respiratory drive, stoma occlusion, and articulation. This may have been the result of his apraxia-like behavior, which had developed following the pull-up surgery.

To verify the gastric and tracheal pressure requirements needed to generate TG sound, a series of aerodynamic measures were taken. These consisted of measuring simultaneously: a) gastric air pressure (using an esophageal latex balloon); b) tracheal pressure (using a custom-made housing with a lead to the differential pressure transducer enclosed within this housing); and, c) oral air flow via a pneumotachograph. Air pressures were measured directly, using a calibrated differential air-pressure transducer system (model CD 18 Validine Corporation, Northridge, CA). The outputs from the transducer were fed into biologic amplifiers (Model VR 6, Electronics for Medicine, Pleasantville, NY) and were written out on a paper strip (running at the speed of 25 mm/sec for further measurements). Oral air-flow signal from a pneumotachograph (Fleisch #6) was calibrated from external air-source at room temperature and humidity. Phonation loudness was measured at a distance of 1 m in a free field, using a sound pressure level meter. Sound pressure measurements were taken when the pneumotachograph mask was removed from patient's face.

To produce soft phonation (<60dB) during insufflation (external method), an average of 25 cm H_2O of gastric pressure was needed. For mid-loudness of about 60dB, 75 cm H_2O gastric pressure was needed; for loud phonation (>65dB), between

Journal of Rehabilitation Research and Development Vol. 25 No. 3 Summer 1988

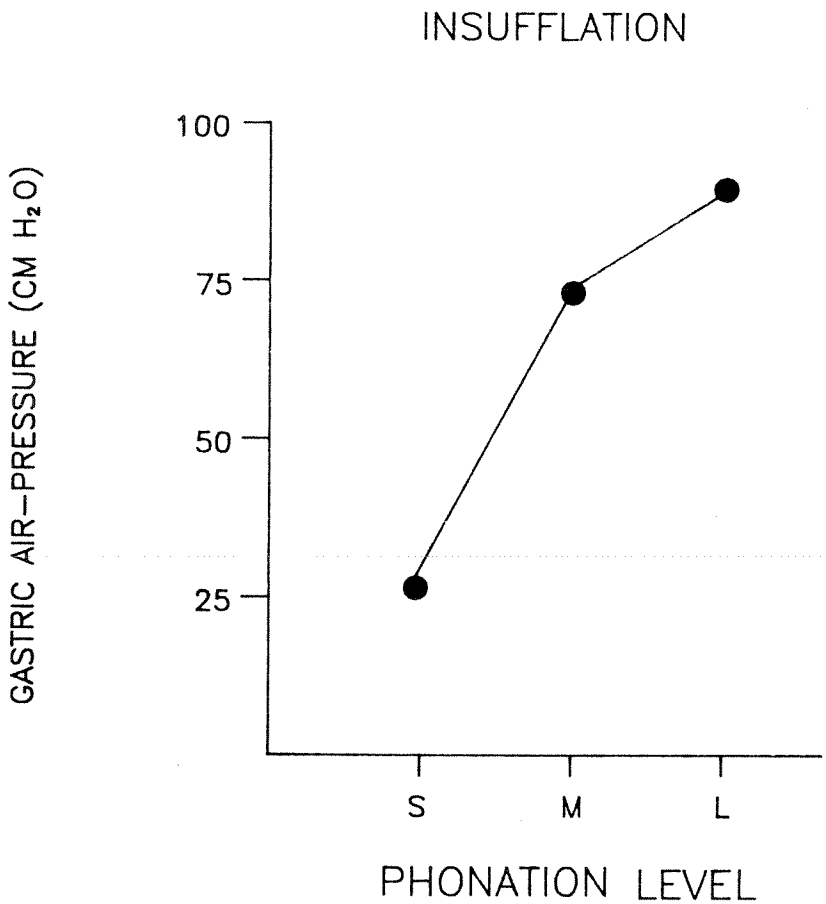

Figure 4.
Plot of gastric air pressure (P_G) in cm H_2O generated for soft (S), mid (M) and loud (L) phonation during external insufflation test. (See text).

80 and 90 cm H_2O gastric pressure was necessary (see **Figure 4**). However, when the tracheal and gastric pressures and air flow were measured simultaneously, as the patient attempted to produce phonation, the generated gastric pressure did not exceed 50 cm H_2O; tracheal pressure was only slightly higher (less than 60 cm H_2O), and the air flow at the mouth was low (an average of 30 cc/sec). (This is illustrated in **Figure 5**.) This aerodynamic profile (tracheal versus gastric pressure difference less than 10 cm H_2O; low air-flow) was inadequate for production of functional phonation despite the optimal positioning of the prosthesis under the vibrating segment.

CONCLUSIONS AND DISCUSSION

Failure to restore speech has been associated with pharyngolaryngoesophagectomies. The technique of TE puncture combined with a voice prosthesis was modified in this study to restore speech in a patient with gastric pull-up via a TG puncture procedure. Crucial to the prosthetic restoration of voice were several factors, including: 1) identification of an optimal location for placement of the fistula and prosthesis; 2) pressure requirements; 3) prosthetic design; and, 4) patient status. A Groningen voice button was used because it can be placed within the trachea without the need for external attachment. Therefore, it could be placed deeper in the trachea than any other available prosthesis.

For sound to be produced, it was necessary to obtain a critical gastric space to create vibrating neoglottis. Placement of the prosthesis high in the trachea was unsuccessful due to the wide gastric space that was unable to contract sufficiently to create vibrations but generated only short friction-like segments. This friction was of inadequate power to produce acceptable speech and resulted in rapid losses of phonatory air reserves, which necessitated frequent inhalations. Lowering the voice prosthesis 15 mm satisfied the criteria for the critical

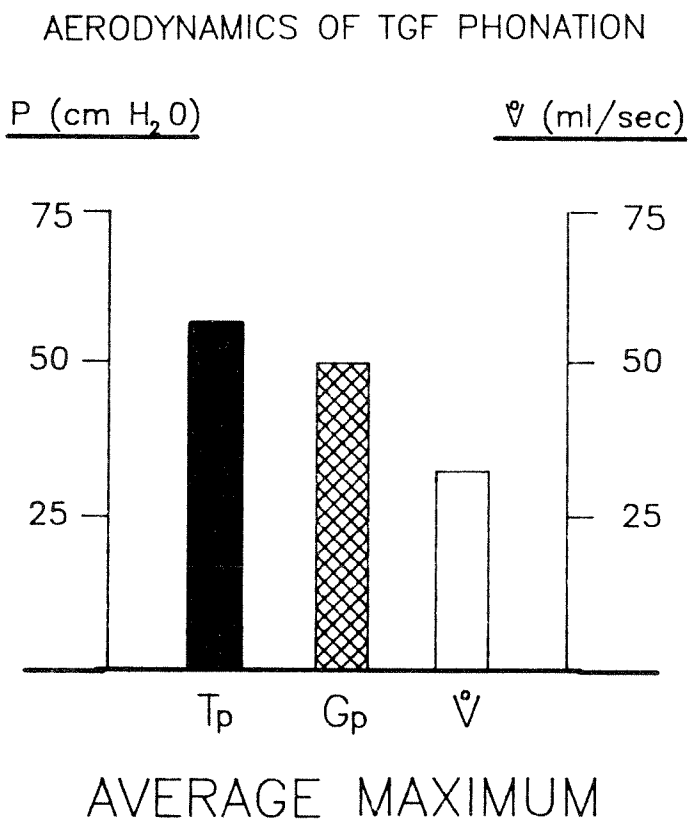

Figure 5.
Histogram of achieved maximum average gastric air pressure (P_G) and tracheal air pressure (P_T) and air-flow at the mouth during patient's own attempts to phonate. Pressure measured in cm H_2O air flow (V) in ml/sec.

gastric space needed to create vibrations. This is consistent with recent observations that the development of neoesophageal speech in gastric pull-up patients is possible if the cervical portion of the gastric pouch diminishes in size secondary to fibrosis (7). Similar to prior observations of voicing production by patients with colon transplant, in whom narrowing of colon to form pseudoglottis was observed (4,9), it is difficult to explain the action causing active gastric contraction during speech in this case. Unfortunately, poor aerodynamics of this patient imposed difficulty to generate adequate pressure differences to overcome prosthesis resistance, and to consistently vibrate the gastric mucosa. Apraxia resulted in problems with coordinating respiratory driving force and occlusion of the stoma with his finger. This combination of factors prevented him from producing voicing adequate for generating functional communication. Therefore, the voice prosthesis was removed, and the patient was provided with an oral electrolarynx. The electrolarynx speech was, however, also of poor quality due to coordination problems.

Although from a clinical standpoint this case may be considered a failure, the experience suggests that creating gastrotracheal puncture stented with a prosthesis may be encouraging for speech restoration if the patient is carefully selected. However, several basic parameters must be achieved. These include adequate air support, critical gastric space, optimal location of the fistula, proper voice prosthesis, adequate tracheal and gastric pressure difference, and the mental status of the patient. If these parameters exist, it can be assumed that phonation and speech will be achieved using the voice prosthesis approach in gastric pull-up patients with minimal postoperative risks and complications.

ACKNOWLEDGMENT

This manuscript was prepared by Ms. Debra Calogero.

REFERENCES

1. **Harrison DFN:** Surgical repair in hypopharyngeal and cervical esophageal cancer. Analysis of 162 patients. *Ann Otol* 90:372-375, 1981.

2. **Harrison DFN, Thompson AE:** Pharyngolaryngoesophagectomy with pharyngogastric anastomosis for cancer of the hypopharynx: Review of 101 operations. *Head Neck Surgery* 8:418-428, 1986.
3. **Holden H:** Personal communication, 1987.
4. **Lal M, Evison G:** Voice production following laryngo-pharyngo-esophagectomy with colon transplant. *J Laryngol Otol* 80:1208-1217, 1966.
5. **Nijdam HF, Annyas AA, Schutte HK, et al.:** A new prosthesis for voice restoration after laryngectomy. *Arch Otorhinolaryngol* 237:27-33, 1982.
6. **Salamoun W, Swartz WM, Johnson JT, et al.:** Free jejunal transfer for reconstruction of the laryngopharynx. *Otolaryngol Head Neck Surg* 96:149-150, 1987.
7. **Schechter GL, Baker JW, Gilbert DA:** Functional evaluation of pharyngoesophageal reconstructive techniques. *Arch Otolaryngol Head Neck Surg* 113:40-44, 1987.
8. **Wei WI, Lam KH, Choi S, Wong J:** Late problems after pharyngolaryngoesophagectomy and pharyngogastric anastomosis for cancer of the larynx and hypopharynx. *Am J Surg* 148:509-513, 1984.
9. **Wertz RT, Keith RL, DeSanto LW:** Speech after laryngo-esophagectomy with colon transplant. *J Speech Hear Dis* 38:495-501, 1973.