Veterans Administration

Journal of Rehabilitation Research
and Development Vol. 26 No.1
Pages 1-14

Artificial nerve graft compared to autograft in a rat model

Joseph M. Rosen, MD, Huu N. Pham, MD, Gordon Abraham, MS, Lou Harold, MD, and Vincent R. Hentz, MD
Rehabilitation Engineering Research and Development Center, Building 51, Veterans Administration Medical Center, Palo Alto, CA 94304

Abstract—A study was made to compare the regeneration of rat peroneal nerve across a 0.5 cm gap repaired with a sutured autograft (SAG) versus an artificial nerve graft (ANG). The ANG model is composed of a synthetic biodegradable passive conduit made of polyglycolic acid (PGA) and a synthetic growth medium composed of hypoallergenic collagen. Axonal regeneration in short-term animals (1 and 4 months) was evaluated by qualitative histology only, while in long-term animals (17 to 21 months) quantitative histology and electro-physiology were used in addition to qualitative histology. This study reveals that axons do regenerate through this ANG model, but electrophysiological analyses show that the axonal regeneration is statistically inferior to that in the SAG. There was no significant statistical difference in the quantitative histological data.

Key words: *artificial nerve graft, autograft, axonal regeneration, electrophysiology, histology, peroneal nerve.*

INTRODUCTION

In some traumatic nerve injuries, nerve loss results in a significant gap between the cut ends of the nerve, which cannot be closed by an end-to-end repair (36,37,40,42,44,45). The present treatment of choice is the use of an autograft to bridge the gap (40,42). Alternatives to the autografts that have been tried include homografts, heterografts, and artificial substitutes for nerve grafts (40,44,45).

One of the main interests in nerve regeneration is to develop an ideal medium for axonal regeneration (24,38,46,47). Various macromolecules, including collagen, have been analyzed and shown to have some axonotrophic effect (5,23,24,26,27,29,30,34). We are therefore interested in the effect of collagen on axonal regeneration in the artificial nerve graft.

In this experimental study, we evaluated an artificial nerve graft consisting of a polyglycolic acid[1] tube filled with a growth medium consisting of hypoallergenic collagen[2] (mainly collagen type I and some collagen type III) as a possible alternative to an autograft (**Figure 1**). The polyglycolic acid (PGA) tube provided a conduit for the intrafascicular contents of a single fascicle repair. The hypoallergenic collagen provided a temporary substitute for the intrafascicular contents.

MATERIALS AND METHODS

A total of 15 Sprague-Dawley white male rats survived the postoperative period. These animals were used to compare artificial nerve grafts to sutured autografts (**Figure 2**).

Adult rats weighing approximately 250 g each were anesthetized with intraperitoneal sodium

Address all correspondence and reprint requests to: Joseph M. Rosen, MD, Stanford University School of Medicine, Division of Plastic and Reconstructive Surgery, Rehabilitation Medicine, Stanford, CA 94305.

[1] Supplied by Davis and Geck, Pearl River, NY.

[2] Supplied by Collagen Corporation, Palo Alto, CA.

Journal of Rehabilitation Research and Development Vol. 26 No. 1 Winter 1989

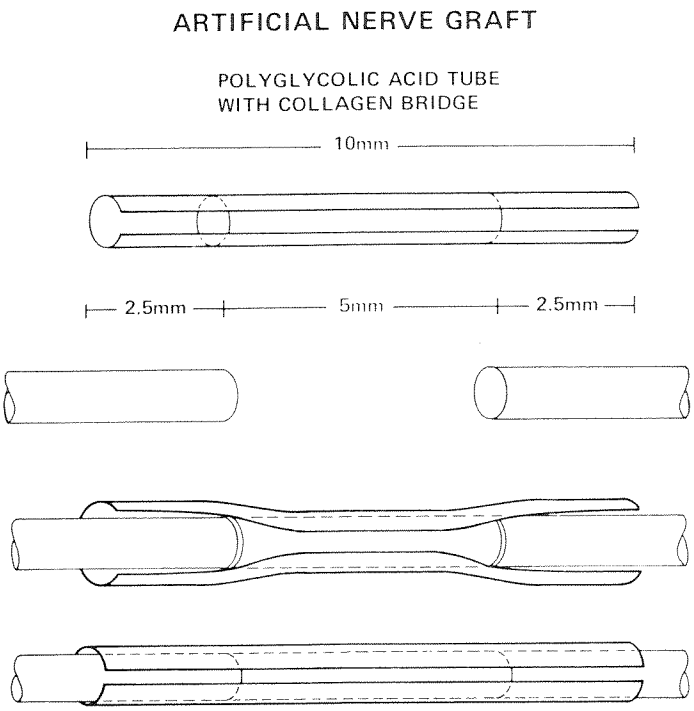

Figure 1.
Drawing of the Artificial Nerve Graft Model. The top drawing represents the polyglycolic acid tube (PGA) with the collagen bridge filling the 5 mm gap. Next drawing represents the proximal and distal ends of the transected nerve. The next two drawings show the two ends of the nerve being placed within the PGA tube. They are held in place by the blood clot (not shown) without the need of sutures.

pentobarbital. The peroneal nerve, a single fascicle (0.6 to 0.8 mm diameter) arising from the trifurcation of the sciatic nerve was used. All surgical dissections and repairs were done using the Zeiss operative microscope with 10 to 25X magnification.

In each animal, both peroneal nerves were exposed and a 0.5 cm-long segment was removed from the distal portion of each nerve. One randomized side in each animal was repaired using an autograft from the opposite peroneal nerve-removed segment. This was sutured using 10-0 nylon suture on a straight 70 micrometer diameter needle (ST-7 Ethicon). The sutures were placed through the perineurium only. The other randomized side in each animal was repaired using an artificial nerve graft (**Figure 1**). The artificial nerve grafts were composed of 10 mm-long polyglycolic acid tubes with diameters slightly larger than those of the nerves and filled with hypoallergenic collagen. Each tube was split longitudinally and the nerve pulled into it both proximally and distally for a distance of 2.5 mm. A blood clot was then placed around both ends of the PGA tube to hold the two nerve stumps, and secured within the tube without sutures being needed.

Two animals were evaluated early: one at one month and one at four months after operation. The remaining 13 animals were evaluated 17 to 21 months after operation. The early animals were evaluated by qualitative histology. The long-term animals were evaluated by quantitative histology and quantitative physiology, in addition to qualitative histology.

Qualitative histology

All nerve repair site biopsies were held at their normal length and were fixed in 3 percent cacodylate-buffered glutaraldehyde for a minimum of 24 hours. The repair zones (proximal and distal ends of graft) were imbedded in paraffin, and longitudinal sections were cut serially at 6 to 8 micrometer intervals. Half of the sections were used to evaluate the organization of the proximal and distal repair site with a Bodian stain, which stains

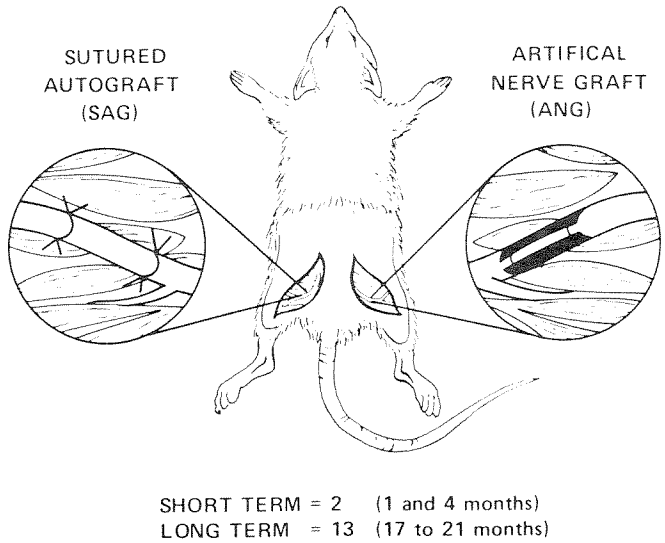

Figure 2.
Drawing of the Rat Model showing the surgical repair of the peroneal nerves with the Artificial Nerve Graft (ANG) and the Sutured Autograft (SAG). The SAG is on the left, and the ANG is on the right. There were two short-term and 13 long-term animals.

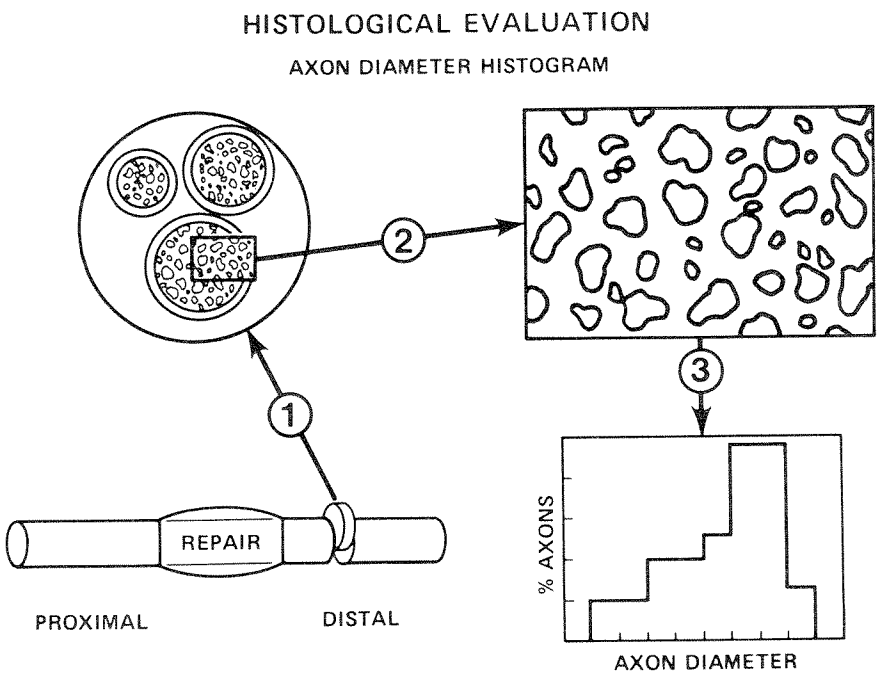

Figure 3.
Diagram of the preparation of Fiber Diameter Histogram (FDH) (see text for details).

the axons. The other half of the sections were stained with hematoxylin-eosin to assess the reaction to the surgical materials (nylon suture, polyglycolic acid tubes, and the hypoallergenic collagen within the tubes). The qualitative histological evaluations were used only as guides to the events which occurred at the repair site. The organization of the repair site was classified as failure, poor, fair, good, excellent, or normal, defined as follows:

Excellent: 90-100 percent of axons aligned;
Good: 70-90 percent aligned;
Fair: 40-69 percent aligned;
Poor: 10-39 percent aligned;
Failed: No visible alignment.

The reaction was classified based upon cellular responses as severe, moderate, or minimal (33). Because of the presence of sutures in the SAG specimens and occasional remnants of PGA in the ANG specimens, it was not possible to make the evaluation using a totally-blind method. All histologic evaluations, however, were made by our histologist to minimize bias.

Quantitative histology

Quantitative histology was used to determine the fiber diameter histogram. The average diameter of the myelinated axon population approximately 5 millimeters distal to the graft was determined from the diameter histogram (**Figure 3** and **Figure 4**) (33). The average diameter provides a measure of axonal regeneration, which is difficult to determine from axon counts because of branching (32).

Preparation of the fiber diameter histograms (FDH) was done by the following method: nerve biopsies 5 mm distal to the distal repair site of the nerve graft were taken in the final phase of the study. The biopsies were fixed in cacodylate-buffered 3 percent glutaraldehyde, followed by a second fixation in 1 percent oxmium tetroxide. The specimens were then imbedded in EPON, and 1-micrometer sections were cut on an ultramicrotome, using a glass knife. The sections were mounted on glass slides, and then stained with Toluidine Blue. Black and white negative photomicrographs of the mounted sections were then made at 450X. The negatives were projected on a scanning table, where the outlines of the axonal myelin sheaths were traced. A computer system coupled to a DEC VAX and Hewlett-Packard digitizer board then counted the axons, and calculated the area within axonal circumferences, using a planimetric algorithm to determine an average diameter. Thirty to 45 percent of each nerve was scanned, and the axon counts were extrapolated using the area algorithm to calculate the number of axons for the entire fascicle. This process is illustrated schematically in **Figure 3**.

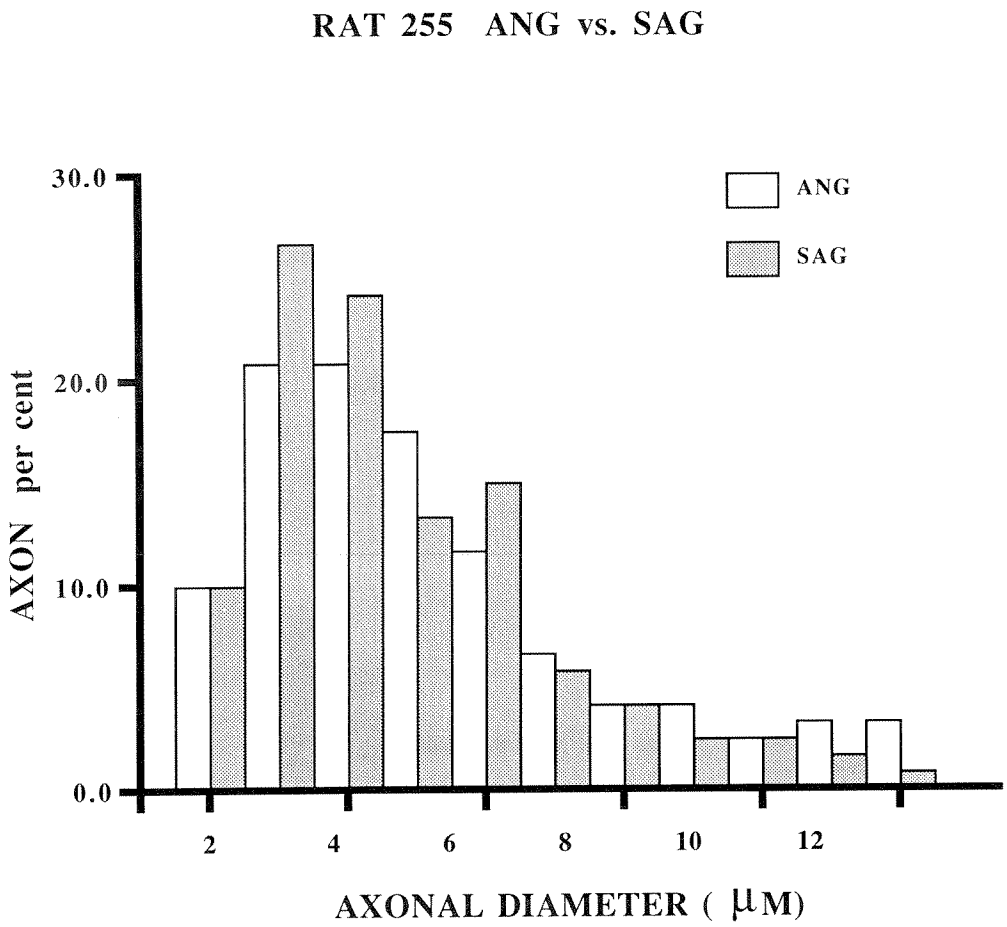

Figure 4.
Fiber Diameter Histogram of ANG and SAG in Rat 255. The vertical axis is percent of total axons. The horizontal axis is outside diameter in micrometers. Axons 1 micrometer and smaller were not included.

Quantitative physiology

Quantitative physiology provides a measure of the population of regenerated axons that have connected the proximal and distal stumps. The compound action potential was used to physiologically evaluate axon regeneration across the repair site, but does not measure the axonal regeneration to the end-organs (**Figure 5**) (41). The area under the monophasic compound action potential was determined by electronically integrating the compound action potential (31) and indicates the proportion (population) of myelinated axons with distal connections (**Figures 6** and **Figure 7**) (32).

The following method was used to obtain the integrated compound action potentials: as in the original nerve repair, the test animals were anesthetized with intraperitoneal sodium pentobarbital at 3-5 mg/100 g of body weight and constrained in a supine position. All surgery was performed under 16-25X magnification. The peroneal nerve repair site was exposed surgically, and the area was bathed in mineral oil maintained at 35 degrees Centigrade. The nerve to be tested was dissected free of surrounding connective tissue at the sciatic notch for the placement of platinum wire recording electrodes. Small areas just proximal and distal to the nerve graft site were also dissected free of connective tissue and placed on platinum wire stimulating electrodes; the repair site itself was left undisturbed (**Figure 7**).

The nerve test pulses were generated by a Grass S8 stimulator with two Model 478A stimulus isolation units. Voltage versus time characteristics of typical stimulating pulses are shown in **Figure 7**. The maximum pulse amplitude was set at 20 percent above the value needed to stimulate the total

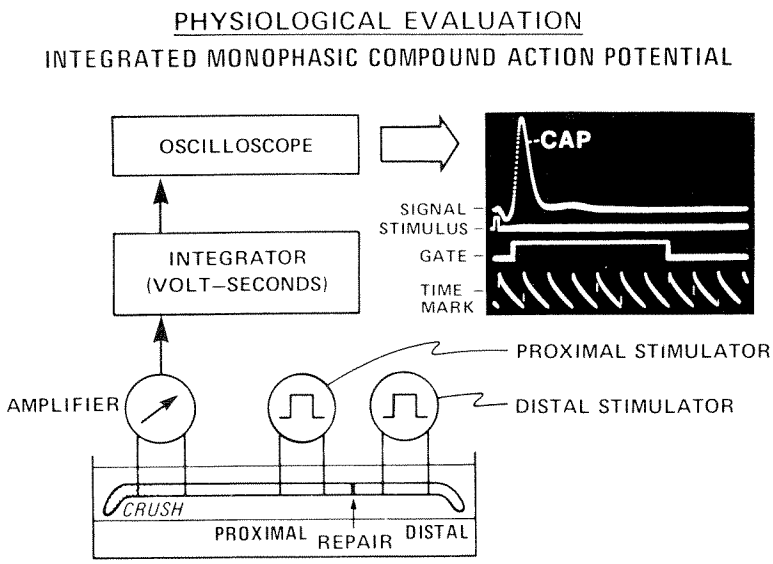

Figure 5.
Diagram of the set-up of the Electrophysiological Study (see text for details).

population of myelinated axons. The stimulator signal was amplified by a WPI amplifier with a bandpass of 0.05 Hz to 10 kHz, and then passed through a Nicolet 1170 signal-averaging system to improve the signal-to-noise ratio. The Nicolet was used to set the stimulus time windows and to integrate the signal. The data was captured on a Hewlett-Packard 7010 X-Y chart recorder.

A baseline monophasic recording of the compound action potential (CAP) was obtained by severing and crushing the nerve at the sciatic notch. The area of the CAP recorded between the proximal electrode and the recording electrode provided a measure of the total population of myelinated axons in the nerve. The area of the CAP recorded from stimulation of the distal electrode measured the proportion of myelinated axons that had reconnected across the repair site. The distal area of the CAP, divided by the proximal area of the CAP, gives the ratio of the total myelinated proximal axons with distal connections, normalized to the total proximal myelinated axon population. It is expressed as a percentage in our data.

STATISTICS

We used Wilcoxon's Signed Ranks Test (4,19) in the statistical analysis of our histological and physiological nerve graft data. This test compares two random samples from paired sequences of test data that share environments but differ in a significant procedure—in our case sutured autograft versus artificial nerve graft repair in the same animal.

The use of rank values in a significance test greatly simplifies the calculations required for a typical statistical significance t-Test. In addition, the ranking procedure is not influenced by the distribution patterns of measurements in the parent sample groups. This means that it is equally applicable to normal, logarithmic, or other data distributions.

The Signed Ranks Test depends on the assumption that if there is no significant difference between two sets of paired measurements, any chance differences between them should include approximately equal numbers of plus and minus discrepancies. Both the direction and magnitude of differences between matched pairs are taken into account, because plus or minus rank values are assigned to the various size differences. If there is no significant difference between pairs, the total plus and minus values should be about equal. The significance of inequalities between pairs is determined by specific calculations and the use of the R Table for the Wilcoxon Signed Ranks Test. The test's sensitivity can be increased to virtually the same level as that of the more complex t-Test.

Wilcoxon's Signed Ranks Test requires a minimum population of 6 pairs of measurements showing a difference, plus all individual measurements in both compared sequences to achieve a 5 percent probability level.

Journal of Rehabilitation Research and Development Vol. 26 No. 1 Winter 1989

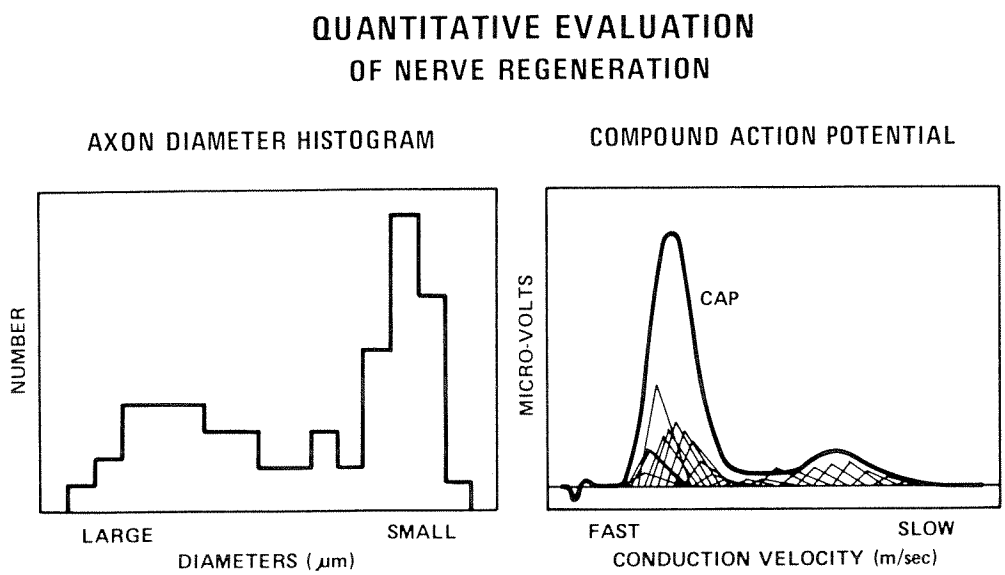

Figure 6.
Methods of quantitative evaluations: Comparison of Fiber Diameter Histogram (FDH) on the left, to Compound Action Potential (CAP) on the right. The FDH demonstrates the diameter size of the fibers in micrometers on the horizontal axis, and the number of fibers on the vertical axis. The histogram shows only the myelinated fibers. The CAP represents the total number of myelinated fibers in the nerve. The triangles within the CAP represent the single Fiber Action Potentials (FAP) that contribute to the CAP. The vertical axis is in millivolts, and the horizontal axis is in meters per second. This CAP shows the fastest fibers with the shortest latency. The FDH is reversed, so that the largest fibers are on the left, and the smallest fibers are on the right, to correspond to the CAP data (36).

RESULTS

Early evaluations (1 and 4 months)

The two early animals were evaluated by histology only. The sutured autograft repair one month after operation demonstrated axonal regeneration through both proximal and distal repair sites. The artificial nerve graft demonstrated axonal regeneration through the proximal repair site into the collagen within the graft. Within one month, the axonal regeneration had *not* reached the distal end.

The reaction to the nylon sutures was minimal in the sutured autograft. There was a moderate reaction to the polyglycolic acid tube, which was seen to be breaking up one month after operation. There was also a moderate reaction to the hypoallergenic collagen within the tube.

In the animal evaluated four months after operation, progressive axonal regeneration was observed through the sutured autograft. There was good organization of the sutured autograft repair at both the proximal and distal repair sites, with minimal reaction.

The artificial nerve graft repair had evidently failed. The distal end was separated from the artificial nerve graft. This was probably a mechanical failure of the distal repair. The distal end may have slipped out in the immediate postoperative period. The animals were not immobilized postoperatively, and only a blood clot was used to hold the artificial nerve graft in place. In the proximal repair, fair organization was observed with a moderate reaction to the remaining fragments of the polyglycolic acid tube and the hypoallergenic collagen within the tube.

Long term evaluations (17 to 21 months)

Thirteen animals were evaluated 17 to 21 months after operation by qualitative histology and quantitative histology and physiology (**Table 1**).

Qualitative histology demonstrated minimal reaction to the surgical materials (nylon suture, polyglycolic acid tubes, and hypoallergenic collagen within the tubes). In several rats (Rats 255, 257, and 265), there was a moderate cellular reaction to the remnants of the artificial nerve graft.

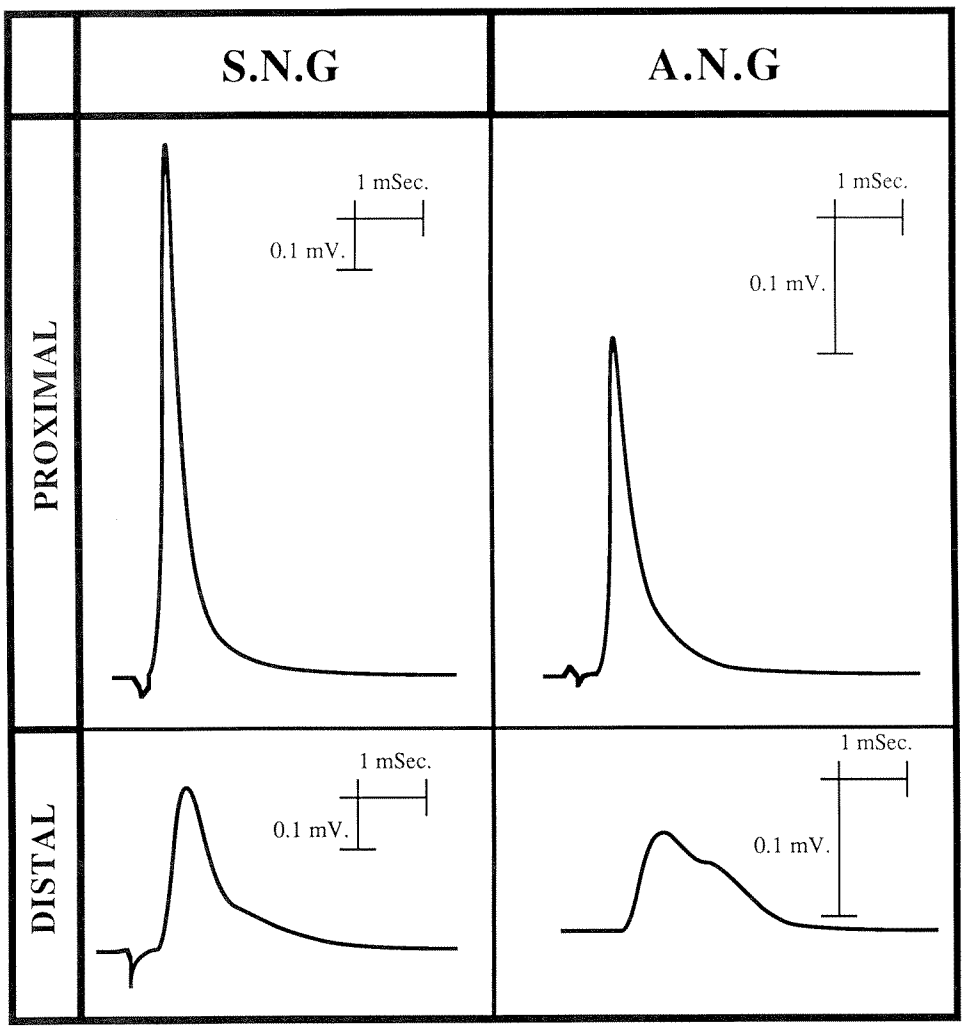

Figure 7.
Integrated monophasic CAPs in Rat 255 at the proximal and distal repair sites of the SAG and ANG. The vertical scale is in millivolts, and the scales are different for the SAG and ANG nerves. The horizontal scale is in milliseconds. The distal CAP for the ANG is delayed and spread out compared to the distal CAP for the SAG.

The organization at the proximal and distal repair sites was evaluated for all repairs (**Figure 8a** and **Figure 8b**; photomicrographs—longitudinal). The proximal repair sites of the sutured autografts had a predominantly good organization. The distal repair sites in the sutured autografts generally had good organization, although in two cases (Rats 251 and 272) the distal repair was slightly better than the proximal repair.

In a larger number of cases, the distal repair in the sutured autografts was worse than the proximal repair (Rats 255, 256, 261, and 264). In two cases, neuromas were present (Rats 255 and 256).

The organization of the repair sites in the artificial nerve graft repair was, generally, worse than that observed in the sutured autografts. There was more variability in the organization of the proximal repair sites. In general, the distal repairs had a worse organization than the proximal repairs.

In one case of ANG nerve repair (Rat 261), it was difficult to find any axonal continuity at the distal repair site. However, this case was classified as "failure?" because there were axons present in the distal myelinated axon histogram, and a physiological continuity was found across the artificial nerve graft. Rat 258 had a failed distal repair for the

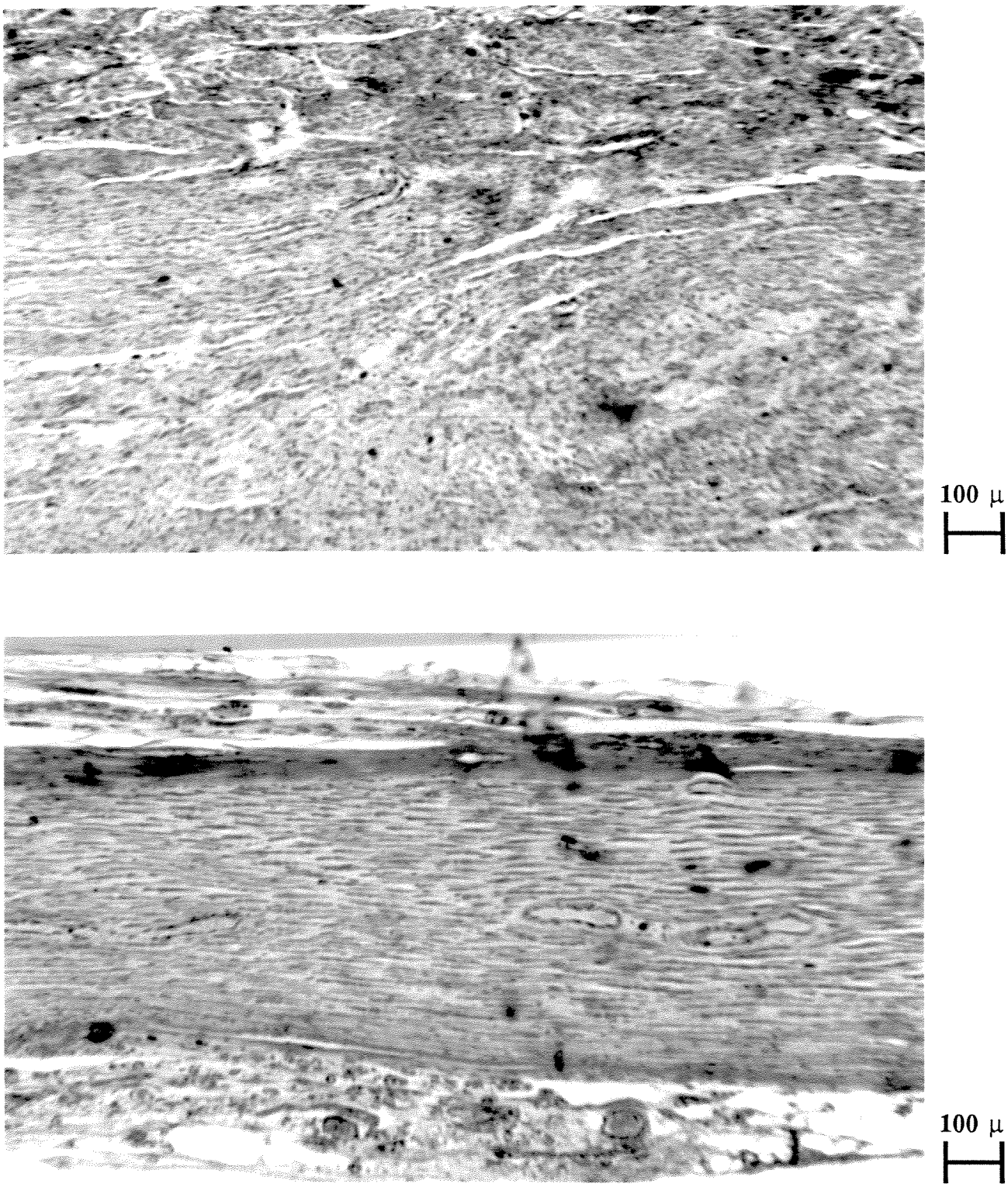

Figure 8a.
Photomicrographs of longitudinal-sections of nerve repair sites in Rat 255 at 17 months. Longitudinal-section of the proximal repair sites in the ANG (top) and in the SAG (bottom). (Stain: Bodian and Aniline blue.) Repair sites are located within the central portion of the sections shown in these photomicrographs.

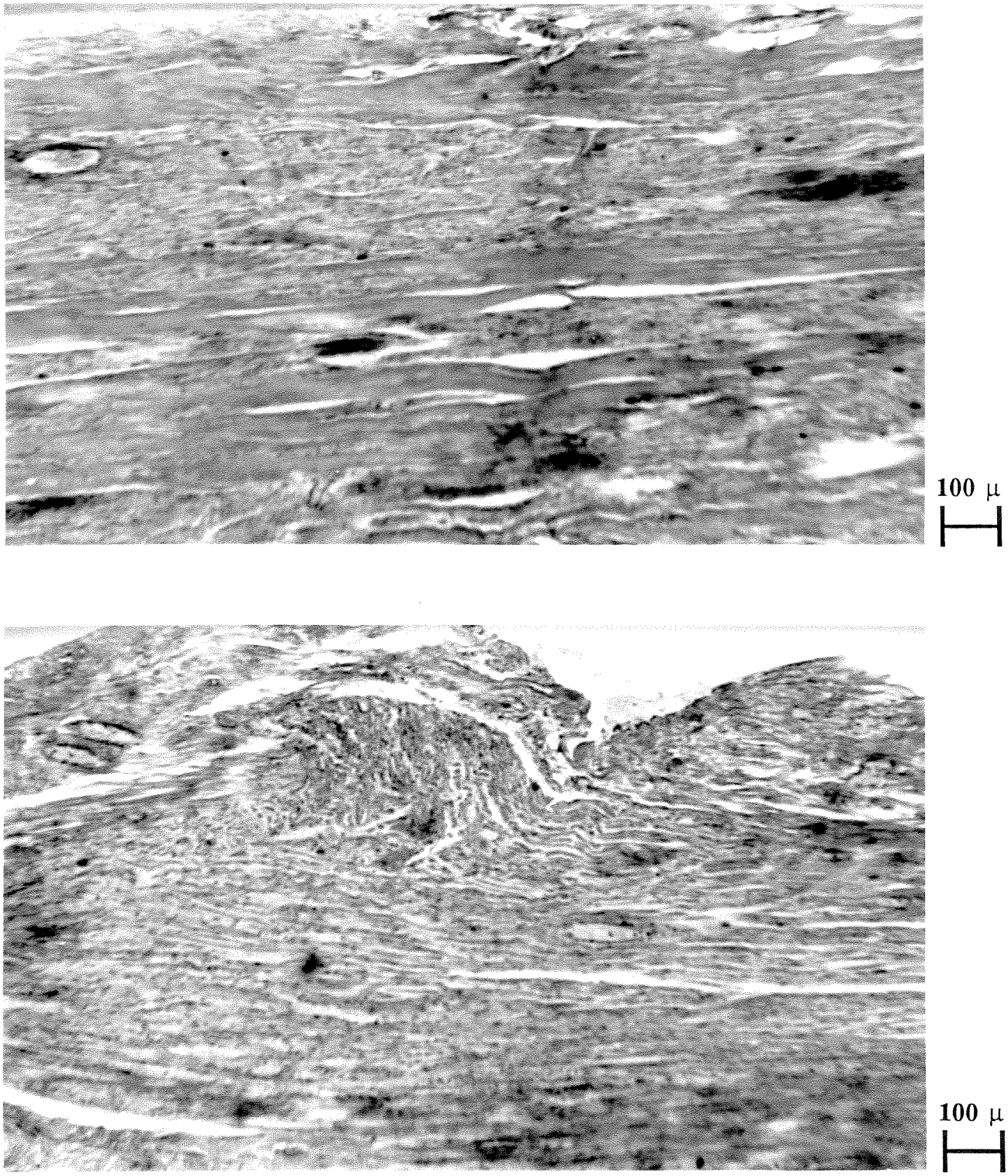

Figure 8b.
Photomicrographs of longitudinal-sections of nerve repair sites in Rat 255 at 17 months. Longitudinal-section of the distal repair sites in the ANG (top) and in the SAG (bottom). (Stain: Bodian and Aniline blue.) Repair sites are located within the central portion of the sections shown in these photomicrographs.

Journal of Rehabilitation Research and Development Vol. 26 No. 1 Winter 1989

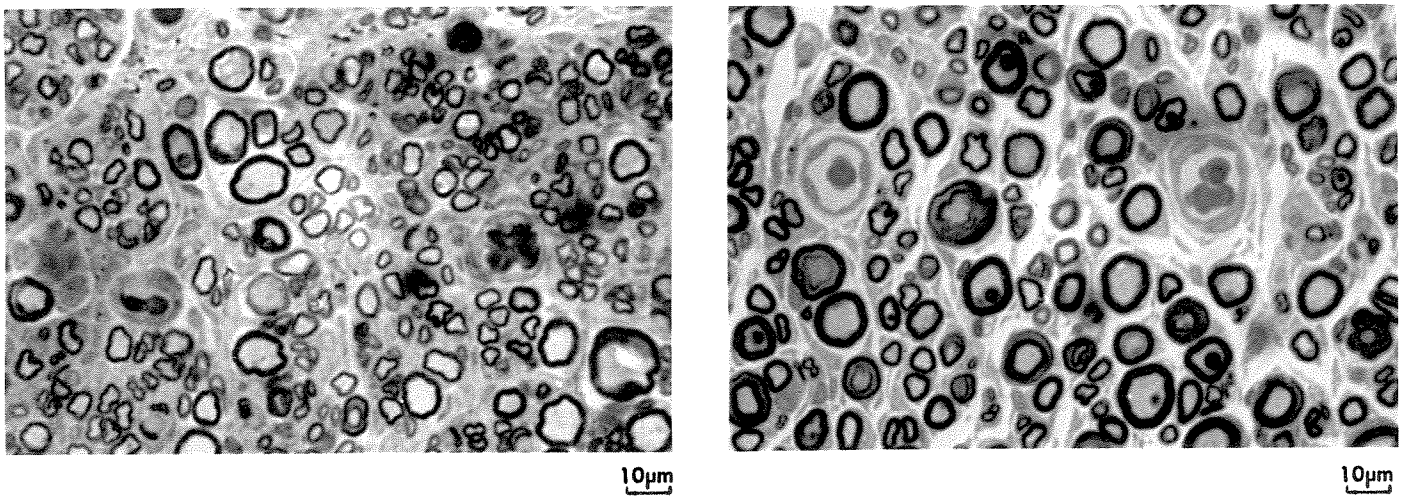

Figure 9.
Photomicrographs of cross-sections of nerve grafts in Rat 255 at 17 months. Cross-sections of the ANG (left) and the SAG (right). (Stain: Osmium and toluidine blue.) The myelin sheath is stained dark and the axon appears lightly stained within the myelin ring.

artificial nerve graft. The distal segment of this nerve had *no* axons, and, physiologically, there was *no* response across the graft.

Quantitative histology provides a measure of the regenerated myelinated axon population. In the distal nerve, the axons in the cross-section of the sutured nerve graft can be compared to those in the cross-section of artificial nerve graft (**Figure 9**). The cross-sections were used first to generate fiber diameter histograms (**Figure 3**) and then used to determine the mean myelinated axon diameter of the regenerated population (**Table 1**).

In 7 of the 13 artificial nerve grafts, it was possible to determine a histogram based on 30 percent of the population. In the other 6 repairs, it was not possible to determine a reliable histogram from the distal sections because of their poor structural organization. This was not a problem with the sutured autograft nerve repairs and in only one autograft was it impossible to determine the distal histogram, because the specimen was lost. We did not determine the distal histograms for the autografts if it was not possible to do the corresponding matched artificial nerve graft (**Table 1**).

Although these results have limitations (only 7 out of the 13 pairs is available for analysis), a statistical comparison between artificial nerve grafts and sutured autografts from quantitative histological fiber diameter histograms was done using the Wilcoxon non-parametric test. The P value for the fiber diameter histograms was $P = 0.4631$, and was not significantly different between the two groups.

Quantitative physiology was performed on all nerve repairs in the long-term animals. No response was obtained from two nerves, the artificial nerve graft in Rat 258 and the sutured autograft in Rat 261. In Rat 258, this was due to distal repair failure in the ANG, and in Rat 261 it was probably due to technical equipment problems, not problems related to the repair itself. In Rat 261, in which a sutured autograft was used, qualitative and quantitative histology demonstrated significant axonal regeneration. In the remaining 11 animals, all the sutured autografts had physiological axonal regenerations superior to those of the artificial nerve grafts. The integrated monophasic compound action potential percentage provides a measure of regeneration which serves as a comparison, but does not provide an absolute percentage of the number of axons with distal connections (see **Materials and Methods**). A statistical analysis of these results was done with the Wilcoxon non-parametric test. For matched pairs in 11 animals that had sutured autografts, which were better than the artificial nerve grafts, the difference was statistically significant ($P = 0.0033$). It should be noted that the absolute proximal response between sides varies considerably in each animal; however, the percentage of integrated monophasic compound action potential remains consistent over time (32).

Although physiologic reconnection of axons through the PGA tube with hypoallergenic collagen as a growth medium did occur, in every case the

Table 1.
Summary of Data.

Animal Number	Type of Repair	Months Post-Op	Reaction	HISTOLOGY Organization Proximal	Distal	QUANTITATIVE HISTOLOGY Mean Diameter (μm)	QUANTITATIVE PHYSIOLOGY I.M.C.A.P. (%)
Rat 251	ANG	21	Minimal	Poor/Good	Good	6.2	44
	SAG	21	Minimal	Good	Good/Exc.	6.8	79
Rat 255	ANG	17	Min./Mod.	Fair/Good	Fair	4.6	47
	SAG	17	Minimal	Good/Exc.	Good/Poor (Neuroma)	5.3	68
Rat 256	ANG	17	Minimal	Fair	Fair	N/A	38
	SAG	17	Minimal	Good	Good/Poor (Neuroma)	N/A	73
Rat 257	ANG	17	Min./Mod.	Good	Poor	N/A	25
	SAG	17	Minimal	Good	Good	N/A	81
Rat 258	ANG	18	Minimal	Good	Fail	N/A	N/A
	SAG	18	Minimal	Good	Good	N/A	75
Rat 259	ANG	19	Minimal	Fair/Poor	Poor	N/A	24
	SAG	19	Minimal	Good	Good	N/A	71
Rat 261	ANG	18	Minimal	Fair/Good	Fair	4.1	12
	SAG	18	Minimal	Good	Poor/Good	5.5	N/A
Rat 263	ANG	19	Minimal	Fair/Good	Poor	5.4	18
	SAG	19	Minimal	Good	Good	5.4	71
Rat 264	ANG	19	Moderate	Good	Poor/Fair	N/A	49
	SAG	19	Minimal	Good	Fair	N/A	66
Rat 268	ANG	19	Minimal	Fair	Fair	5.5	30
	SAG	19	Minimal	Good	Good	5.2	65
Rat 270	ANG	18	Minimal	Good	Poor	N/A	24
	SAG	18	Minimal	Good	Good	N/A	87
Rat 272	ANG	20	Minimal	Poor	Poor	6.0	28
	SAG	20	Minimal	Good	Good/Exc.	5.0	77
Rat 274	ANG	21	Minimal	Good	Good	4.8	46
	SAG	21	Minimal	Good	Fair	5.0	64

N/A = Not Available

physiologic function in artificial nerve grafts was inferior to that in the sutured autografts.

DISCUSSION

Indications for nerve grafting vary from gaps of 1 cm to over 5 cm before a graft can replace an end-to-end repair under tension (36,40,42). Where a graft is indicated, autografts are preferred at the present time (40,42). The autograft fulfills three major requirements for an ideal nerve graft: 1) it acts as a *passive* conduit for axonal regeneration; 2) it is an immunologically acceptable *natural* substitute; and, 3) it is vascularized by the recipient bed as a free graft.

The major limitation of the autografts is the requirement of a donor nerve. Homografts and heterografts have been evaluated as an alternative to autografts, but have been found to be immunologically unacceptable (44,45). The development of an artificial nerve graft is therefore necessary to solve

Journal of Rehabilitation Research and Development Vol. 26 No. 1 Winter 1989

both problems of availability and rejection by the immune system.

The interest in finding an ideal medium for axonal growth and passive devices for bridging gaps resulting from resected nerves has spanned almost a century (44). The passive devices, which have comprised a wide range of biological and non-biological materials, must fulfill the three requirements for an ideal nerve graft: 1) they must act as a conduit for axonal regeneration; 2) they must be immunologically acceptable; and, 3) they must be vascularized by the host if the regenerating axons are to have a blood supply.

In early artificial nerve grafts (11), a tube filled with blood or some plasma product was provided to span the nerve gap. In a few cases, only threads were used to span the gap with no surrounding tube (39). These attempts were all unsuccessful, whether made experimentally or clinically.

In 1944, Weiss reviewed prior studies of artificial nerve grafts. He performed experiments and demonstrated that tubes filled with blood, with or without threads as guides, successfully acted as artificial nerve grafts (44,45). These artificial nerve graft experimental studies were not tested clinically.

More recently, experiments were made with autogenous veins as passive conduits for nerve regeneration. They were found to be acceptable, but were far from being an ideal artificial nerve graft (7,8). In other studies, pseudosynovial or mesothelial tubes have been used, and moderate successes have been reported (21,22,23,24). Other authors (18) have experimented with tubes of various synthetic resorbable materials as well as collagen (10).

The introduction of PGA as a biodegradable material for various uses in tissue repair (33) is an exciting event, because PGA is a polymer which is completely hydrolyzed with minimal inflammation. PGA is therefore an ideal material for the manufacture of the guide tube of the artificial nerve graft. In one experimental study, PGA tubes filled with blood as an artificial nerve graft have been evaluated and the results were generally poor (35). In a more recent clinical study a PGA tube filled with plasma was found to provide excellent functional recovery (25). None of these studies has evaluated the material to fill the tube as a growth medium for axonal regeneration.

It is now recognized that the growing nerve fibers can both influence, and be influenced by, the cellular and extracellular components of their immediate environment. Experiments using radioactive or immunologic markers revealed that, when a segment of one nerve is grafted to transected ends of another nerve, Schwann cells in the nerve graft do survive, multiply, and eventually ensheath axons that regenerate from the proximal stump of the recipient nerve (1). Furthermore, work done using Schwann cells, grown in tissue culture and transplanted into peripheral nerves, has shown that the Schwann cells do ensheath and remyelinate axons (2,5). Schwann cells are clearly a key factor in the regeneration of the proximal stump toward the distal stump across a gap (38).

The discovery of the nerve growth factor (20) and its purification (9) have changed the long-held Wallerian theory of the nerve cell body as the trophic center that supports the distal nerve's existence, function, and regeneration. These factors, also known as neuronotrophic factors, are most often macromolecular proteins synthesized by various cell lines within the nerve (15,24). Therefore, several natural components of the peripheral nerve will probably play a crucial role in axonal regeneration, and their purification and incorporation in the growth medium will be a crucial step toward the manufacture of an ideal growth medium.

The interaction of neural processes with the surface or substratum on which they grow has been a subject of increasing interest. In Lundborg's work on regenerating nerves in pseudosynovial tubes, it is reported that the serum harvested from within the mesothelial chamber had a strong neurotrophic influence on the growing neurites in tissue culture (22,24). Furthermore, the studies suggest that if the regrowing proximal stump is placed in an appropriate environment, it can form a well-organized and oriented nerve trunk(46). Several studies have evaluated the connective tissue matrix or extracellular matrix (6,47), laminin (16,26,27,29,30,34), and fibronectin (23,29) on regenerating axons.

Work on collagen typing has revealed that there is a definite distribution of specific collagen types (28). In addition to its structural and mechanical role, collagen was also found to serve a number of "nonstructural" functions, such as in cell attachment to a substrate and in platelet aggregation (3). Procollagen type I and type III were found to be extensively codistributed with fibronectin on the surface of fibroblasts. This suggests an association

between the proteins (43). Fibronectin or cold-insoluble globulin was then found to be a requirement for optimal attachment and the spreading of many cells to a collagen substratum (13,17). In an assay using collagen bound to a solid support (either polystyrene or sepharose), collagen type III was found to be more active in binding to fibronectin than either type I or type II (12,14). Furthermore, collagen types I and III have been demonstrated in human femoral nerve (37). In addition, a histochemical study of nerve collagen has revealed that collagen type I is present in the connective tissue of the nerve sheath while collagen type III is predominantly found to be present in the endoneurium (18). Hypoallergenic collagen used in this experiment is composed primarily of collagen type I. A relatively poor axonal regeneration in this type of medium therefore indicates that collagen type I alone does not have a sufficient neurotrophic effect in the artificial nerve graft. Further study investigating the effect of other collagen types—notably collagen type III—and, in particular, different mixtures of different types of collagen on axonal regeneration in the artificial nerve graft will be an important step toward the development of an ideal growth medium for the fabrication of an ideal artificial nerve graft.

In our study, we demonstrated that hypoallergenic collagen will act as a growth medium for axonal regeneration within a polyglycolic acid tube. This artificial nerve graft is immunologically acceptable in most cases, with minimal reaction. However, the axonal regeneration, although significant, is inferior to that found in sutured autografts by electrophysiological evaluation. This artificial nerve graft model will therefore serve as a prototype for future investigation into the development of an ideal growth medium. In addition, in the future, we will investigate methods other than blood clots to secure the artificial nerve graft in place.

ACKNOWLEDGMENTS

The authors wish to thank JoAnn Kipp for her assistance with the histological preparation and evaluation of specimens; Collagen Corporation for providing hypoallergenic collagen; and Davis and Geck for providing PGA tubes.

This study was supported by the Plastic Surgery Educational Foundation Grant, NIH Grant NS 14165-05 and VA RR & D Merit Review Grant (B387-RA), and was presented at the Resident's Meeting of the Hand Society in Las Vegas, NV, in January 1985.

REFERENCES

1. **Aguayo AJ, Bray GM, Perkins CS, et al.:** Axon-sheath cell interactions in peripheral and central nervous system transplants. *Soc Neurosci Symp* 4:36, 1979.
2. **Aguayo AJ, Bunge RP, Duncan ED, et al.:** Rat Schwann cells, cultured *in vitro,* can ensheath axons regenerating in mouse nerves. *Neurology* 29:589, 1979.
3. **Bornstein P:** Structurally distinct collagen types. *Ann Rev Biochem* 49:957-1003, 1980.
4. **Brown BW, Hollander M:** *Statistics: A Biomedical Introduction,* 310-316. New York: John Wiley and Sons, 1977.
5. **Bunge RP, Bunge MB:** Evidence that contact with connective tissue matrix is required for normal interaction between Schwann cells and nerve fibers. *J Cell Biol* 78:943-950, 1978.
6. **Bunge MB, Jeffrey J, Wood P:** Different contributions of Schwann cells and fibrolasts to the collagenous components of peripheral nerves. *J Cell Biol* 78:943-950, 1977.
7. **Chiu DTW, Janecka I, Krizek TJ, et al.:** Autogenous vein graft as a conduit for nerve regeneration. *Surgery* 91:226, 1982.
8. **Chiu DTW, Lovelace RE, Yu L, et al.:** Comparative electrophysiologic evaluation of nerve grafts and vein grafts as nerve conduits. *Surg Forum* 34:601, 1983.
9. **Cohen S:** Purification and metabolic effects of a nerve growth-promoting protein from snake venom. *J Biol Chem* 234:1129, 1959.
10. **Colin W, Donoff RB:** Nerve regeneration through collagen tubes. *J Dent Res* 63:987, 1984.
11. **Edinger L:** Ueber die vereinigung getrennter nerven. Grundsaetzliches und mitteilung eines nerven verfahrens. *Munch Med Wschr* 63:225, 1910.
12. **Engvall E, Ruoslahti E, Miller EJ:** Affinity of fibronectin to collagens of different genetic types and to fibrinogen. *J Exp Med* 147:1584-1595, 1978.
13. **Grinnel F:** Cellular adhesiveness and extracellular substrata. *Int Rev Cytol* 53:65-144, 1978.
14. **Jilek F, Hormann H:** Cold-insoluble globulin (fibronectin), IV [1,35] affinity to soluble collagen of various types. *Physiol Chem* 359:247-250, 1978.
15. **Heumann R, Korsching S, Bandtlow C, Thoenen H:**

Changes of nerve growth factor synthesis in non-neuronal cells in response to sciatic nerve transection. *J Cell Biol* 104:1623-1631, 1987.

16. **Ide C, Tohyama K, Yokota R, et al.:** Schwann cell basal lamina and nerve regeneration. *Brain Res* 228:61-75, 1983.
17. **Kleinman HK, Murray JC, McGoodwin EB, et al.:** Connective tissue structure: Cell binding to collagen. *J Invest Dermatol* 71:9-11, 1978.
18. **Kline DG, Hayes GJ:** The use of a resorbable wrapper for peripheral nerve repair. *J Neurosurg* 21:737, 1964.
19. **Langley R (Ed.):** *Practical Statistics,* 179-189. New York: Dover Publications, 1971.
20. **Levi-Montalcini R, Hamburger V:** Selective growth stimulating effects of mouse sarcoma on sensory and sympathetic nervous system of the chick embryos. *J Exp Zool* 116:321, 1951.
21. **Lundborg G, Hansson HA:** Regeneration of peripheral nerve through a preformed tissue space: Preliminary observations on the reorganization of regenerating nerves fibers and perineurium. *Brain Res* 178:573, 1979.
22. **Lundborg G, Hansson HA:** Nerve regeneration through preformed pseudosynovial tubes. *J Hand Surg* 5:35, 1980.
23. **Lundborg G, Dahlin LB, Danielsen NP, et al.:** Reorganization and orientation of regenerating nerve fibers, perineurium, and epineurium in preformed mesothelial tubes: An experimental study on the sciatic nerve of rats. *J Neurosci Res* 6:265, 1981.
24. **Lundborg G, Dahlin LB, Danielsen NP, et al.:** Nerve regeneration across an extended gap: A neurobiological view of nerve repair and the possible involvement of neurotrophic factors. *J Hand Surg* 7:580, 1982.
25. **MacKinnon SE, Dellon AL:** Clinical nerve reconstruction with a bioabsorbable polyglycolic acid tube. Presented at the American Association of Plastic Surgery Meeting, May 1988.
26. **Madison R, Da Silva CF, Dikkes P, et al.:** Increased rate of peripheral nerve regeneration using bioresorbable nerve guides and a laminin-containing gel. *Exp Neurol* 88:767-772, 1985.
27. **Manthorpe M, Engvall E, Ruoslahti E, et al.:** Laminin promotes neuritic regeneration from cultured peripheral and central neurons. *J Cell Biol* 97:1882-1890, 1983.
28. **Miller EJ:** Biochemical characteristics and biological significance of the genetically distinct collagens. *Mol Cell Biochem* 13:165-192, 1976.
29. **Riggott MJ, Moody SA:** Distribution of laminin and fibronectin along peripheral trigeminal axon pathways in the developing chick. *J Comp Neurol* 258:580-596, 1987.
30. **Rogers SL, Letourneau PC, Palm SC, et al.:** Neurite extension by peripheral and central nervous system neurons in response to substratum bound fibronectin and laminin. *Dev Biol* 98:212-220, 1983.
31. **Rosen JM, Kaplan EN, Jewett DL, et al.:** Fascicular sutureless and suture repair of the peripheral nerves: A comparison study in laboratory animals. *Orthop Rev* 8:85, 1979.
32. **Rosen JM, Jewett DL:** Physiological methods of evaluating experimental nerve repair. In *Nerve Repair and Regeneration: Its Clinical and Experimental Basis,* D.L. Jewett, et al. (Eds.), 150. St. Louis: C.V. Mosby, 1980.
33. **Rosen JM, Hentz VR, Kaplan EN:** Fascicular tubulization: A cellular approach to peripheral nerve repair. *Ann Plast Surg* 11:397, 1983.
34. **Sanes JR:** Laminin for axonal guidance? *Nature* 315:714-715, 1985.
35. **Seckel BR, Chiu TH, Nyilas E, et al.:** Nerve regeneration through synthetic biodegradable nerve guides: Regulation by the target organ. *Plast Reconstr Surg* 70:251, 1984.
36. **Seddon HJ:** *Surgical Disorders of Peripheral Nerve.* Edinburgh: Churchill Livingstone, 1975.
37. **Seyer JM, Kang AH, Whitaker JN:** The characterization of type I and III of collagens from human peripheral nerve. *Biochem Biophys Acta* 492:415-425, 1977.
38. **Shine D, Harcourt PG, Sidman RL:** Cultured peripheral nervous system cells support peripheral nerve regeneration through tubes in the absence of distal nerve stump. *J Neurosci Res* 14:393-401, 1985.
39. **Stopford JSB:** The treatment of large defects in peripheral nerve injuries. *Lancet* 2:16, 1920.
40. **Sunderland S:** Nerves and Nerve Injuries, Edinburgh: Churchill Livingstone, 1978.
41. **Terzis JK, Dykes RW, Hakstian RW:** Electrophysiological recordings in peripheral nerve surgery: A review. *J Hand Surg* 1:52, 1976.
42. **Terzis JK:** Principles and techniques of peripheral nerve surgery. In *Reconstructive Microsurgery,* R.K. Daniel, et al. (Eds.), 137. Boston: Little Brown, 1977.
43. **Vaheri A, Kurkinen M, Lehto VP, Linder E, Timpl R:** Codistribution of pericellular matrix proteins in cultured fibroblasts and loss in transformation: Fibronectin and procollagen. *Proc Natl Acad Sci, USA* 75:4944-4948, 1978.
44. **Weiss PA:** The technology of nerve regeneration: A review. Sutureless tubulation and relayed methods of nerve repair. *J Neurosurg* 1:315-365, 1944.
45. **Weiss PA, Taylor AC:** Guides for nerve regeneration across gaps. *J Neurosurg* 3:375-389, 1946.
46. **Williams LR, Longo FM, Powell HC:** Spatial-temporal progress of peripheral nerve regeneration within a silicone chamber: Parameters for a bioassay. *J Comp Neurol* 218:460-470, 1983.
47. **Williams LR, Varon S:** Modification of fibrin matrix formation *in situ* enhances nerve regeneration in silicone chambers. *J Comp Neurol* 231:209-220, 1985.