Department of Veterans Affairs

Journal of Rehabilitation Research and Development Vol. 35 No. 1, January 1998
Pages 85–90

CLINICAL REPORT

Sensory Changes in Adults with Unilateral Transtibial Amputation

Judith B. Kosasih, MD and M. Barbara Silver-Thorn, PhD
Department of Physical Medicine and Rehabilitation, Medical College of Wisconsin, Milwaukee, WI 53226; Department of Veterans Affairs Medical Center, Milwaukee, WI 53295; Marquette University, Department of Biomedical Engineering, Milwaukee, WI 53201

Abstract—The purpose of this study was to describe the sensory changes in adults with unilateral transtibial amputation (TTA), as any loss of sensation may have significant impact on the successful use of a prosthesis. Sensory modalities of light touch, deep pressure, vibration, and superficial pain (pinprick) were examined on the residual and contralateral limbs of 16 veterans with TTA. Six subjects demonstrated normal sensation on the contralateral limb and impaired sensation of superficial pain, vibration, and/or light touch on the residual limb. Superficial pain was the most frequently impaired sensation, and vibration and superficial pain sensation appeared to be age-dependent, with increased impairment observed in the elderly. Deep pressure sensation was intact in all subjects. These preliminary data suggest that although neither the amputation nor the prosthetic rehabilitation resulted in impaired deep pressure sensation, these two factors contributed to minimal impairment of light touch and vibration, and significant impairment of the superficial pain sensation.

Key words: *amputation, sensation, sensory disorders.*

This material is based upon work supported by the Department of Veterans Affairs, Rehabilitation Research and Development Service, Washington, DC 20420.
Address all correspondence and requests for reprints to: J.B. Kosasih, MD, VA Medical Center, Physical Medicine and Rehabilitation (117), 5000 West National Avenue, Milwaukee, WI 53295.

INTRODUCTION

The soft tissues of the residual limbs of individuals with transtibial amputation (TTA) are subjected to significant loading that would otherwise be supported by the feet. If such an individual fails to perceive sensory cues about the status of the residual limb and its interface with the prosthetic socket, skin breakdown and pressure sores may result. Many investigators have described sensory changes (i.e., changes in light touch, pinprick, deep pressure, vibration, and temperature perception) that occur in the lower limb associated with various disease processes and aging (1–3). However, the description of concomitant sensory changes, which occur in the well-healed residual limb subsequent to TTA with or without prosthetic rehabilitation, is lacking. Haber studied the sensory changes of individuals with unilateral transhumeral amputation, and noted that sensation (point localization, two-point discrimination, and light touch) of the residual limb was actually heightened subsequent to amputation, that is, it was more sensitive than the contralateral limb (4). The authors did not discuss whether the subjects were active prosthesis users. As the tissues of the lower limb differ from those of the upper limb, and the loading of these tissues differs significantly for prosthetic users, such results may not be readily extrapolated to individuals with lower limb amputation. The nature and the extent of the loss of sensation in the lower residual limb

remains to be determined. Loss of sensation may have significant impact on prosthetic fit and comfort, the tolerance of the subject to weightbearing in the socket, and the need for redistribution of pressure areas in the socket to prevent skin breakdown and pressure sores.

The objective of this pilot study was to conduct sensory examinations of light touch, pressure, pinprick, and vibration on the residual and contralateral limbs of individuals with TTA, in order to compare characteristics of sensory loss in traumatic and vascular and young and elderly subjects. Improved understanding of the sensitivity of the residual limb soft tissues may help to improve prosthetic socket design and socket fit, and minimize the risk of dermatological damage of the tissues subsequent to prosthetic use.

METHODS

The Milwaukee Department of Veterans Affairs Medical Center Regional Prosthetic Clinic records for the past 2 years were reviewed to identify potential research subjects. All subjects with sound residual limbs, who had no prior or current history of dermatological problems, and who were stable in their prosthetic rehabilitation (i.e., stable residual limb volume and ambulatory in a definitive prosthesis), were included in this study. Subjects were excluded who had bilateral lower limb amputations, open wounds, or neurologic disorders (including stroke, Parkinson's disease, Alzheimer's disease, or language/cognitive deficits). For inclusion in this study, subjects provided written informed consent and were cooperative and mentally alert.

Clinical examinations of the residual and contralateral limbs of 16 male veterans with TTA were conducted by the same physician to determine the ability of each subject to discern light touch, deep pressure, vibration, and pinprick. Subjects of various etiology (traumatic, vascular, and cancer), as well as young and elderly individuals, were examined (see **Table 1**). The results of these examinations were used to determine what impairments existed, the extent of the impairments, and the possible influence of age, etiology, and time postamputation in the findings.

Prior to initiating the sensory examination, a brief medical/surgical history was taken, the procedure was explained to the subject, and the stimuli to be applied were demonstrated. All sensory testing was conducted in a random order; the subject's eyes were closed during testing. Bilateral sensory examinations of lower limbs were conducted in a standard manner (5,6). The stimuli included light touch, deep pressure, vibration, and pinprick. For all stimuli, the regions tested included pressure-tolerant (patellar tendon, popliteal, medial and lateral tibial flares) and pressure-sensitive (fibular head, anterior tibial crest) areas of the residual limb (7), in addition to the distal end and the incision site. Comparative areas, excluding the distal end and the incision site, were examined for the contralateral limb. The subjects were seated throughout testing; the contralateral foot was flat on the floor, and the residual limb was relaxed with approximately 85° of knee flexion. The test duration for the sensory examination, including the medical history, was approximately 20 minutes. The sensory examination consisted of four parts:

Table 1.
Summary of subject statistics (mean ± standard deviation).

Etiology	# Subjects	Age, years	Time Post-Amputation, years
Vascular	4	64.0 ± 11.3	2.5 ± 2.4
Traumatic	11	55.4 ± 12.3	23.4 ± 14.9
Other	1	51	23

1. *Light touch:* a wisp of cotton swab was lightly applied to the limb surface. The subject responded "yes" when the stimulus was detected.
2. *Deep pressure:* the physician pressed firmly on the skin with his thumb.
3. *Vibration:* a magnesium alloy tuning fork (128 Hz) was struck against the examiner's hand and applied to the limb surface at the bony prominences of the fibular head, the patella, and the distal anterior tibial crest. The distal anterior tibial crest site on the contralateral limb was located at approximately the same level as on the residual limb. The subject was asked whether the tuning fork was vibrating ("buzzing") or just touching ("no"). The length of time that the vibration was discernible to the subject was noted, as was whether the fork was still vibrating when applied to the contralateral limb.
4. *Pinprick:* the sharp and dull ends of a safety pin were lightly pressed against the limb tissues at the specific test locations. The subject responded "sharp" or "dull" when the respective stimulus was detected.

During testing, care was taken to ascertain the extent of asymmetry between sensory responses of the two limbs. Only subjects who demonstrated normal sensation of the intact contralateral limb were included in the data analysis, so that the soft tissue sensation of the residual limb subsequent to amputation and prosthetic usage could be assessed.

RESULTS

Nine of the 16 subjects demonstrated normal sensation of the contralateral limb. The sensory impairment of the intact contralateral limb in the remaining subjects signified the lack of an individual "norm." Identification of sensory deficits subsequent to amputation and prosthetic usage would therefore be difficult to assess. Thus, those subjects demonstrating impaired sensation of the contralateral limb, (i.e., all subjects with amputation due to vascular causes and three individuals with traumatic amputation) were excluded from further investigation. Impairments in contralateral limb sensation were believed to be due to various reasons, including bilateral lower limb trauma, diabetic polyneuropathy, and/or prior cardiac bypass surgery with grafts on the contralateral limb. For 13 subjects, the sensory modalities of superficial pain (pinprick), vibration and/or light touch of the residual limb were either impaired or absent, while the deep pressure sensation remained intact (**Figure 1** and **Table 2**).

The sensory impairment of the residual limb for the nine subjects demonstrating intact sensation of the contralateral limb is summarized in **Table 3.** The results indicate that pinprick sensibility was the most common impairment observed for this population (67 percent); this impairment was observed at both pressure-tolerant and pressure-sensitive regions and typically involved the distal end and/or the incision site of the limb, the patellar tendon, the anterior tibial crest, and the medial and lateral tibial flares. Deep pressure sensation was consistently intact. Sensation of light touch and vibration were only minimally affected. Specifically, the impairment of light touch was generally observed over the distal end and/or the incision site of the residual limb, the patellar tendon, and the lateral tibia areas. Vibration, if impaired, involved all of the tested bony prominences.

The results of further analysis investigating the symmetry of lower limb sensation are summarized in **Table 2** and **Figure 1.** Conclusions regarding the effects

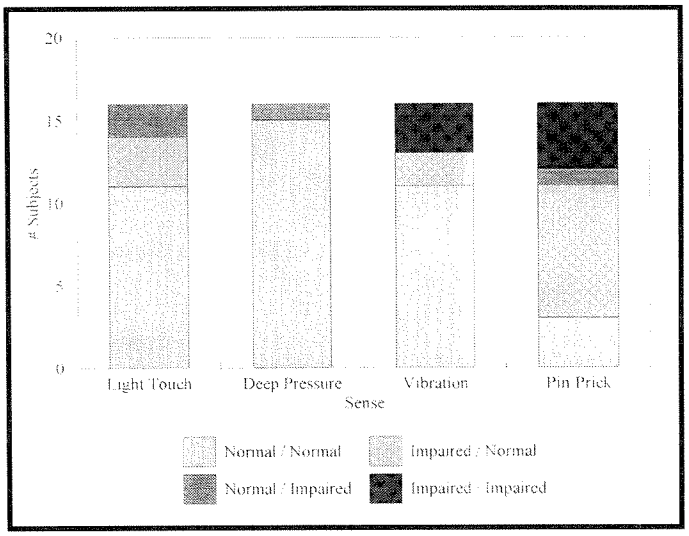

Figure 1.
Summary of the symmetry/asymmetry of the sensation of the entire residual limb versus that of the overall contralateral limb for each of the four applied stimuli: light touch, deep pressure, vibration, and pinprick (n=16). Normal/Impaired refers to normal sensation of the residual limb and impaired sensation of the contralateral limb; Impaired/Normal indicates asymmetric behavior in which the sensation of the residual limb is impaired and that of the contralateral limb is normal.

of amputation etiology are inclusive, as none of the vascular subjects demonstrated normal sensation of the contralateral limb, and only a single subject had an amputation due to a nonvascular disease. To investigate limb sensibility as a function of subject age, three age groups were defined. Subjects younger than 45 years were considered young, those between 46 and 59 years were considered middle aged, and those older than 60 years were considered elderly. The incidence of impairment of vibration and pinprick sensibility was greatest for the elderly subjects. Finally, when analyzing the data as a function of the time postamputation, sensory impairments, primarily the superficial pain sensation, were most common in subjects who had amputation for more than 20 years.

DISCUSSION

The purpose of this study was to develop a broader understanding of characteristics of sensory loss as related to etiology and age of men with TTA. Of particular concern was the potential loss of deep pressure sensation. Intact deep pressure sense is neces-

Table 2.
Summary of subject sensory data for the entire residual and contralateral limbs (i.e., inclusive of pressure tolerant and pressure sensitive regions).

				RESIDUAL LIMB					CONTRA LIMB				
Subject #	Age (years)	Cause of Amp	Years Post Amp	Light Touch	Deep Pressure	Vibra-tion	Pin Prick	Total Sensory Score	Light Touch	Deep Pressure	Vibra-tion	Pin Prick	Total Sensory Score
1	48	Trauma	28	0	0	0	2	2	0	0	0	0	0
2	43	Trauma	24	0	0	0	0	0	0	0	0	0	0
3	63	Trauma	43	0	0	0	1	1	0	0	0	0	0
4	47	Trauma	26	1	0	0	1	2	0	0	0	0	0
*5	40	Trauma	5	0	0	0	1	1	1	0	0	1	2
6	53	Trauma	30	0	0	0	2	2	0	0	0	0	0
7	47	Trauma	26	0	0	0	0	0	0	0	0	0	0
8	72	Trauma	9	0	0	0	2	2	0	0	0	0	0
*9	69	Trauma	12	1	0	0	2	3	0	1	0	1	2
10	75	Trauma	50	0	0	1	1	2	0	0	0	0	0
*11	52	Trauma	4	0	0	0	2	2	0	0	0	1	1
*12	56	Vascular	1	0	0	1	2	3	1	0	1	2	4
*13	56	Vascular	1	2	0	1	1	4	0	0	1	0	1
*14	80	Vascular	6	0	0	1	2	3	0	0	1	0	1
*15	64	Vascular	2	0	0	1	0	1	0	0	0	2	2
16	51	Other	23	0	0	0	0	0	0	0	0	0	0

Scoring of sensory impairments: 0 = normal sensation; 1 = heightened, impaired, or absent sensation in either the pressure tolerant or pressure sensitive regions of the lower limb; 2 = heightened, impaired, or absent sensation in both the pressure tolerant and pressure sensitive regions of the lower limb; Amp = amputation. Total scores range from 0 to 8. Subjects identified with an asterisk demonstrated impaired sensation of the contralateral limb and were therefore not included in subsequent data analysis.

Table 3.
Summary of sensory impairments for the overall residual limb (i.e., pressure-tolerant and pressure-sensitive regions) for subjects, n = 9, demonstrating intact sensation of the contralateral limb.

	Light Touch	Deep Pressure	Vibration	Pin Prick
Overall Population, N = 9	11%	0%	11%	67%
Trauma, N = 8	13%	0%	13%	75%
Vascular, N = 0	n/a	n/a	n/a	n/a
Other Causes, N = 1	0%	0%	0%	0%
Young (<45 y), N = 1	0%	0%	0%	0%
Middle Aged, (46–59 y), N = 5	20%	0%	0%	60%
Elderly (60+ y), N = 3	0%	0%	33%	100%
0–10 years Post Amputation, N = 1	0%	0%	0%	100%
11–20 years Post Amputation, N = 0	n/a	n/a	n/a	n/a
21+ years Post Amputation, N = 8	13%	0%	13%	75%

sary for the detection of excessive and/or prolonged loading before tissue degradation occurs due to local ischemia and inflammation (8,9).

The results of this pilot study indicate that there is no impairment of deep pressure, minor impairment of light touch and vibration, and significant impairment of pinprick sensitivity of the residual limb for those subjects demonstrating intact sensation of their contralateral limb. The light touch and pinprick sensibility, which may occur at pressure tolerant and/or pressure sensitive regions, may be reduced due to soft tissue desensitization and residual limb conditioning during prosthetic rehabilitation, and/or callus formation from prosthetic usage. Callus formation is a common skin adaptive response, increasing load tolerance to repeated frictional loading (9).

The results also indicate that the vibratory and pinprick sensation are age-dependent, with impairment more likely in elderly subjects. This is consistent with prior studies involving individuals without lower limb amputation (2,10). This literature also states that impairments in vibratory sense are typically bilateral (i.e., symmetric), and that the vibratory sense may be entirely absent in elderly individuals.

The intact deep pressure sensation for individuals with either traumatic or vascular amputation was somewhat encouraging, as impairment to deep pressure sensibility was believed to be a significant risk factor for tissue degradation. However, the observed impaired pinprick sensibility indicates that these subjects may unknowingly submit their tissues to repeated trauma from superficial mechanical sources, which may result in skin ulceration (11).

Impairment in pinprick sensibility may also indicate an impairment in temperature perception, another superficial sensation. Thus, future studies should include the examination of temperature perception of the residual limb, as pressure sore etiology includes extrinsic factors, such as the presence of abnormally high temperatures and moisture accumulation at the loading area of the skin (12).

Despite efforts to include subjects with traumatic and vascular amputation in equal numbers, the available veteran population and the subject selection criterion did not support this endeavor. Although the relatively small subject sample does not justify statistical analysis and definitive conclusions, the preliminary data indicate specific trends in residual limb sensibility.

To obtain more quantitative results, the vibration perception threshold may be evaluated using a vibrometer or Bio-Thesiometer (13). Also, as sensory impairments involved light touch but not deep pressure, more specific investigation of pressure sensibility should be investigated using Semmes-Weinstein monofilaments. This methodology has been shown to produce a controlled, reproducible force stimulus for use in clinical testing (14). In addition, the location of the amputation scar should be noted, as the cutaneous sensation is likely to be dependent on nerve severance and division.

CONCLUSION

These preliminary data suggest that TTA, prosthetic rehabilitation with or without continued use of a prosthesis, does not impair the deep pressure sensation, minimally impairs the light touch and vibration sensibility, and significantly impairs the superficial pain sensation of the residual limbs. More extensive examination of sensory changes in individuals with TTA is needed. In addition to testing the sensory perception of deep pressure, light touch, vibration, and pinprick, temperature perception should also be investigated.

ACKNOWLEDGMENTS

The authors would like to acknowledge Barbara M. Myklebust, PhD, who was instrumental in the conception of this research study.

REFERENCES

1. Dyck PJ, Bushek W, Spring EM, et al. Vibratory and cooling detection thresholds compared with other tests in diagnosing and staging diabetic neuropathy. Diabetes Care 1987;10:432–40.
2. Dyck PJ, Karnes J, O'Brien PC. Detection thresholds of cutaneous sensation. In: Dyck PJ, Thomas PK, Asbury AK, Winegrad AI, Porte D, editors. Diabetic neuropathy. Philadelphia: Saunders; 1987. p. 107–21.
3. Adams RD, Victor M. Principles of neurology. 4th ed. New York: McGraw-Hill, Inc.; 1989.
4. Haber WB. Effects of loss of limb on sensory functions. J Psychol 1955;60:115–21.
5. Haerer AF. DeJong's: the neurologic examination. 5th ed. Philadelphia: J.B. Lippincott Company; 1992.
6. Dale AJD. The sensory examination. In: Dale AJD, Kokmen E, Swanson JW, Weibers DO, editors. Clinical examinations

in neurology. 6th ed. St. Louis: Mayo Clinic and Mayo Foundation, Mosby Year Book, Inc.; 1991. p. 255–75.

7. Rae JW, Cockrell JL. Interface pressure and stress distribution in prosthetic fitting. BPR 1971;10-16:64–111.
8. Kosiak M. Etiology and pathology of ischemic ulcers. Arch Phys Med Rehabil 1959;40:62–9.
9. Sanders JE, Goldstein BS, Leotta DF. Skin response to mechanical stress: adaptation rather than breakdown—a review of the literature. J Rehabil Res Dev 1995;32(3):214–26.
10. Bleecker ML. Quantifying sensory loss in peripheral neuropathies. Neurobehav Tox Teratol 1985;7:305–8.
11. Tredwell JL. Pathophysiology of tissue breakdown in the diabetic foot. In: Kominsky SJ, editor. Medical and surgical management of the diabetic foot. St. Louis: Mosby; 1994. p. 93–114.
12. Barbenel JC. Pressure management. Prosthet Orthot Int 1991;15:225–31.
13. Liniger C, Albeanu A, Bloise D, Assal J. The tuning fork revisited. Diabet Med 1990;7:859–64.
14. Bell-Krotoski J, Tomancik E. The repeatability of testing with Semmes-Weinstein monofilaments. J Hand Surg 1987; 12A(1):155–61.

Submitted for publication March 18, 1996. Accepted in revised form July 26, 1996.