Department of Veterans Affairs

Journal of Rehabilitation Research and Development Vol. 26 No. 3
Pages 63–76

Sutureless nerve repair at the fascicular level using a nerve coupler

Deirdre M. Marshall, MD; Morton Grosser, PhD; Michael C. Stephanides; Robert D. Keeley; Joseph M. Rosen, MD
Stanford University School of Medicine, Div. of Plastic and Reconstructive Surgery, Stanford, CA 94305

Abstract—Peripheral nerves are transected in many traumatic injuries of the extremities. Satisfactory functional regeneration of such nerves often fails to occur after repair with sutures. Possible reasons for these failures include poor alignment of nerves or fascicles, intrusion of scar tissue into the nerve junction, and outgrowth of nerve tissue from the repair site. This animal study describes an experimental method of sutureless, monofascicular peripheral nerve repair using a resorbable nerve coupler in the rat model. The first version of this coupler shows approximately equal performance to suture repair. Histology and electrophysiology assessments after regeneration showed that the polyglycolic acid (PGA) tube repairs were functionally equal to monofascicular suture junctions as well as being quicker and simpler to perform. Modified coupler designs based on this and other work show greater promise. Collateral studies are using similar versions of the nerve coupler as a vehicle for the insertion of chemical and neuro-electronic factors that may enhance nerve regeneration.

Key words: *histology and electrophysiology assessments, nerve injury, nerve regeneration, polyglycolic acid tube, sutureless nerve repair.*

INTRODUCTION

The goal of transected nerve repair has been to re-establish the continuity of the multiple layers of nervous tissue (**Figure 1**) (31). Both suture and sutureless techniques have been used to join whole nerves (epineural repair), and components of nerves (perineurial, group perineural, or interfascicular repair). The most common current method of repairs is by epineural suture. Each of these methods is described below.

Address all correspondence and requests for reprints to: Deirdre M. Marshall, MD, Stanford University School of Medicine, Division of Plastic and Reconstructive Surgery, Stanford, CA 94305.

SUTURE REPAIR BACKGROUND

Epineural

In this technique, sutures are used to join the outermost (epineural) layer of the nerve sheath. The nerve ends are approximated, and it is sometimes possible to match linear markings so that the sheath is aligned axially and rotationally (**Figure 2a**). However, such visual alignment is crude compared with the scale of the internal nerve structure, and fascicular coaptation is often poor (1,17,32). Internal gaps, overlapping, buckling, and straddling of fascicles may all reduce the number of axons that regenerate across the junction. Epineural sutures do not prevent ingrowth of scar tissue or outgrowth of nerve tissue from the repair site, and many such repairs have been unsatisfactory except in children (9,17,20).

Perineurial

Advances in microsurgical technique over the past twenty years have permitted the development of fascicular nerve repair with sutures (**Figure 2b, 2c**).

Journal of Rehabilitation Research and Development Vol. 26 No. 3 Summer 1989

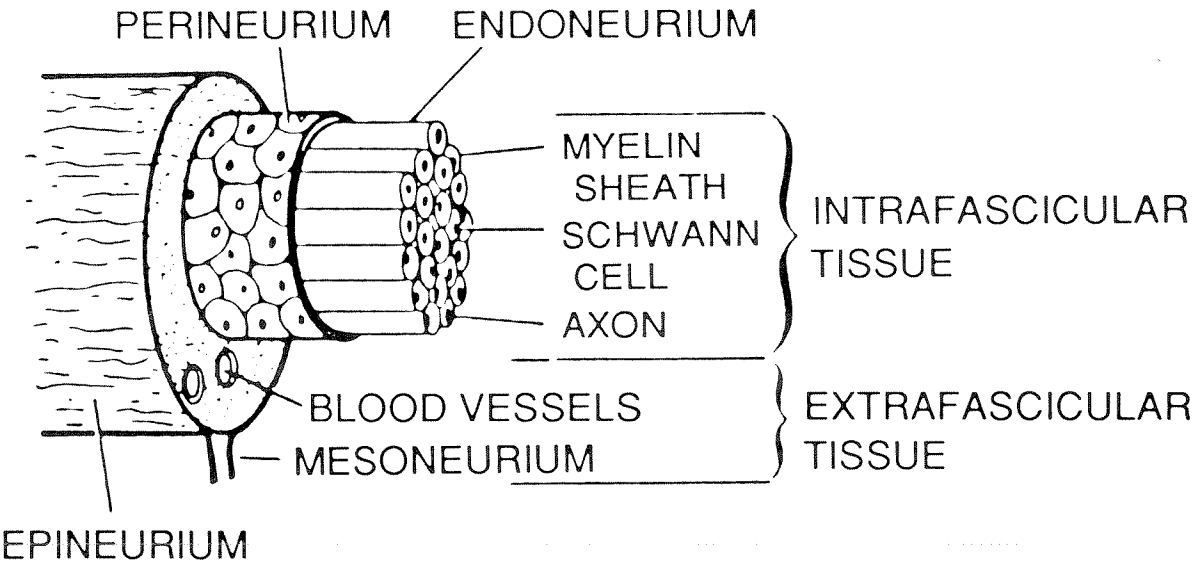

Figure 1.
Cellular schematic of peripheral nerve trunk. Intrafascicular tissue = endoneurium, Schwann cells, and myelin-axon complexes. Extrafascicular tissue = epineurium and mesoneurium. Perineurium lies at junction of intrafascicular and extrafascicular tissues.

In this technique, fascicles or small groups of fascicles are captured together. The expectation was that more precise alignment of fascicles would allow more axons to regenerate into the correct endoneurial tubes distal to the repair site (18,19,25). However, clinical trials have not shown perineurial suture repairs to improve functional regeneration relative to epineural repair (13,15,26,34). Similarly, experimental studies have not found any advantage of perineurial suture repair over epineural suture repair (25,26).

It may be that while perineurial repair is promising in theory, the complication of the technique offsets any putative benefits. Fascicular sutures increase the trauma to the perineurium and the intrafascicular tissues, and a perineurial suture repair is just as susceptible as an epineural repair to scar tissue intrusion and nerve tissue escape.

SUTURELESS REPAIR BACKGROUND

Prior experiments

Since the 19th century, investigators and clinicians have experimented with tubes and cuffs of various materials for sutureless repair of transected peripheral nerves (35,36). Early experimental epineural repairs with sutureless tubes showed improved alignment and less trauma, but did not result in improved nerve function. During World War II, many clinical epineural nerve repairs were made with tantalum cuffs. These repairs showed no functional improvement over similar suture repairs (37), and in time, the non-resorbable tantalum cuffs fragmented, causing local fibroses, and had to be removed.

Despite this setback, interest in sutureless epineural repair continued after the war (25). Investigators tested various materials such as parchment and transplanted arterial wall tissue for cuffs and tubes (3,10,12). Like the tantalum cuffs, these devices showed improved histological organization at the repair site, but no functional physiological improvement (25,27,33). There have been many subsequent attempts to refine epineural tube repairs (21,23,29,30), with approximately similar results.

Monofascicular perineurial tube repair of peripheral nerves was first reported in 1979 (26). In this experiment, the sutureless tubulization of rat saphenous nerve fascicles with hypoantigenic collagen membranes produced a repair that was better than suture repair, both histologically and physiologically. However, the prototype collagen tubes used in this study were primitive in design and very difficult to apply.

Multifascicular perineurial sutureless repairs

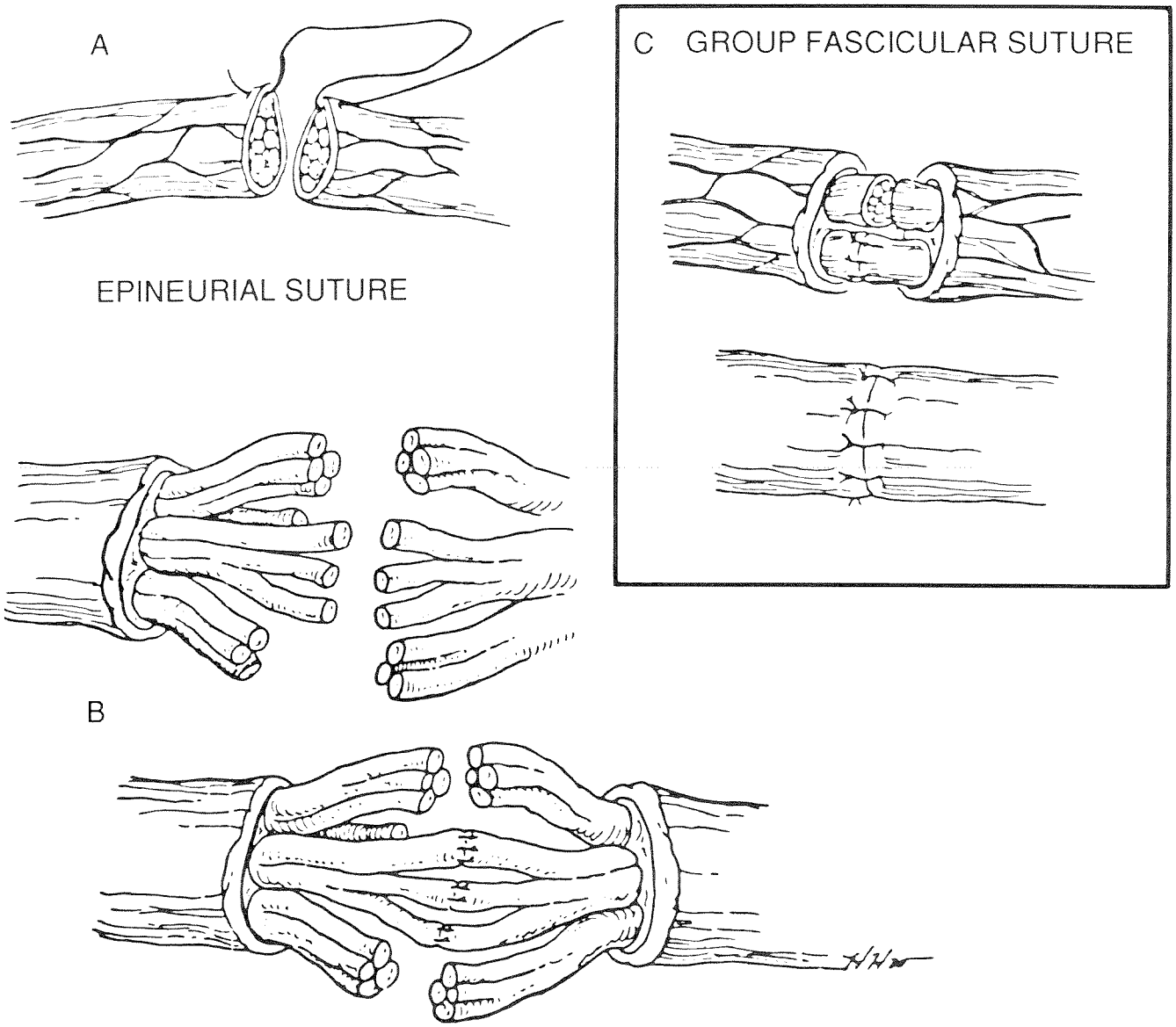

Figure 2.
Peripheral nerve suture methods (redrawn from Chase). a) Epineurial suture repair; b) Fascicular repair, perineurial suture repair; c) Grouped fascicular suture repair.

were also attempted in a cat model with collagen tubes (J.M. Rosen, *Annals of Plastic Surgery,* accepted for publication). Again, the use of collagen membranes proved very difficult. In an attempt to improve ease of application and also provide a resorbable repair medium, new tubes were made of polyglycolic acid (PGA) and tested in a monofascicular rat model (27). Histology and electrophysiology assessments after regeneration showed that the PGA tube repairs were functionally equal to monofascicular suture junctions, as well as being quicker and simpler to perform.

Adjuncts to axonal regeneration

It should be mentioned in passing that several investigators have used ancillary chemical and physical agents in an attempt to augment nerve repair. These include substances such as Cis-hydroxyproline, which alters scar formation at the repair site, various "nerve growth factors" such as the Glucosaminoglycans and Extracellular matrix and electric or magnetic fields applied to the reconnected nerve (5,6,7,8,11,16,29).*

*Also personal communication from V.R. Hentz, 1983.

Journal of Rehabilitation Research and Development Vol. 26 No. 3 Summer 1989

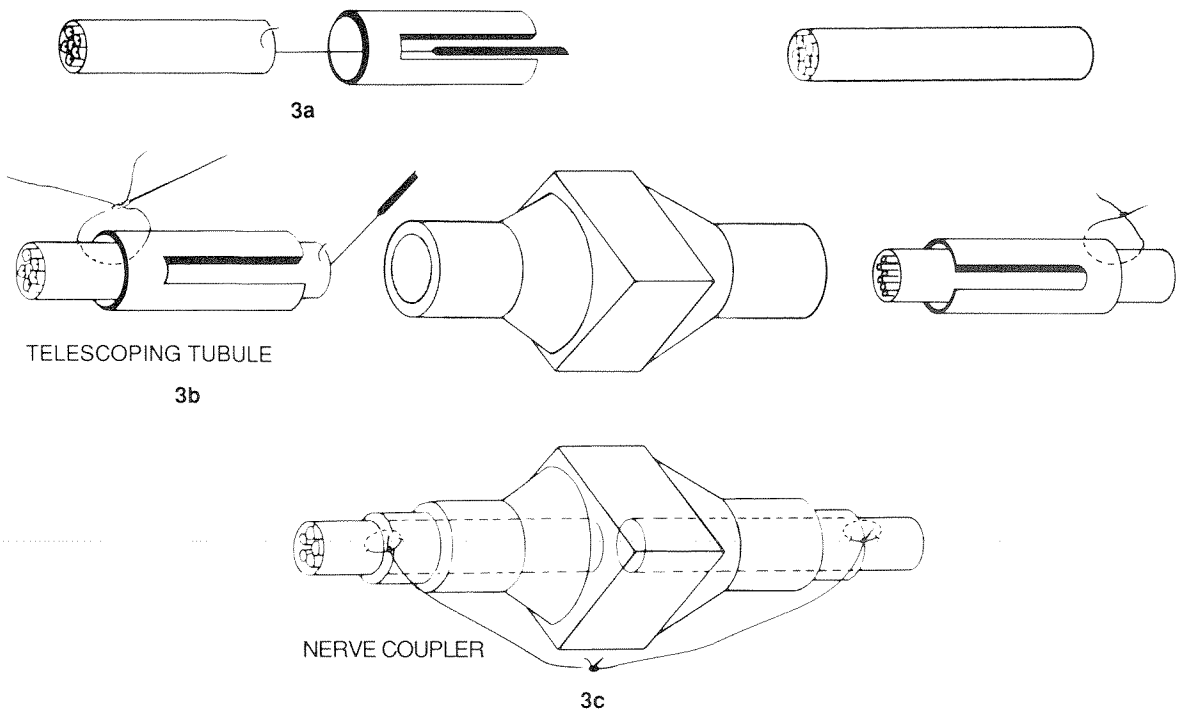

Figure 3.
Nerve coupler repair. a) Microhook is used to place single fascicle within tube; b) Telescoping tubules with fascicle held in place with microsuture. Fascicle end is brought slightly beyond end of tubule; c) Tubes with fascicles in place are placed proximally and distally within central nerve coupler. Nerve is then held in place by tying ends of microsutures across nerve coupler.

A NERVE COUPLER

Description

The evolution of new micro-casting techniques for PGA in the 1970s made possible the development of a sutureless microvascular coupler (4). The same technology has made possible the design and production of a prototype PGA nerve coupler (**Figure 3**). The device consists of three parts: 1) A central one-piece hollow housing from which extend short axial cylindrical tubes; and, 2 & 3) proximal and distal tubules which can encase a peripheral nerve or fascicle, and which are dimensioned to telescope firmly into the axial bores of the central housing. A narrow longitudinal slot may be cut through each tubule for part of its length (**Figures 3a, 3b**).

The prototype coupler housing is 7.0 mm long by 2.5 mm square at its widest point, with axial bores 1.3 mm in diameter. The telescoping tubes are each 5.0 mm long and have an internal diameter of 1.0 mm. Facilities exist for the fabrication of various sizes and shapes of PGA nerve couplers to suit particular sites and requirements.

Method of application

In use, a fine microhook is passed outward through the slot in each telescoping tubule and used to draw a transected nerve end through the tubule toward the central coupler (**Figure 3a**). The nerve ends are adjusted to extend slightly past the inner ends of the tubules. The tubules are then inserted into the opposing axial bores of the central coupler housing where they are retained by interwall friction, and the transected nerve ends are juxtaposed in direct contact. Typically, a small blood clot forms around the junction. Since the PGA tubules and coupler are nearly transparent, it is possible to align any contiguous longitudinal markings on the surface of the epineurium or perineurium. After the nerves have been positioned, a single longitudinal suture is passed superficially through each nerve sheath at the outer margin of its tubule and around the circumferential tubule bridge. It is tied off as a small loop, so that each nerve end is loosely connected to its respective tubule at the most proximal or distal intersection (**Figure 3b**). One tail from each suture loop is left long. To prevent the nerves from being withdrawn accidentally by subject movement, the

Table 1.
Timetable of the experiments.

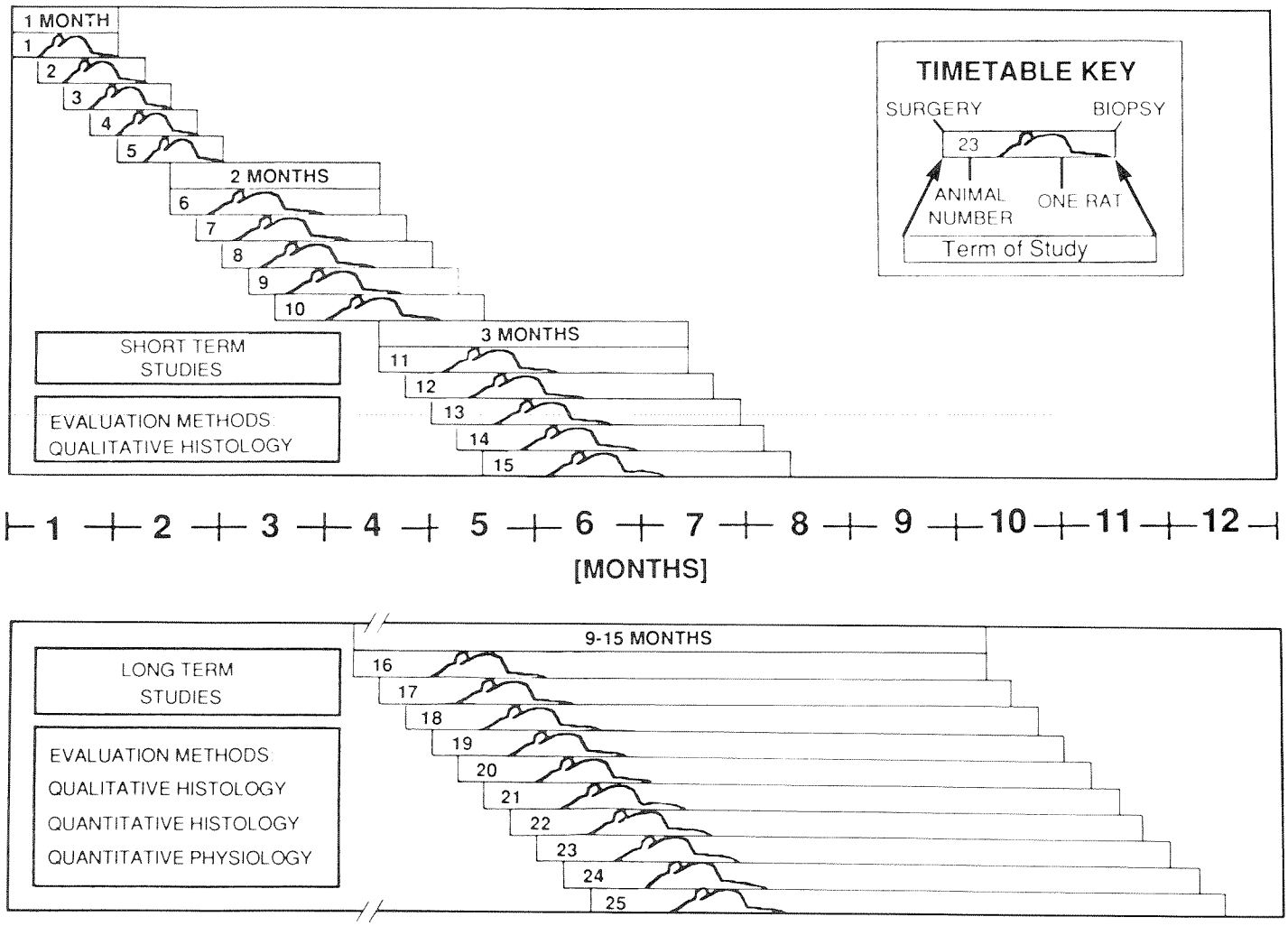

The upper timetable shows the short-term studies which were evaluated by qualitative histology. The lower timetable shows the long-term studies which were evaluated by qualitative and quantitative histology and, in addition, quantitative physiology. A total of 25 animals were included in this study. The timetable key shows the surgery onset and the biopsy as the termination. It also shows the animal number and the term of the study.

tails of the suture loops are tied together to make an untensioned retainer which parallels the coupler (**Figure 3c**).

EXPERIMENTAL MATERIALS AND METHODS

Model

Twenty-five male Sprague-Dawley rats weighing approximately 300 grams each were used to compare the nerve coupler to perineurial suture repair. The peroneal nerve of the hind leg was chosen for the transection and repair. This monofascicular nerve stems from the trifurcation of the sciatic nerve into the peroneal, sural, and tibial branches, and averages 0.9 mm in diameter for approximately 1 cm distal to its origin without branching. Bilateral transection in this segment causes minimal motor and sensory deficit in the rat.

Surgical procedure

Test animals were anesthetized with intraperitoneal sodium pentobarbital at 3-5 mg/100g of body weight. All surgery was performed under 16-25× magnification.

Journal of Rehabilitation Research and Development Vol. 26 No. 3 Summer 1989

Both peroneal nerves were exposed and transected sharply with a microscissors 1 cm distal to the trifurcation of the sciatic nerve. One randomly-chosen side in each animal was repaired using two or three 10-0 nylon sutures on a 70-micrometer diameter needle. The epineurium was removed from the repair site, and the sutures were placed through the perineurium only as in **Figure 2b**.

The opposite peroneal nerve in each animal was repaired using a nerve coupler as described above. Again the epineurium was removed, and no gap was left between the fascicle ends as observed through the wall of the nerve coupler.

Following the repairs, the muscles overlying the peroneal nerves were reapproximated with two 5-0 nylon sutures. The skin incision was closed with surgical wound clips. The animals were observed in the laboratory until they were awake and alert. They were then returned to the animal care facility for routine postoperative monitoring and care. The extremities were not immobilized, and no postoperative medications were given.

EVALUATION METHODS

The animals used in this study were divided into short- and long-term groups. The short-term group of 15 rats was assayed by qualitative histology only in three sets of 5 animals each, after 1, 2, and 3 months respectively, as shown in **Table 1**. (These regeneration times are too early for quantitative evaluation.) The 10 long-term rats were assayed both qualitatively and quantitatively after 9 to 15 months of regeneration, as shown in the schedule in **Table 2**. The qualitative studies assessed axonal organization and cellular reaction at the repair site; the quantitative study also assessed axonal regeneration.

Qualitative evaluation

Qualitative histology by optical microscopy

All nerve repair site biopsies were fixed in 3 percent cacodylate-buffered glutaraldehyde for a minimum of 24 hours. The repaired zone of the nerve was embedded in paraffin, and longitudinal sections were cut serially at 6 to 8 micrometer intervals. Half of the sections were stained with standard hematoxylin-eosin to evaluate tissue reaction. The reaction was assessed on the following scale:

Minimal:	50 White Blood Cells/100× Field (WBC/F)
Moderate:	50–100 WBC/F
Severe:	Extremely Numerous WBC/F

The other half of the sections were prepared with Bodian stain, which produces sharply delineated black axons, to assess the organization of regenerated axons. The scale of assessment was as follows:

Excellent:	Normal, 100 % of axons aligned
Good:	70 % - 90 % aligned
Fair:	40 % - 69 % aligned
Poor:	10 % - 39 % aligned
Failed:	No visible alignment

Quantitative evaluation

Quantitative histology using fiber diameter histograms

During nerve regeneration, axons ending in scar tissue and branched axons develop at a repair site. Axons ending in scar tissue are blocked, and hence nonfunctioning. Furthermore, axonal scarring and blockage stimulates compensatory axonal branching into empty endoneurial tubes distal to the repair site. As the demand on the proximal axons increases during this blocking and branching process, the average size of the distal fibers diminishes. Because of this, a comparison of the number of myelinated axons proximal and distal to a repaired nerve junction gives an uncertain estimate of the percentage of connected axons.

The use of fiber diameter histograms (FDH) of a nerve made distal to a repair site solves this problem, because an FDH measures both the size of the regenerated axons, which is proportional to their maturation, and their number. The reduction of axonal fiber size due to branching is also reflected in an FDH (24,25,27).

Preparation of the fiber diameter histograms

Nerve biopsies 5 mm distal to the repair site were taken in the final phase of the study. The biopsies were fixed in cacodylate-buffered 3 percent glutaraldehyde, followed by a second fixation in 1 percent osmium tetroxide. The specimens were then imbedded in EPON, and 1-micrometer serial sec-

Table 2.
Short-term studies.

Identification				Qualitative evaluation				
Animal number	**Coupler material**	**Study period**	**Type of repair**	**Adhesion**	**Neuroma**	**Alignment**	**Reaction**	**Organization**
382	PLEXIGLASS	24 DAYS	LC	MOD	NONE	EXC	MIN	EXC
			RC	MIN	NONE	EXC	MIN	EXC
384	PGA	9 DAYS	LS	MOD	MIN/MOD	GOOD	MIN	EXC
			RC	MIN	NONE	EXC	MIN	EXC
395	PGA	25 DAYS	LS	MIN	MIN	GOOD	MIN	GOOD
			RC	MOD	NONE	EXC	MIN/MOD	GOOD
396	PLEXIGLASS	DIED	LC/RS	NA	NA	NA	NA	NA
399	PGA	3 MOS.	LC	MIN	NONE	EXC	MOD	FAIR
			RS	MOD	NONE	EXC	MIN	EXC
446	PGA	2 MOS.	LC	MIN	NONE	EXC	ARTIFACT	ARTIFACT
			RS	MIN	MIN	GOOD	ARTIFACT	ARTIFACT
447	PGA	2 MOS.	LS	MOD	MIN	EXC	MIN	FAIR
			RC	MIN	NONE	EXC	MIN	FAIR
448	PGA	1 MO.	LC	MIN	NONE	EXC	MOD	EXC
			RS	MOD	NONE	GOOD	MIN	EXC
449	PGA	2 MOS.	LC	NONE	NONE	EXC	MOD/SEVERE	GOOD
			RS	MOD	MIN	EXC	MIN	GOOD
450	PGA	2 MOS.	LS	MOD	MIN	EXC	MIN	GOOD
			RC	NONE	NONE	EXC	MOD	GOOD
496	PGA	1 MO.	LC	MIN	NONE	EXC	SEVERE	EXC
			RS	MOD	NONE	GOOD	MIN	EXC
497	PGA	1 MO.	LS	MOD	MIN	EXC	MIN	GOOD
			RC	NONE	NONE	EXC	MOD	GOOD
498	PGA	1 MO.	LS	MOD	NONE	EXC	MIN	EXC
			RC	MIN	NONE	EXC	MOD	GOOD
531	PGA	DIED	LC/RS	NA	NA	NA	NA	NA
533	PGA	DIED	LC/RS	NA	NA	NA	NA	NA
535	PGA	3 MOS.	LC	MIN	NONE	GOOD	SEVERE	EXC
			RS	MIN	MIN	EXC	MIN	EXC
536	PGA	3 MOS.	LS	MOD	MIN	GOOD	MIN	EXC
			RC	MIN	NONE	EXC	MIN	EXC
539	PGA	3 MOS.	LS	NONE	NONE	EXC	MIN	FAIR
			RC	NONE	NONE	EXC	MIN	EXC
540	PGA	2 MOS.	LC	NONE	NONE	EXC	MOD	EXC
			RS	MOD	NONE	EXC	MIN	EXC
541	PGA	DIED	LS/RC	NA	NA	NA	NA	NA
542	PGA	3 MOS.	LC	MIN	NONE	EXC	MOD	EXC
			RS	MIN	NONE	EXC	MIN	EXC
543	PGA	2 MOS.	LS	MIN	NONE	EXC	MOD	GOOD-EXC
			RC	MIN	NONE	EXC	MIN	GOOD-EXC

KEY: LC: Left Coupler LS: Left Suture RC: Right Coupler RS: Right Suture
MIN: Minimal MOD: Moderate EXC: Excellent NA: Not available

tions were cut on an ultramicrotome, using a glass knife (27). The sections were stained with tuolidine blue and mounted on glass slides.

Black-and-white 8×10 inch photomicrograph prints were made of each section. The prints were scanned using a 300 dpi digitizing scanner with a 16-level gray scale, and the resulting image data was read into the memory of a Macintosh II computer. The digitized images were contrast-enhanced by eliminating all gray levels below the density of the

Journal of Rehabilitation Research and Development Vol. 26 No. 3 Summer 1989

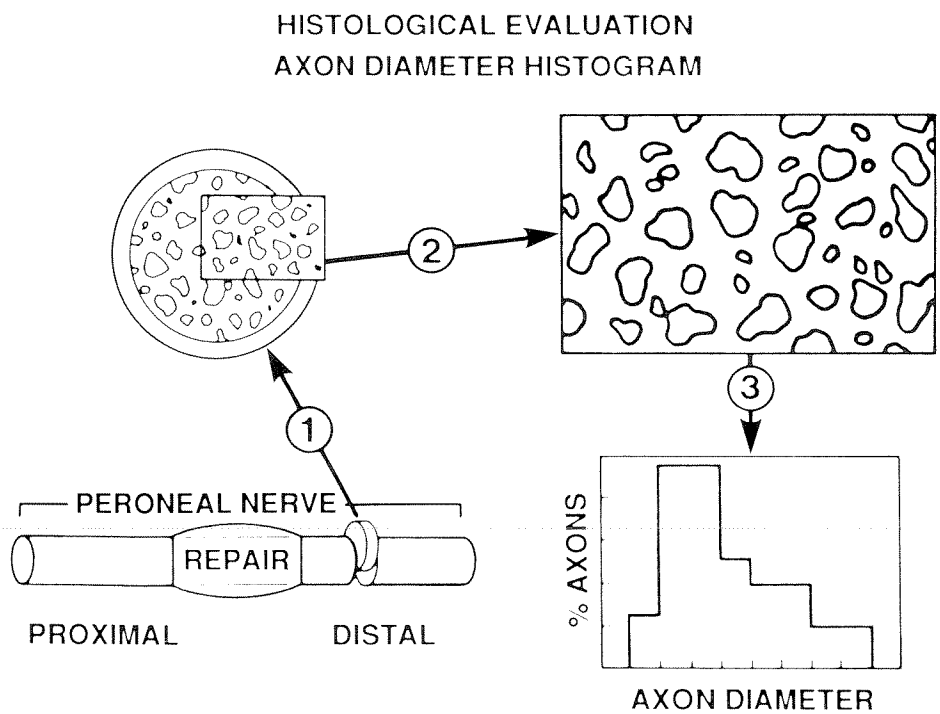

Figure 4.
Schematic illustration of fiber diameter histogram production. *Step One*—Distal cross section of nerve is cut to prepare histological specimen. *Step Two*—Photomicrograph is made from histological cross section. *Step Three*—Histological cross section is analyzed with computer-aided system to create axon diameter histogram (for further details see text). Schematic of physiological evaluation methods for obtaining Integrated Monophasic Compound Action Potential. Lower portion of drawing shows *in vivo* recording chamber with two stimulating electrode sites and one recording site. There is a proximal stimulating site as a control just proximal to the repair site. There is a distal stimulating site just distal to the repair site. The recording site is at the most proximal portion of the sciatic nerve. The most proximal electrode of this pair is over a crushed segment of the nerve to create a Monophasic Compound Action Potential. The signal is then sent to an oscilloscope and is integrated to obtain the area under the Compound Action Potential. The output on the oscilloscope is shown in the upper right. This demonstrates the Monophasic Compound Action Potential, the stimulus artifact, the gate (time window) for integration, and the time marks measuring 1 millisecond for each spike.

darker-staining myelin. Some remaining blood vessel outlines were removed manually. Between 45 percent and 50 percent of each digitized nerve section was counted, using recursive iteration of pixels forming the axon images. The output file included both axon numbers and axon diameters in microns. The latter data were used to construct frequency distribution histograms. This process is illustrated schematically in **Figure 4**. The accuracy of the system was verified by comparing data between it and a prior manual count system.

Electrophysiology

The Compound Action Potential (CAP) was used to evaluate physiological regeneration across the repaired nerve junction *in vivo*. The area under the CAP curve provides a measure of the total proximal myelinated axon potential with distal connection. The method of area measurement is by Integration of the Monophasic Compound Action Potential (IMCAP).

IMCAP procedure

As in the original nerve repair, the test animals were anesthetized with intraperitoneal sodium pentobarbital at 3-5 mg/100g of body weight and constrained in a supine position. Again all surgery was performed under 16-25× magnification. The peroneal nerve repair site was exposed surgically, and the area was bathed in mineral oil maintained at 35 degrees Centigrade. The nerve to be tested was dissected free of surrounding connective tissue at the sciatic notch for the placement of platinum wire recording electrodes. Small areas just proximal and distal to the repair site were also dissected free of connective tissue and placed on platinum wire

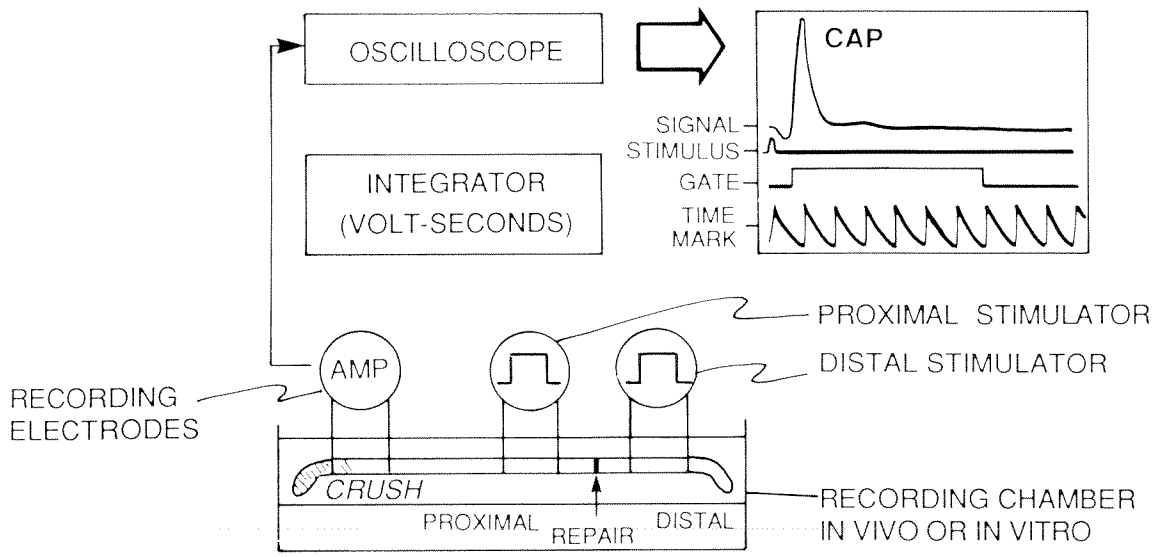

Figure 5.
Physiological evaluation. Integrated monophasic compound action potential.

stimulating electrodes. The repair site itself was left undisturbed (**Figure 5**).

The nerve test pulses were generated by a Grass S8 stimulator with two Model 478A stimulus isolation units. Voltage versus time characteristics of typical stimulating pulses are shown in **Figure 5**. The maximum pulse amplitude was set at 20 percent above the value needed to stimulate the total population of myelinated axons as measured by the IMCAP algorithm. The recorded signal was amplified by a WPI amplifier with a bandpass of 0.05 Hz to 10 kHz, and then passed through a Nicolet 1170 signal-averaging system to improve the signal-to-noise ratio. The Nicolet was used to set the stimulus time windows and to integrate the signal. The data was captured on a Hewlett-Packard 7010 X-Y chart recorder.

A baseline monophasic recording of the CAP was obtained by severing and crushing the nerve at the sciatic notch. The IMCAP recorded between the proximal electrode and the recording electrode provided a measure of the total population of myelinated axons in the nerve. The IMCAP recorded from stimulation of the distal electrode measured the proportion of myelinated axons that had reconnected across the repair site. The distal IMCAP divided by the proximal IMCAP gives the ratio of the total myelinated proximal axons with distal connections, normalized to the total proximal myelinated axon population. It is expressed as a percentage in our data.

Statistics

Wilcoxon's signed ranks tests (2,14) were used. This test compares two random samples from paired sequences of test data—in this case suture versus sutureless nerve repair in the same animal.

The ranking procedure is not influenced by the distribution patterns in the parent sample groups. This means that it is equally applicable to normal, logarithmic, or other data distributions.

The signed ranks test is based on the assumption that if there is no significant difference between two sets of paired measurements, any chance differences between them should include approximately equal numbers of plus and minus discrepancies. Both the direction and magnitude of differences between matched pairs are taken into account. If there is no significant difference between pairs, the sum of the ranks should be close to zero. The significance of inequalities between pairs is determined by specific calculations and use of the R Table for the Wilcoxon's signed ranks test. The test's sensitivity can be increased to virtually the same level as that of the more complex *t*-test.

Wilcoxon's signed ranks test requires a minimum population of 6 pairs of measurements showing a difference, plus all individual measurements in

Journal of Rehabilitation Research and Development Vol. 26 No. 3 Summer 1989

both compared sequences to achieve a 5 percent probability level. Our quantitative study group contained 10 animals.

EARLY EVALUATIONS (1, 2, AND 3 MONTHS)

Qualitative studies

Gross visual evaluation

A low magnification visual evaluation of the nerve repairs was made when each animal was biopsied. The factors assessed were: nerve adhesions to surrounding tissues, presence of neuromas, and gross nerve alignment. No failed repairs were identified by visual inspection.

Adhesions ranged from absent to moderate for both suture and coupler repairs in this group. The coupler repairs, however, showed generally fewer adhesions than their control suture repairs (**Table 2**). Neuromas were present in 50 percent of the suture junctions and absent in all coupler junctions. Nerve alignment was excellent in the 1- and 2-month coupler repairs, and good-to-excellent in the paired suture repairs. At 3 months, nerve alignment was excellent in all suture and coupler junctions.

Qualitative histology

Cellular reaction to PGA and to nylon sutures at the repair sites was evaluated in the 1 to 3 month repairs. The suture junctions showed minimal, predominantly lymphocytic, local reactions. The coupler repairs provoked reactions ranging from minimal to severe, including various fibroblasts, lymphocytes, and macrophages surrounding the degenerating PGA coupler (**Table 2**).

Both sets of junctions showed good to excellent nerve organization at 1 month, and fair to excellent organization at 2 months. Nerve alignment was excellent in all 3-month coupler repairs, and ranged from fair to excellent in the 3-month suture repairs.

LONG TERM EVALUATIONS (9-15 MONTHS)

Ten animals were evaluated at 9 to 15 months after surgery. Gross visual examination, qualitative histology, quantitative histology, and quantitative physiology were used in this assay.

Qualitative studies

Gross visual evaluation

Low magnification visual examination of the repair site was again used to evaluate adhesions, neuroma formation, and alignment of control suture and coupler repair nerves in the long-term group.

All 20 repairs were intact. Adhesions were generally more extensive in the suture repairs than in the contralateral coupler repairs. Of the suture sites, 3 had minimal adhesions, 2 had minimal to moderate adhesions, and 5 had moderate adhesions. Six coupler junctions had minimal adhesions, and 4 had moderate adhesions.

Visual examination revealed no neuromas in any nerves of this group. Gross nerve alignment was excellent in all suture and coupler repairs. For comparative data see **Table 3**.

Qualitative histology

Differences between the cellular reaction to PGA and nylon sutures at the repair sites were slight in the 9 to 15 month repairs. Seven of the suture nerves showed minimal reactions, and 3 showed minimal to moderate reactions. Of the coupler repairs, 8 showed minimal reactions to PGA, one showed minimal to moderate reaction, and one had a moderate reaction.

Repair site organization in the long-term group appeared to be significantly better for the coupler-repaired nerves than for the suture repairs. Of the 10 coupler repairs, 9 showed excellent organization and 1 showed good organization. The suture repair sites ranged from fair to excellent, with 4 of the 10 repairs showing excellent organization (**Table 3**).

Quantitative studies

Fiber diameter histograms

In the long-term group, cross-sections of the nerves 5 mm distal to the repair site were analyzed by axon counts and area determinations. As described above, a computer-linked digitizer determined a mean radius and mean area for each axon traced, summed the data, and extrapolated the 45 to 50 percent sampled area to the entire nerve. A histogram prepared from the area data is shown in **Figure 6**.

In the 10 animals evaluated, the mean diameters

Table 3.
Long-term studies.

Identification				Qualitative evaluation				Quantitative evaluation		
Animal number	**Coupler material**	**Study period**	**Type of repair**	**Adhesion**	**Neuroma**	**Alignment**	**Reaction**	**Organization**	**Mean distal axon diameter**	**IMCAP**
397	PGA	9 MOS.	LC	MOD	NONE	EXC	MIN	EXC	5.4 um	38%
			RS	MIN/MOD	NONE	EXC	MIN	GOOD-EXC	5.6 um	79%
398	PGA	9 MOS.	LS	MOD	NONE	EXC	MIN/MOD	GOOD-EXC	5.8 um	78%
			RC	MIN	NONE	EXC	MOD	GOOD	5.9 um	48%
527	PGA	12 MOS.	LC	MIN	NONE	EXC	MIN	EXC	4.8 um	22%
			RS	MIN	NONE	EXC	MIN	FAIR	5.1 um	68%
528	PGA	12 MOS.	LC	MOD	NONE	EXC	MIN	EXC	5.0 um	65%
			RS	MIN/MOD	NONE	EXC	MIN/MOD	EXC	5.3 um	68%
529	PGA	11.5 MOS.	LS	MOD	NONE	EXC	MIN	EXC	6.3 um	43%
			RC	MOD	NONE	EXC	MIN	EXC	5.9 um	67%
530	PGA	13.5 MOS.	LS	MOD	NONE	EXC	MIN	EXC	NA	62%
			RC	MIN	NONE	EXC	MIN	EXC	NA	71%
532	PGA	15 MOS.	LC	MOD	NONE	EXC	MIN	EXC	4.5 um	92%
			RS	MOD	NONE	EXC	MIN	FAIR-GOOD	5.4 um	79%
534	PGA	14 MOS.	LS	MOD	NONE	EXC	MIN	GOOD	4.4 um	48%
			RC	MIN	NONE	EXC	MIN	EXC	4.3 um	56%
537	PGA	15 MOS.	LC	MIN	NONE	EXC	MIN	EXC	4.1 um	80%
			RS	MOD	NONE	EXC	MIN	GOOD	4.8 um	60%
544	PGA	9 MOS.	LS	MIN	NONE	EXC	MIN-MOD	EXC	4.0 um	18%
			RC	MIN	NONE	EXC	MIN-MOD	EXC	3.8 um	25%

KEY: LC: Left Coupler LS: Left Suture RC: Right Coupler RS: Right Suture MIN: Minimal
MOD: Moderate EXC: Excellent NA: Not available IMCAP: Integrated Monophasic Compound Action Potential

and areas of the distal axons repaired by suture are slightly larger than those of the contralateral nerves repaired by coupler. This may indicate a slightly faster rate of myelin maturation and formation in the sutured junctions. The distal axon counts are higher in 80 percent of the coupler repaired nerves. These higher counts may represent more proximal axons with successful connections across the repair site, or they may represent more branching of proximal axons.

The results of Wilcoxon's signed rank tests on the matched pairs (coupler suture-repaired side) show that FDH results from repairs by suture are significantly better than the coupler repairs (**Table 3**). The results clearly indicate that a significant difference at the 5 percent level exists between the two populations of nerves. The number of tied groups were taken into account in our calculations.

Electrophysiology

Quantitative electrophysiology using the IMCAP procedure described above was performed on all nerve repairs in the long-term animal group. Gross responses were obtained from all nerves, as demonstrated by dorsiflexion of the appropriate foot during externally-applied electrical stimulation. The IMCAP percentage gives a comparison measure of axon regeneration; it does not, however, provide an absolute anatomical percentage of axons with distal reconnections.

Nerves repaired with couplers in 6 of the 10 animals showed superior physiological axonal regeneration as compared with nerves repaired with suture (see **Table 3**). Wilcoxon's signed ranks test on the matched pairs showed that there was no statistically significant difference between the two repair methods.

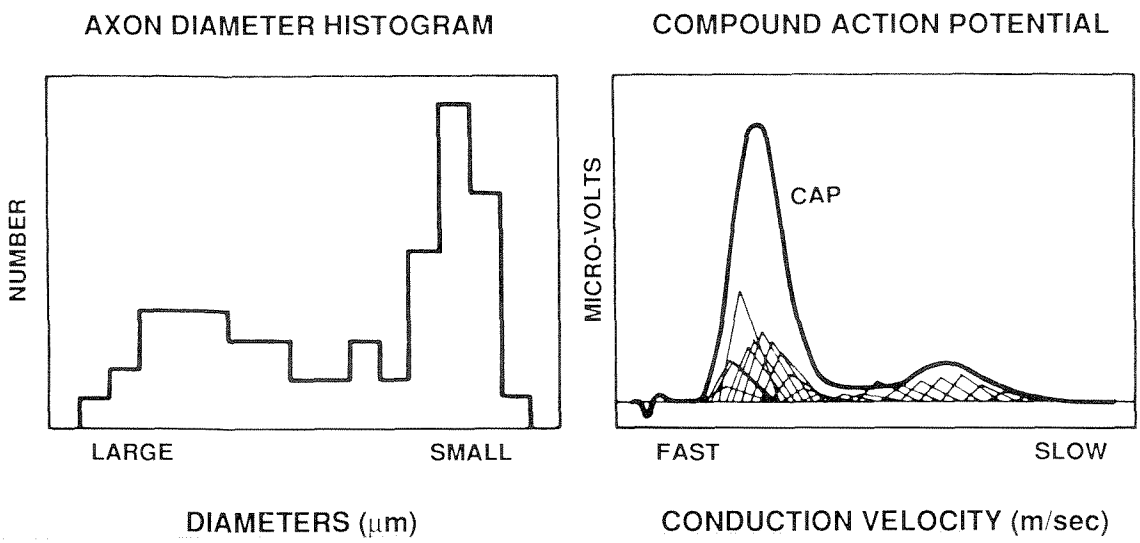

Figure 6.
Quantitative evaluation of nerve regeneration showing axon diameter histogram on the left and compound action potential on the right. The axon diameter histogram shows the number of fibers on the vertical axis and the size of the fibers on the horizontal axis. Large is shown to the left to make the axon diameter histogram agree with the compound action potential on the right. The Compound Action Potential vertical axis is in microvolts and the horizontal axis indicates conduction velocity. The fastest fibers are to the left and are the largest.

DISCUSSION

Background work

Historical and current methods of peripheral nerve repair by suture are based on an anatomical doctrine. The goal of this method is to re-establish physical continuity of the multiple layers of nervous tissue (33). In suture repairs, either the epineural or perineurial layers of connective tissue are reconnected by sutures to effect a junction and allow healing and regenerational nerve structures. In most suture repairs, the discrete layers of the nerve are obscured at the repair site by scar tissue.

A possible alternative to the anatomical philosophy of nerve repair is a cellular approach. The peripheral nerves are divided into two distinct cells by the perineurium (22) (**Figure 1**). The extrafascicular environment contains the cellular components—epineural and extrafascicular fibroblasts—which are responsible for the fibrous reaction to trauma. The intrafascicular cellular complement includes the Schwann cells, axons, and endoneurial fibroblasts that comprise the nerve's transmission and regeneration apparatus. A cellular approach to nerve repair involves the installation of an artificial perineurium to separate these two cellular environments during the repair and regeneration period. Over the past eight years Rosen has developed tubes of hypoantigenic collagen and PGA for use as artificial perineurium in nerve repair (25,26,27). These tubes are resorbable, and represent an attempt to provide a prosthetic perineurial membrane until the nerve reestablishes this cell separation layer naturally.

Nerve coupler development

The prototype plexiglass couplers used in the experiments described in this report were first designed by Rosen to see if nerves could be mechanically coupled. A pilot series of couplers, some machined from plexiglass and some cast from PGA, was produced through the cooperation of Lehmann Li of Davis & Geck, Inc. In 1984, Grosser modified the prototype couplers and designed new versions which were again produced in both plexiglass and PGA for us by Davis & Geck (29). The redesign/experiment cycle has gone through several iterations as of this writing.

CONCLUSIONS

Our results indicate that the prototype nerve coupler used in these experiments provides a means

of nerve repair comparable to the suture techniques currently in use. Histologically, suture repairs appear to produce slightly larger mean axon diameters distal to the repair site, possibly because of a lack of constriction. Future resorbable couplers should reduce this compression neuropathy. The nerve coupler gives equal or better physiological results, and the nerve organization after a coupler repair appears to be qualitatively better than in a suture repair. The study shows no statistically significant difference in functional regeneration between nerves repaired with the coupler or with sutures.

As indicated above and in **Tables 2 and 3**, repaired nerves evaluated at a longer time postoperatively show decreased cellular reaction, improved nerve fiber maturation, and a larger number of axons regenerated across the repaired junction. It is possible that this trend continues for a longer period than the maximum postoperative time of 15 months assayed in our experiment. If that is the case, it is also possible that the balance of the results could be shifted in one direction or the other.

The nerve coupler is to our knowledge the first device of its kind to be used for nerve repair. We believe that it offers an improvement over prior repair techniques in several ways. First, even with the early version of the coupler used in these experiments, the surgical repair sequence is easier, faster, and causes far less trauma to the nerve than sutures. Second, it allows precise, adjustable alignment and approximation of the nerve or fascicle ends both radially and axially. Third, it protects the repair site completely from the ingrowth of scar tissue during the regeneration period and inhibits the growth of neuromas.

The early version of the nerve coupler can obviously be improved. This study shows that it is usable in its present form as a carrier for electronics and for *in situ* application of nerve growth factor and other enhancements.

FUTURE STUDIES

The newest model of the PGA coupler is modified in shape, includes a directional key, and is available in several diameters to fit fascicles of various sizes. It will soon be made from a new bioresorbable material which is more pliable and easier to manipulate with microsurgical tools.

Our initial experiments with rats were made to test the feasibility of this novel method of nerve repair. Our ultimate goal is to improve human nerve repair. We have recently started studies using the nerve coupler in ways that may expand our knowledge of this problem. First, we have used it as a vehicle for introducing therapeutic substances to the nerve repair site. We will be evaluating agents such as Cyclosporin-A, a potent inhibitor of cell-mediated immunologic activity, and Cis-hydroxyproline, an antagonist of scar formation. In this mode, the bioresorbable coupler will serve as a drug reservoir, maintaining pharmacologicallv-active levels at the repair site throughout regeneration. Modifications of the nerve coupler could be used in fabricating artificial nerve grafts (28). In this application, the space between the ends of the nerve would be expanded and lengthened to overcome a nerve gap. This space could be filled with a matrix to encourage nerve regeneration.

Rosen and Grosser are using a further modified version of the coupler as the mount for a microelectronic axon processor (MAP), a programmable neuroelectronic chip that we hope will allow permanent redirection of misconnected axons in peripheral motor nerves (29, reports in preparation).

REFERENCES

1. **Bora FW Jr:** Peripheral nerve repair in cats: The fascicular stitch. *J Bone Joint Surg* 49A:659, 1967.
2. **Brown BW, Hollander M:** *Statistics: A Biomedical Introduction,* 310-316. New York: John Wiley & Sons, 1977.
3. **Cairns H, Young JZ:** Treatment of gunshot wounds of peripheral nerves. *Lancet* 123-130, August, 1940.
4. **Daniel RK, Terzis JK (Eds.):** Microsutures: Their evolution and role in microvascular surgery. In *Reconstructive Microsurgery,* 43-45. Boston: Little Brown, 1977.
5. **DeMedinaceli L, Freed WJ:** Peripheral nerve repair with distributed mechanical support. *Soc Neurosci Abstr* 8:26, 1982.
6. **DeMedinaceli L, Freed WJ:** Peripheral nerve reconnection: Immediate histologic consequences of distributed mechanical support. *Exp Neurol* 81:459, 1983.
7. **DeMedinaceli L, Freed WJ, Wyatt RJ:** Peripheral nerve reconnection: Improvement of long-term functional effects under simulated clinical conditions in the rat. *Exp Neurol* 81:488, 1983.
8. **DeMedinaceli L, Wyatt RJ, Freed WJ:** Peripheral nerve reconnection: Mechanical, thermal, and ionic conditions that promote the return of function. *Exp Neurol* 81:469, 1983.

9. **Doyle JR:** Factors affecting clinical results of nerve suture. In *Nerve Repair and Regeneration: Its Clinical and Experimental Basis,* D.L. Jewett, H.R. McCarroll, Jr. (Eds.). St. Louis: CV Mosby, 1980.
10. **Ducker TB, Hayes GJ:** Peripheral nerve injuries: A comparative study of the anatomical and functional results following primary nerve repair in chimpanzees. *Milit Med* 133:298, 1968.
11. **Freed WJ, DeMedinaceli L, Wyatt RJ:** Promoting functional plasticity in the damaged nervous system. *Science* 227:1544, 1985.
12. **Freeman BS:** Adhesive anastomosis technique for five nerves: Experimental and chemical techniques. *Am J Surg* 108:529-532, 1964.
13. **Ito T, Hirotani H, Tanamoto K:** Peripheral nerve repairs by the funicular suture technique. *Acta Orthop Scand* 47:283, 1976.
14. **Langley R (Ed.):** *Practical Statistics.* New York: Dover Publications, 1971.
15. **Levinthal R, Brown WJ, Rand RW:** Comparison of fascicular, interfascicular, and epineurial suture techniques in the repair of simple nerve lacerations. *J Neurosurg* 47:744, 1977.
16. **Lundborg G, Hansson HA:** Regeneration of peripheral nerve through a preformed tissue space. Preliminary observations on the reorganization of regenerating nerve fibers and perineurium. *Brain Res* 178:573, 1979.
17. **MacKenzie IG, Woods CG:** Cause of failure after repair of the median nerve. *J Bone Joint Surg* 43B:465-473, 1961.
18. **Millesi H:** Fascicular nerve repair and intrafascicular nerve grafting. In R.K. Daniel, J.K. Terzis (Eds.), *Reconstructive Microsurgery*, Boston: Little Brown, 1977.
19. **Millesi H:** Reappraisal of nerve repair. *Surg Clin North Am* 61:321, 1981.
20. **Moberg E:** Evaluation and management of nerve injuries in the hand. *Surg Clin North Am* 44:1019, 1964.
21. **Molander H, et al.:** Nerve repair using a polyglactin tube and nerve graft: An experimental study in the rabbit. *Biomaterials* 4:276, 1983.
22. **Morris JH, Hudson AR, Weddell G:** A study of degeneration and regeneration in the divided rat sciatic nerve based on electron microscopy. *Z Zellforsch* 124:165, 1972.
23. **Nyilas E, et al.:** Synthetic bioresorbable polymers: 1. Polyester and polyester-composite guidance channels for peripheral nerve repair. *Transactions of the 9th Annual Meeting of the Society of Biomaterials* 6:85, 1983.
24. **Rosen JM, Jewett DL:** Physiologic methods of evaluating experimental nerve repair. In *Experimental Basis,* 150-162. St. Louis: CV Mosby, 1980.
25. **Rosen JM, Kaplan EN, Jewett, DL:** Suture and sutureless methods of repairing experimental nerve injuries. In *Nerve Repair and Regeneration: Its Clinical and Experimental Basis,* D.L. Jewett, H.R. McCarroll, Jr. (Eds.), 235-242. St. Louis: CV Mosby, 1980.
26. **Rosen JM, Kaplan EN, Jewett DL, Daniels JR:** Fascicular sutureless and suture repair of the peripheral nerves. *Ortho Rev* 8:85, 1979.
27. **Rosen JM, Hentz VR, Kaplan EN:** Fascicular tubulization: A cellular approach to peripheral nerve repair. *Ann Plast Surg* 11:397, 1983.
28. **Rosen JM, et al.:** Artificial nerve graft compared to autograft in a rat model. *J Rehabil Res Dev* 26(1):1-14, 1989.
29. **Rosen JM, Grosser M:** Nerve repair at the axon level: A merger of microsurgery and microelectronics. In *Artificial Organs,* J.D. Andrade, *et al.* (Eds.), 583-594. Salt Lake City: VCH, 1987.
30. **Sidman RL, Nyilas E, Chiu TH, Brushart T, Hoshin Y:** Synthetic channel implants: Regenerative response in rodent sciatic nerve. Presented at *American Paralysis Association Workshop III,* Arlie House, VA, 1982.
31. **Sunderland S:** Funicular suture and funicular exclusion in the repair of severed nerves. *Br J Surg* 40:580, 1953.
32. **Sunderland S:** Factors influencing the course of regeneration and the quality of the recovery after nerve suture. *Brain* 74:19, 1952.
33. **Sunderland S:** The anatomic basis of nerve repair. In *Nerve Repair and Regeneration: Its Clinical and Experimental Basis,* D.L. Jewett, H.R. McCarroll, Jr. (Eds.), 14-35. St. Louis: CV Mosby, 1980.
34. **Usbeck W:** Nerve suture without tension, a method for repairing transected peripheral nerves. *Acta Neurochir (Wien)* 34:215, 1976.
35. **Weiss PA:** Sutureless reunion of severed nerves with elastic cuffs of tantalum. *J Neurosurg* 1:219-225, 1944.
36. **Weiss PA:** *From Cell Research to Nerve Repair: Articles Illustrating the Transition from Biological Experience to Medical Practice,* 315-425. New York: Futura Publishing Co., Inc., 1976.
37. **Woodhall B, Beebe GW (Eds.):** *Peripheral Nerve Regeneration: A Follow-Up Study of 3,656 Word War II Injuries.* Veterans Administration Medical Monograph, Washington, DC: US Govt. Printing Office, 1956.