

## A comparative study of the effects of electrical stimulation and laser treatment on experimental wound healing in rats

Hüseyin Demir, MD; Halil Balay, MD; Mehmet Kirnap, MD

Erciyes University Medical Faculty, Department of Physical Medicine and Rehabilitation, Kayseri, Turkey;  
Private Practice, Sanliurfa, Turkey

**Abstract**—We investigated the effects of electrical stimulation (ES) and laser treatment on wound healing in rats. A randomized-controlled trial, conducted at the Experimental and Clinical Research Centre of Erciyes University (Kayseri, Turkey), divided 124 healthy female Swiss-Albino rats into four groups. A 6 cm linear incision was made at the dorsal skin of all rats. Group 1 was given a constant direct current of 300  $\mu$ A for 30 min per day. The current was applied in negative polarity for the first 3 days and in positive polarity for the next 7 days. Group 3 received a full-contact, continuous gallium-arsenide (GaAs) laser therapy, with a wavelength of 904 nm, an energy density of 1 J/cm<sup>2</sup>, and an average power of 6 mW for 10 min per day. The remaining two groups (Groups 2 and 4) were considered the control groups and received sham treatment. All groups were treated for 10 days. Histopathologic and biochemical evaluations were conducted on 10 rats from each group on the 4th and 10th days, and wound breaking strength was measured for biomechanical evaluation on the 25th day of the study. Both ES and laser treatment proved significantly effective in the inflammatory phase compared with control groups ( $p < 0.05$ ); however, the ES was even more effective than laser treatment, with more significant results ( $p < 0.05$ ). In the proliferation and maturation phases, while ES and laser treatment were both found to be significantly effective treatment methods compared with the control groups, no statistically significant difference was observed between the two treatment groups ( $p > 0.05$ ). Although ES and laser treatment both were effective in the maturation phase, increasing wound breaking strength compared with their control groups ( $p < 0.05$ ), there was no statistically significant difference between the two treatment groups ( $p > 0.05$ ). We conclude that ES and laser treatment both have beneficial effects during the inflammatory, proliferation, and maturation phases of a wound. Both

ES and laser treatment can be used successfully in decubitus ulcers and chronic wounds, in combination with conventional therapies such as daily care and debridement of wounds; however, ES has more beneficial effects during the inflammatory phase in some parameters than laser treatment.

**Key words:** electrical stimulation, laser, wound healing, physical therapy, rat.

### INTRODUCTION

Wound healing, the result of a complex tissue repairing process, is a continuing challenge in rehabilitation medicine. Despite some recent advances in understanding its basic principles, problems in wound healing continue to cause significant morbidity and mortality [1]. Studies on wound healing have increased our knowledge and understanding of pressure ulcers [2], an important clinical

---

**Abbreviations:** ES = electrical stimulation, GaAs = gallium arsenide, PNL = polymorphonuclear leukocytes.

**This material was based on work supported by the Experimental and Clinical Research Center of Erciyes University**

Address all correspondence to Hüseyin Demir, MD, Erciyes Üniversitesi Tıp Fakültesi, FTR Anabilim Dalı, 38039, Kayseri-TURKEY; +90.352.437 49 01/22077; fax: +90.352.437 52 85; email: demirh@erciyes.edu.tr.

problem, but they remain the second most frequent cause of death in patients with spinal cord injury. A great number of studies have been conducted on the acceleration of wound healing, attainment of normal breaking strength, and prevention of keloid and scar formation. Recently, it was reported that both electrical stimulation (ES) and laser treatment facilitate and accelerate wound healing, and also improve scar quality [3–14]. The literature does not compare ES with laser treatment on acceleration of wound healing and quality of scar formation. In this study, we aimed to investigate and compare the effects of ES and laser treatment on wound healing. We performed a randomized-controlled trial to evaluate the wound healing process according to its various phases.

## METHODS

The study included 124 healthy female Swiss-Albino rats, each 200 to 240 g and 8 to 10 months of age. The study was conducted at the Experimental and Clinical Research Centre of Erciyes University in Kayseri, Turkey. All rats were housed in metal cages at 15 °C to 18 °C, with 12 hours per day of light, and fed standard rat chow and water. After a 6 cm linear incision was made at the dorsal skin, the rats were randomly divided into 4 groups of 30 rats each. The treatment protocols used were ES in Group 1, control ES in Group 2, laser in Group 3, and control laser in Group 4. In all groups, histopathologic and biochemical evaluations were conducted on the 4th and 10th days, and biomechanical tests were performed on the 25th day of the study. In addition, results of daily macroscopic observations of the wounds were recorded.

### Surgical Procedure

After local preparation of the dorsal skin and general anaesthesia of rats by ketamine (60 mg/kg, intraperitoneally), a 6 cm full-thickness linear incision was made 2 cm away from the dorsal midline, including the panniculus carnosus. The incision was sutured with 5.0 prolene intradermally. All surgical procedures were performed by the same investigator.


### Treatment Methods and Group Formation

Treatment was started in all groups within 2 h of the surgical procedure and continued for 10 days. For Group 1, we used an ES treatment device (model Endomed 582,

Enraf-Nonius Co., The Netherlands). Carbon rubberized electrodes were placed on pads moistened with 0.09-Ns percent sodium chloride solution. The active electrode was placed on the incision and the passive electrode was placed distal to the incision. Direct current of 300  $\mu$ A was applied continuously for 30 min per day, by negative polarity for the first 3 days and positive polarity for the next 7 days. For Group 2, we followed a similar procedure, including the saline dressing, with no current applied (sham method). In Group 3, a gallium-arsenide (GaAs) laser device (model Laserpet 100, Petas Co., Turkey), delivered a 904 nm wavelength, 6 mW average power, 1 J/cm<sup>2</sup> dosage, with a maximum frequency of 128 Hz. This dosage was delivered continuously for 10 min per day for 10 days, with a stroking method. Additional specifications of the laser device were an infrared GaAs laser tube, 6 mW mean and 27 mW maximum power, 15° emission angle and continuous and modulated output type, and 1Hz to 128 Hz frequency, as well as an output indicator, operation timer, and laser detector. For Group 4, we followed a similar procedure, with no current applied (sham method).

All wounds were cleaned with povidon-iodine solution every day, and the rats returned to their metal cages. Ten rats in each group were killed with a 2 cc intracardiac KCl injection on the 4th, 10th, and 25th days. We divided each incision into parts a, b, c, d, e, and f (**Figure 1**). Parts a and c were used for histopathologic evaluation, parts b and d for biochemical evaluation, and parts e and f for biomechanical evaluation. Histopathologic and biochemical evaluations were performed on the 4th and 10th days, and biomechanical evaluation on the 25th day. Full-thickness samples were obtained after the surgical process. Slides were stained with hematoxylin and eosin for polymorphonuclear leukocytes (PNL), macrophages, and fibroblasts by the method of Young and Dyson [15]; Masson's trichrome for collagen density and arrangement by the method of Brown (personal communication, Brown M, Washington University, St. Louis, 1992); and toluidine blue for mast cells by the method of Weiss et al. [5], for histopathologic analysis. The level of tissue hydroxyproline was measured with the double-blind method in parts b and d by the method of Reddy and Envemeka for biochemical analysis [16].

For biomechanical evaluation on the 25th day, after sacrificing the rats with the KCl injection and removing the sutures, we used a parallel surgical blade to excise two 10 mm strips, 6 cm long, in parts e and f of the



**Figure 1.**  
Model of dorsally based skin wound of rat.

wound, according to the method of Mustoe [7]. The wound breaking strength, measured in Newtons by a tensiometer (model 4411, Instron Inc., England), provided data to identify the maturation phase of the wound for biomechanical evaluation by the blind method. A pneumatic action clamp was used to attach each wound part to the testing system; then each clamped wound was pulled to rupture at a cross-head speed of 250 mm/min to measure the breaking strength.

### Statistical Analysis

A chi-squared test was used to compare the collagen density and arrangement of the groups. The Mann-Whitney U test was used for statistical analysis of the other parameters.

## RESULTS

A small serohemorrhagic leakage was seen within first few days in the ES control and laser treatment control groups. The duration of the inflammatory phase was decreased in the ES and laser treatment groups compared with their control groups ( $p < 0.05$ ). In a comparison of the ES and laser treatment groups, ES was more effective in decreasing the duration of this phase, particularly in decreasing PNL, macrophages, and the number of mast cells ( $p < 0.05$ ). Both treatment modalities had a positive effect on the proliferation phase, increasing the fibroblast number and hydroxyproline level, and stimulating the synthesis and organization of collagen compared with their control groups ( $p < 0.05$ ). However, there was no statistically significant difference between ES and laser treatment ( $p > 0.05$ ). The mast cell count was lower in the

ES group compared to the laser group on the 4th day ( $p < 0.05$ ); however, there was no statistically significant difference between the treatment groups on the 10th day ( $p > 0.05$ ). On the 4th and 10th days, the collagen density and arrangement were significantly better in the ES and laser treatment groups than in their control groups ( $p < 0.05$ ), but there was no statistically significant difference between the treatment groups ( $p > 0.05$ ).

Both ES and laser treatment were found to be effective in the maturation phase, increasing wound breaking strength compared with their control groups ( $p < 0.05$ ), but there was no statistically significant difference between the treatment groups ( $p > 0.05$ ).

Overall results are summarized in **Tables 1, 2, 3, and 4** and **Figures 2, 3, and 4**.

## DISCUSSION

Numerous recent studies, focused on accelerating wound healing and considerably improving the strength and quality of scar formation, have emphasized the efficacy of ES in this process [3–8,17–19]. The beneficial effects of laser treatment on wound healing and qualified scar formation have also been reported [9–14,20,21]. In this study, we aimed to compare the effects and efficacy of ES and laser treatment on wound healing and scar formation. Our study designed considered the various phases of wound healing, a very important subject in experimental clinical studies.

The cells have a complex electricity that is sensitive to changes in electrical fields. Metabolic, immunologic, and physiologic changes have been found to develop in different cell cultures after electrical current is applied [3]. A small amount of voltage, which is produced as long as the collagen bundle is subjected to stress, is necessary for production, continuity, arrangement, and absorption of the collagen. It has been suggested that the recorded current in experimental wounds triggers wound healing [22]. Because of this effect, we used exogenous electrical current to accelerate wound healing and obtain a stronger scar [23,24]. ES with different polarities has been reported to increase the breaking strength of the wound, which would increase naturally after 3 weeks [25]. We applied negative polarity for the first 3 days and positive polarity for the next 7 days, based on the antibacterial effect of the negative polarity and epithelization effect of positive polarity.

**Table 1.**  
Analysis of data on 4th day.

Parameters	Electrical Stimulation (n = 10)	Sham Electrical Stimulation (n = 10)	<i>p</i>	Laser Treatment (n = 10)	Sham Laser Treatment (n = 10)	<i>p</i>
	<i>X</i> ± SD	<i>X</i> ± SD		<i>X</i> ± SD	<i>X</i> ± SD	
Polymorphonuclear leukocytes	12.40 ± 1.14	51.20 ± 1.30	<0.05	17.40 ± 1.14	61.00 ± 5.24	<0.05
Macrophages	19.60 ± 1.14	30.60 ± 0.89	<0.05	25.60 ± 1.14	35.60 ± 0.89	<0.05
Mast cells	20.40 ± 1.14	20.20 ± 1.48	>0.05	24.20 ± 0.84	17.60 ± 0.55	<0.05
Fibroblasts	82.20 ± 1.14	36.80 ± 0.84	<0.05	82.60 ± 2.07	32.80 ± 2.17	<0.05
Hydroxyproline (mg/gr)	0.59 ± 1.14	0.11 ± 0.03	<0.05	0.62 ± 0.02	0.14 ± 0.04	<0.05

**Table 2.**  
Analysis of data on 10th day.

Parameters	Electrical Stimulation (n = 10)	Sham Electrical Stimulation (n = 10)	<i>p</i>	Laser Treatment (n = 10)	Sham Laser Treatment (n = 10)	<i>p</i>
	<i>X</i> ± SD	<i>X</i> ± SD		<i>X</i> ± SD	<i>X</i> ± SD	
Polymorphonuclear leukocytes	2.60 ± 1.32	37.40 ± 3.05	<0.05	8.60 ± 1.52	43.20 ± 1.79	<0.05
Macrophages	14.00 ± 1.30	27.80 ± 1.30	<0.05	17.40 ± 1.14	27.40 ± 0.89	<0.05
Mast cells	7.00 ± 0.71	33.40 ± 1.14	<0.05	6.20 ± 0.84	22.80 ± 0.84	<0.05
Fibroblasts	115.20 ± 1.92	51.8 ± 1.92	<0.05	113.20 ± 4.09	53.00 ± 2.83	<0.05
Hydroxyproline (mg/gr)	0.99 ± 0.13	0.22 ± 0.01	<0.05	1.01 ± 0.13	0.22 ± 0.01	<0.05

**Table 3.**  
Comparison of data on 4th and 10th days.

Parameters	4th Day			10th Day		
	Electrical Stimulation (n = 10)	Laser Treatment (n = 10)	<i>p</i>	Electrical Stimulation (n = 10)	Laser Treatment (n = 10)	<i>p</i>
	<i>X</i> ± SD	<i>X</i> ± SD		<i>X</i> ± SD	<i>X</i> ± SD	
Polymorphonuclear leukocytes	12.40 ± 1.14	17.40 ± 1.14	<0.05	2.60 ± 1.32	8.60 ± 1.52	<0.05
Macrophages	19.60 ± 1.14	25.60 ± 1.14	<0.05	14.00 ± 1.30	17.40 ± 1.14	<0.05
Mast cells	20.40 ± 1.14	24.20 ± 0.84	<0.05	7.00 ± 0.71	6.20 ± 0.84	>0.05
Fibroblasts	82.20 ± 1.48	82.60 ± 2.07	>0.05	115.20 ± 1.92	113.20 ± 4.09	>0.05
Hydroxyproline (mg/gr)	0.59 ± 0.01	0.62 ± 0.02	>0.05	0.99 ± 0.13	1.01 ± 0.13	>0.05

Laser treatment also has been studied in wound healing. Currently, it is used in decubitis and diabetic ulcers, open wounds, venous ulcers, graft ulcers, incisions, lacerations, and burns. Studies in vivo and in vitro showed that the laser treatment accelerated the biochemical reactions,

fibroblast activity, collagen metabolism, neovascularization, qualified scar formation, and wound formation [9–14,20,21]. The issue of “significant” thermal change is controversial, although it is concluded in some textbooks and books that the low-energy laser does not produce

Table 4.

Comparison of wound breaking strength on 25th day.

	Electrical Stimulation (n = 10)	Sham Electrical Stimulation (n = 10)		Laser Treatment (n = 10)	Sham Laser Treatment (n = 10)	
	X ± SD	X ± SD	p	X ± SD	X ± SD	p
Breaking strength (N)	7.77 ± 1.42	2.38 ± 0.77	<0.05	6.76 ± 1.32	1.84 ± 0.61	<0.05

significant tissue temperature changes [26,27]. Therefore, there is no unanimous agreement on the thermal effects and treatment protocol of laser treatment on wound healing, and more studies are required in this field. Recommendations vary widely for the optimal energy under different conditions; the usual ranges are from 0.5 to 10 J/cm<sup>2</sup> [27]. Generally, a laser with a wavelength of 600 to 984 nm is used in physical medicine, and a wavelength of 632.8 nm for a helium-neon laser and 904 nm for a GaAs laser are used most frequently in wound healing [9–

14,27]. For our study, therefore, we used a GaAs laser with a wavelength of 904 nm and power of 1 J/cm<sup>2</sup>.

Wolcott et al. [28] and Gault et al. [29] concluded that negative polarity had an antibacterial effect. Takan et al. [8] reported that the PNL number was found to be lower in the ES group compared with the sham ES group on the 4th and 10th days after application of negative polarity for 3 days. In our study, we found significantly decreased PNL numbers in the ES group compared with the sham ES group on the 4th and 10th days after application of negative polarity for 3 days.

Laser treatment was also reported to have an antibacterial effect, by inhibiting proliferation of bacteria in cultures and stimulating the phagocytic activity of leukocytes in vitro [30]. In our study, the PNL number was increased in the laser treatment group compared with the sham laser treatment group. This finding indicates suppressed inflammation, which is desired in clean wound healing. Some authors report that low-energy laser treatment decreases the duration of the inflammatory phase [14,31]. We, too, found a decreased number of macrophages in the laser treatment group compared with the sham laser treatment group. However, we did not find any previous study in the literature reporting on the effects of laser treatment on the number of macrophages.

When we compared these two treatment modalities in the inflammatory phase, the numbers of PNL and macrophages were found to be more decreased in the ES group than in the laser treatment group. This difference indicates that ES decreased the duration of the inflammatory phase significantly more than the laser treatment.

ES has a galvanotaxis that is described as a migration of myofibroblast, fibroblast, and epithelial cells [23,32–34]. Alvarez et al. reported that direct electrical current increased the migratory and proliferative activity in incisional skin wounds in pigs [3]. ES treatment allows the wound to reach the phases of proliferation earlier [25,35]. The difference in the fibroblast number between the ES and the ES sham groups in our study on the 4th day indicates the beneficial effect of ES treatment on the early

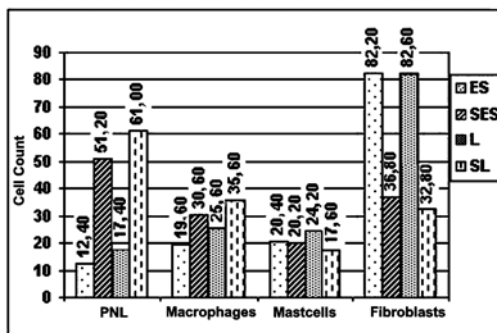


Figure 2.  
Graph of data on 4th day.

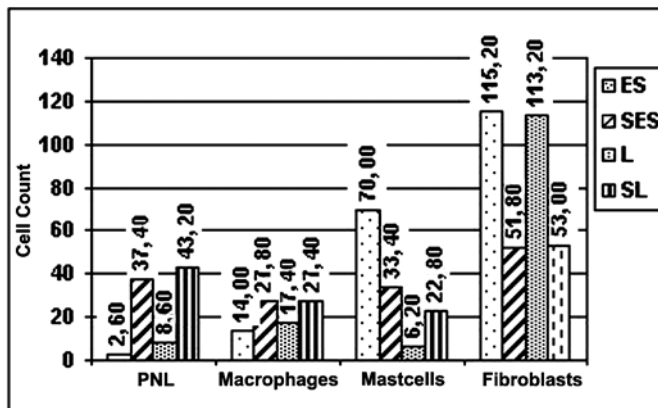
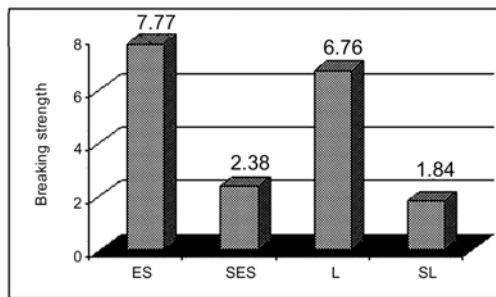


Figure 3.  
Graph of data on 10th day.



**Figure 4.**  
Graph of data on 25th day.

proliferative phase, and this finding correlates with the literature.

Also, in some studies, the fibroblast number was higher in the laser treatment group compared with its control group [9,12]. In our study, we found that the fibroblast number was more increased in the laser treatment group than in the sham laser treatment group on the 4th and 10th days. This finding indicates that laser treatment is beneficial at the earliest stages and for the continuity of the proliferative phase, which is in accordance with the literature.

Tissue hydroxyproline level is accepted as an important parameter in the evaluation of collagen metabolism [36]. In some studies, the hydroxyproline level was found to be higher in the ES group than in the sham ES group [3,8]. We, too, found a significantly increased level of hydroxyproline in the ES group compared to the sham ES group on the 4th and 10th days.

During the maturation or remodeling phase, the last and longest phase of wound healing, the most important development is the remodeling and maturation of collagen. The wound breaking strength is used for the biomechanical evaluation of the wound in this phase. Breaking strength increases significantly after the third week of healing; therefore we measured the wound breaking strength on 25th day. Both ES and laser treatment increased the wound breaking strength significantly compared with their control groups, which is also consistent with the literature [3,8,10,11,13]. No statistically significant difference could be found in the wound breaking strength between the ES and laser treatment groups. Ours is the first reported data on this parameter to appear in the literature.

As a result, we conclude that ES is beneficial during the inflammatory phase with negative polarity, and in the proliferation and maturation phase with positive polarity;

consequently, it increases the wound healing process. In addition, laser treatment is beneficial during all three phases—inflammatory, proliferation, and maturation—by stimulating fibroplasia, which in turn increases wound breaking strength and consequently accelerates the wound healing process.

## CONCLUSION

Both ES and laser treatment have been found effective in the qualified and early scar formation. We conclude that they can be used in decubitus ulcers and chronic wound treatment, in combination with conventional therapies such as daily care and debridement of wounds. ES is more effective than laser treatment in the inflammatory phase.

## REFERENCES

1. Peacock EE, Cohen IK. Wound healing. In: McCarthy JG, May JW, Littler JW, editors. *Plastic surgery*. Philadelphia: WB Saunders; 1990. p. 161–85.
2. Colen SR. Pressure sores. In: Goodgold J, editor. *Rehabilitation medicine*. St. Louis: CV Mosby Co; 1988. p. 167–83.
3. Alvarez OM, Mertz PM, Smerbeck RV, Eaglstein WH. The healing of superficial skin wounds is stimulated by external electrical current. *J Invest Dermatol*. 1983;81: 144–48.
4. Brown M, McDonnell MK, Menton DN. Electrical stimulation effects on cutaneous wound healing in rabbits. *Phys Ther*. 1988;68:955–60.
5. Weiss DS, Eaglstein WH, Falanga V. Exogenous electric current reduces the formation of hypertrophic scars. *J Dermatol Surg Oncol*. 1989;15:1272–75.
6. Mulder GD. Treatment of open skin wounds with electrical stimulation. *Arc Phys Med Rehabil*. 1991;72:375–77.
7. Mustoe TA, Weber DA, Krukowski M. Enhanced healing of cutaneous wounds in rats using beads with positively charged surfaces. *Plast Rec Surg*. 1992;89:891–99.
8. Takan I, Özyazgan I, Tercan M, Karda HY, Balkanl S, Saraymen R, et al. A comparative study of the effect of ultrasound and electrostimulation on wound healing in rats. *Plast Reconstr Surg*. 1997;100:966–72.
9. Bisht D, Gupta SC, Misra V, Mital VP, Sharma P. Effect of low intensity laser radiation on healing of open skin wounds in rats. *Indian J Med Res*. 1994;100:43–46.
10. Abergel P, Lyons RF, Castel JC, Dwyer RM, Uitto J. Bio-stimulation of wound healing by lasers: experimental approaches in animal models and in fibroblast cultures. *J Dermatol Surg Oncol*. 1997;13:127–33.

11. Lyons RF, Abergel P, White R. Biostimulation of wound healing in vivo by a helium-neon laser. *Ann Plast Surg.* 1987;18:47–51.
12. Conlan M, Rapley JW, Cobb CM. Biostimulation of wound healing by low-energy laser irradiation: a review. *J Clin Periodont.* 1996;23:492–96.
13. Braverman B, McCarthy RJ, Ivankovich DE, Forde DE, Overfield M, Bapna MS. Effect of helium-neon and infrared laser irradiation on wound healing in rabbits. *Lasers Surg Med.* 1989;9:50–58.
14. Ghamsari SM, Taguchi K, Abe N, Acorda JA, Sato M, Yamada H. Evaluation of low level laser therapy on primary healing of experimentally induced full thickness teat wounds in dairy cattle. *Vet Surg.* 1997;26:114–20.
15. Young SR, Dyson M. Effect of therapeutic ultrasound on the healing of full thickness excised skin lesions. *Ultrasonic.* 1990;28:175–80.
16. Reddy GK, Envemeka CS. A simplified method for the analysis of hydroxyproline in biological tissues. *Clin Biochem.* 1996;29:225–29.
17. Tatarchuk PA. The application of perilesional bioelectrical stimulation in mechanical treatment of wounds. *Klin Khir.* 2000;1:33–35.
18. Peters EJ, Lavery LA, Armstrong DG, Fleischli JG. Electric stimulation as an adjunct to heal diabetic foot ulcers: a randomized clinical trial. *Arch Phys Med Rehabil.* 2001;82:721–25.
19. Houghton PE, Kincaid CB, Lovell M, Campbell KE, Keast DH, Woodbury MG, et al. Effect of electrical stimulation on chronic leg ulcer size and appearance. *Phys Ther.* 2003;83:17–28.
20. Stadler I, Lanzafame RJ, Evans R, Narayan V, Dailey B, Buehner N, Naim JO. 830-nm irradiation increases the wound tensile strength in a diabetic murine model. *Lasers Surg Med.* 2001;28:220–26.
21. Simunovic Z, Ivankovich AD, Depolo A. Wound healing of animal and human body sport and traffic accident injuries using low-level laser therapy treatment: a randomized clinical study of seventy-four patients with control group. *J Clin Laser Med Surg.* 2000;18:67–73.
22. Barker AT, Jagge LF, Venable JW. The glabrous epidermis of cavies contains a powerful battery. *Am J Physiol.* 1982;242:R358–65.
23. Kloth LC, Feedar JA. Electrical stimulation in tissue repairs. In: Kloth LC, McCulloch JM, Feedar JA, editors. *Wound healing: alternatives in management.* Philadelphia: FA Davis Co; 1990. p. 222–56.
24. Assimacopoulos D. Wound healing promotion by the use of negative electric current. *Am Surg.* 1968;34:423–26.
25. Dumphy JE. Modern biochemical concepts on the healing wound. In: Dumphy JE, editor. *Wound healing.* New York: Medcom; 1974. p. 22–31.
26. Weber DC, Brown AW. Physical agent modalities. In: Braddom RL, editor. *Physical medicine and rehabilitation.* Philadelphia:WB Saunders Co; 1996. p. 449–64.
27. Low J, Reed A. Laser therapy. In: Low J, Reed A, editors. *Electrotherapy explained: principle and practice.* London: Butterworth Heinemann Ltd; 1993. p. 299–313.
28. Wolcott LE, Wheeler PC, Hardwicke HM, Rowley BA. Accelerated healing of skin ulcers by electrotherapy. *South Med J.* 1969;62:795–801.
29. Gault WR, Gatens PF. Use of low intensity direct current in management of ischemic skin ulcers. *Phys Ther.* 1976;70:37–40.
30. Cummings J. Role of light in wound healing. In: Kloth LC, McCulloch JM, Feedar JA, editors. *Wound healing: alternatives in management.* Philadelphia: FA Davis Co; 1990. p. 287–94.
31. Young S, Bolton P, Dyson M, Harvey W, Diamantopoulos C. Macrophage responsiveness to light therapy. *Lasers Surg Med.* 1989;8:495–505.
32. Ericson CA, Nucitelli R. Embryonic fibroblast motility and orientation can be influenced by physiological electric fields. *J Cell Biol.* 1984;98:296–307.
33. Bourguignon GJ, Bourguignon LY. Electrical stimulation of protein and DNA synthesis in human fibroblast. *J Fed Am Soc Exp Biol.* 1987;1:398–402.
34. Robinson KR. The responses of cells to electrical fields: a review. *J Cell Biol.* 1985;101:2023–27.
35. Dumphy JE, Udupa KN. Chemical and histochemical sequences in the normal healing of wounds. *N Eng J Med.* 1955;253:847–90.
36. Kloth LC, Miller KH. The inflammatory response to wound healing. In: Kloth LC, McCulloch JM, Feedar JA, editors. *Wound healing: alternatives in management.* Philadelphia: FA Davis Co; 1990. p 3–13.

Submitted January 6, 2003. Accepted March 31, 2003.